
ThinPrep® Pap Test Diagnostic Challenges and Differential Diagnoses

ThinPrep[®] Characteristics

- Wet Fixation
 - enhanced cytoplasmic and nuclear detail
 - variability in nuclear staining
- Cell Size
 - proportionately smaller
 - single cells more prominent
 - cells may round up in solution e.g.. adenocarcinoma
- Smear Pattern
 - Cellular material not pulled out in mucous
 - Mechanical artifacts eliminated
- Specimen Background
 - Cellular debris may appear clumped

Differential Diagnoses

- Endocervical Adenocarcinoma vs. Poorly Differentiated Squamous Cell Carcinoma (SCC)
- Endocervical Adenocarcinoma vs. Endometrial Adenocarcinoma
- Endometrial Adenocarcinoma vs. Small Cell Squamous Carcinoma
- Adenocarcinoma-in-situ vs. Tubal Metaplasia
- HSIL vs. Single Endometrial Cells
- HSIL vs. Immature Squamous Metaplasia
- Poorly Differentiated Squamous Cell Carcinoma vs. Repair

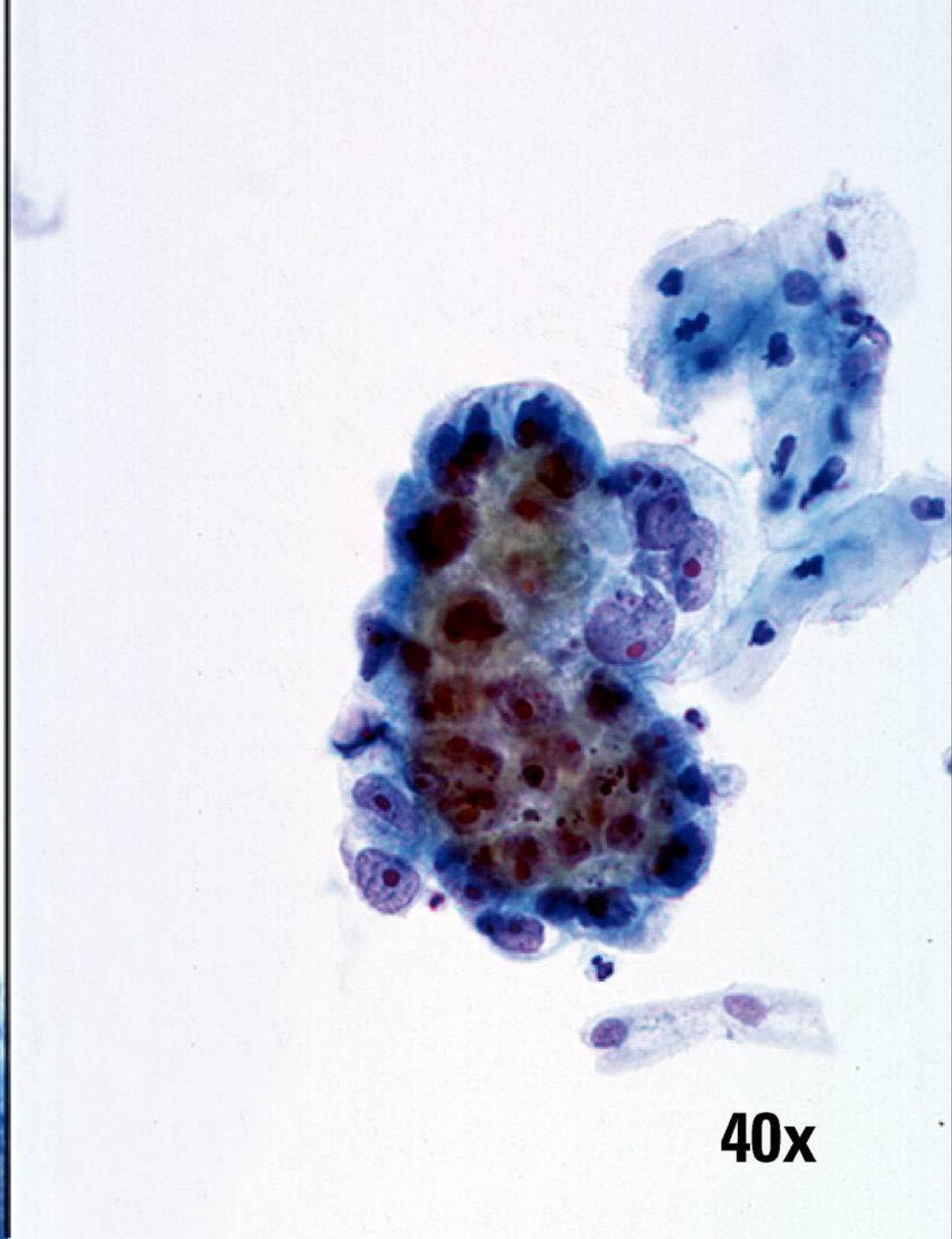
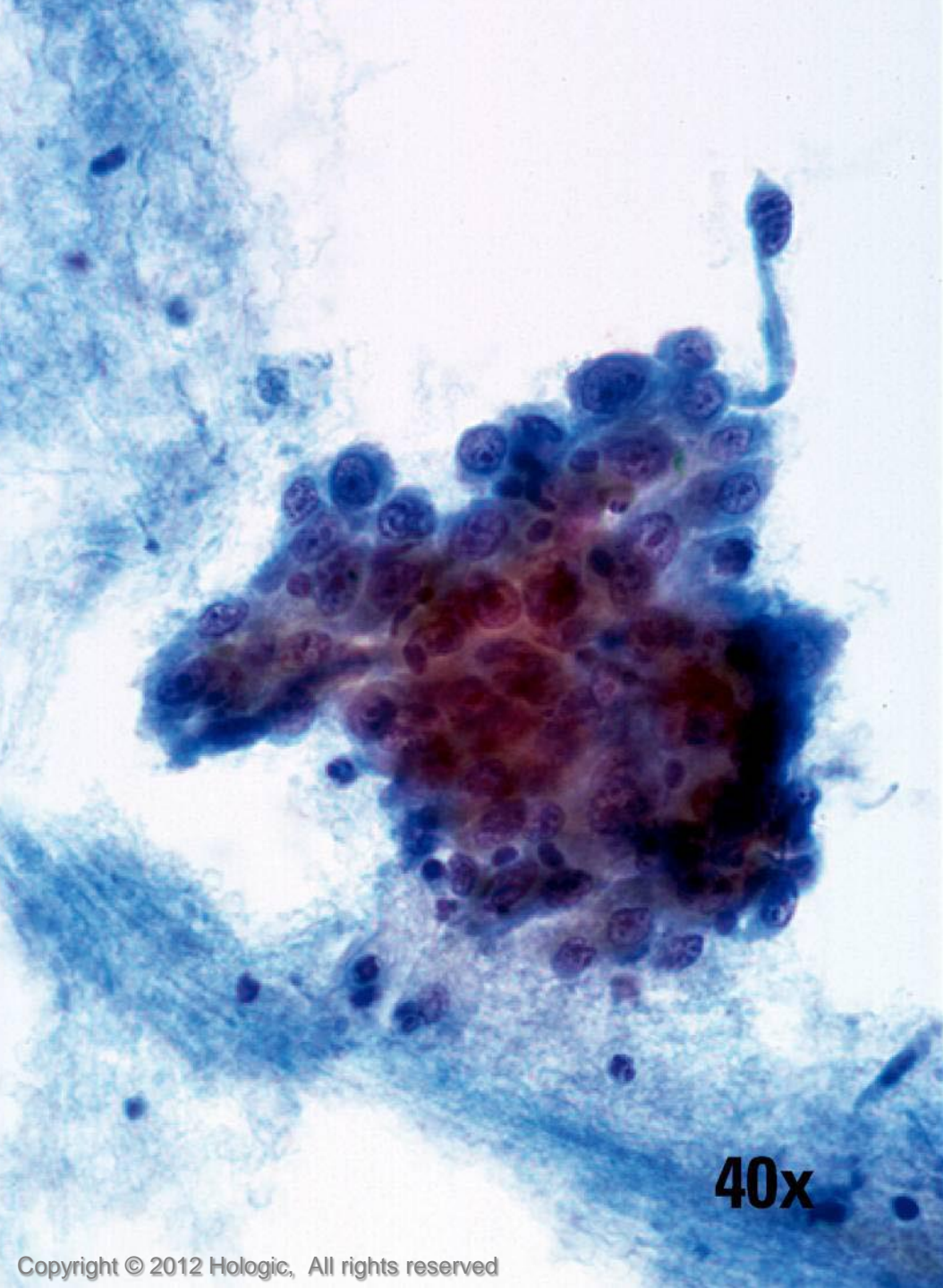
Poorly Differentiated Squamous Cell Carcinoma vs. Endocervical Adenocarcinoma

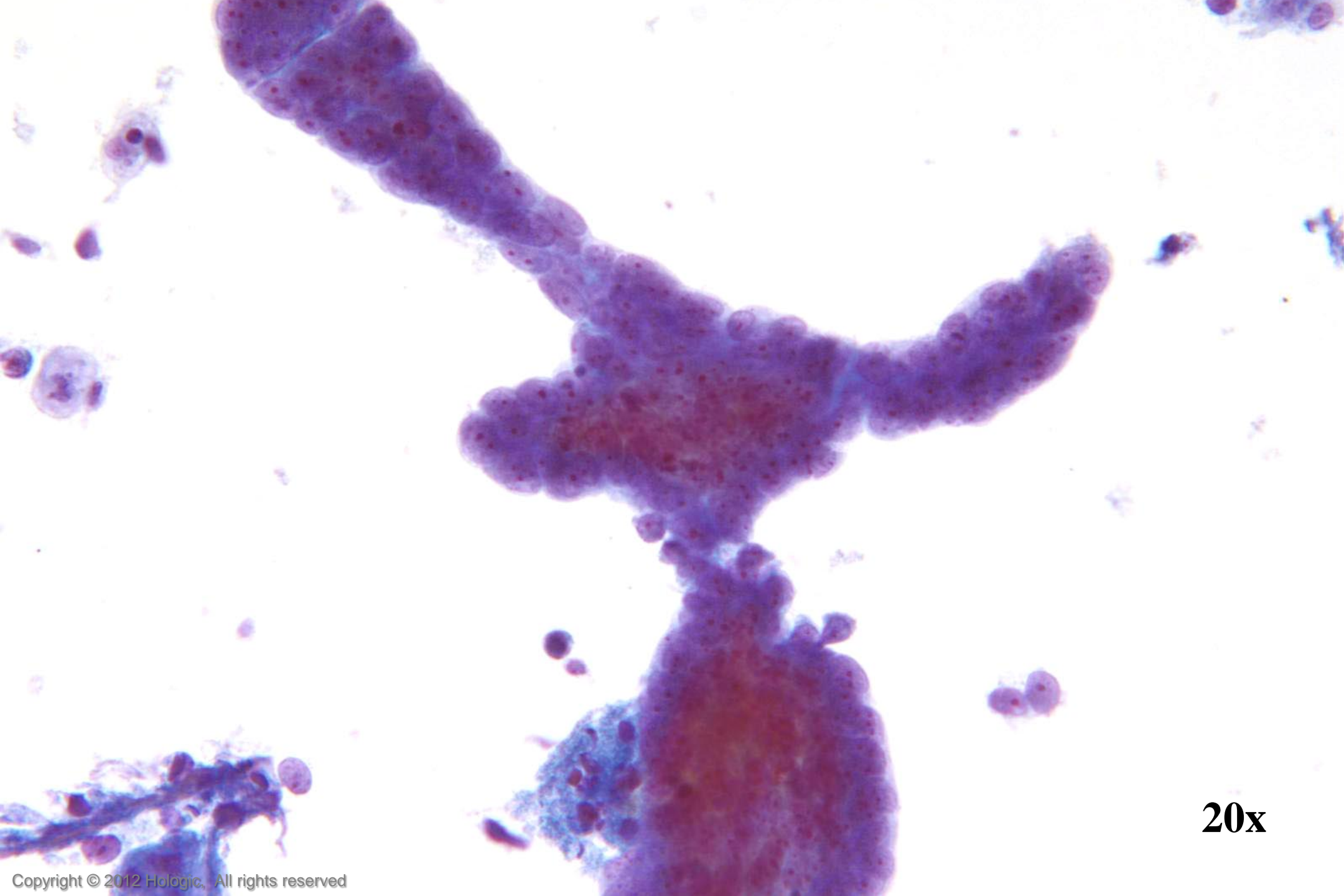Poorly Differentiated SCC

- 2D sheets and single cells
- Ragged group edges
- Dense, homogenous cytoplasm
- Pleomorphism, irregular nuclear shapes and sizes
- Irregular chromatin clumping
- Nucleoli variable in shape, size, number and position

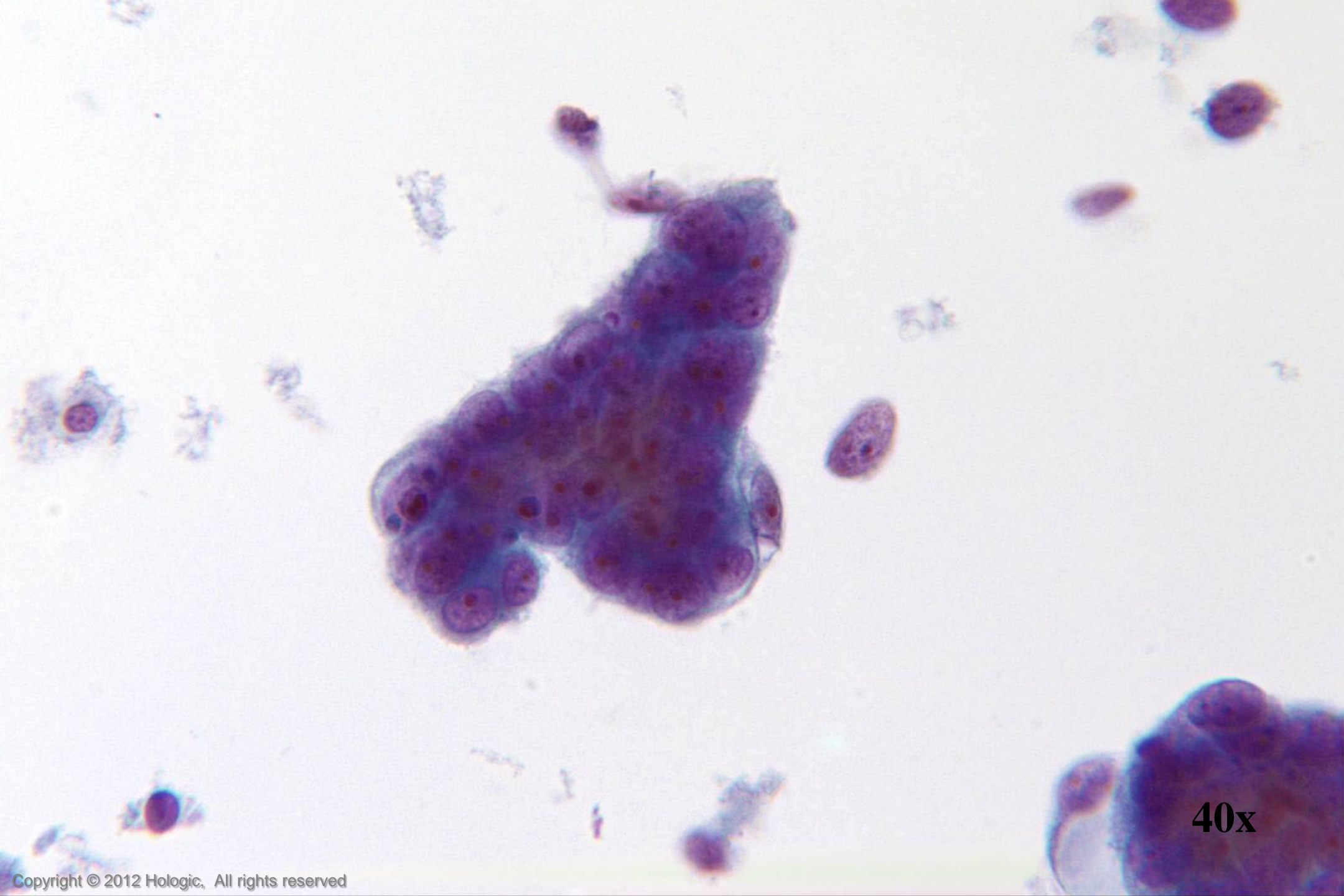
Endocervical Adenocarcinoma

- 3D cell groupings
- Common group borders
- Delicate, foamy cytoplasm
- Enlarged nuclei, commonly round/oval
- Parachromatin clearing
- Round, central, single or multiple macronucleoli

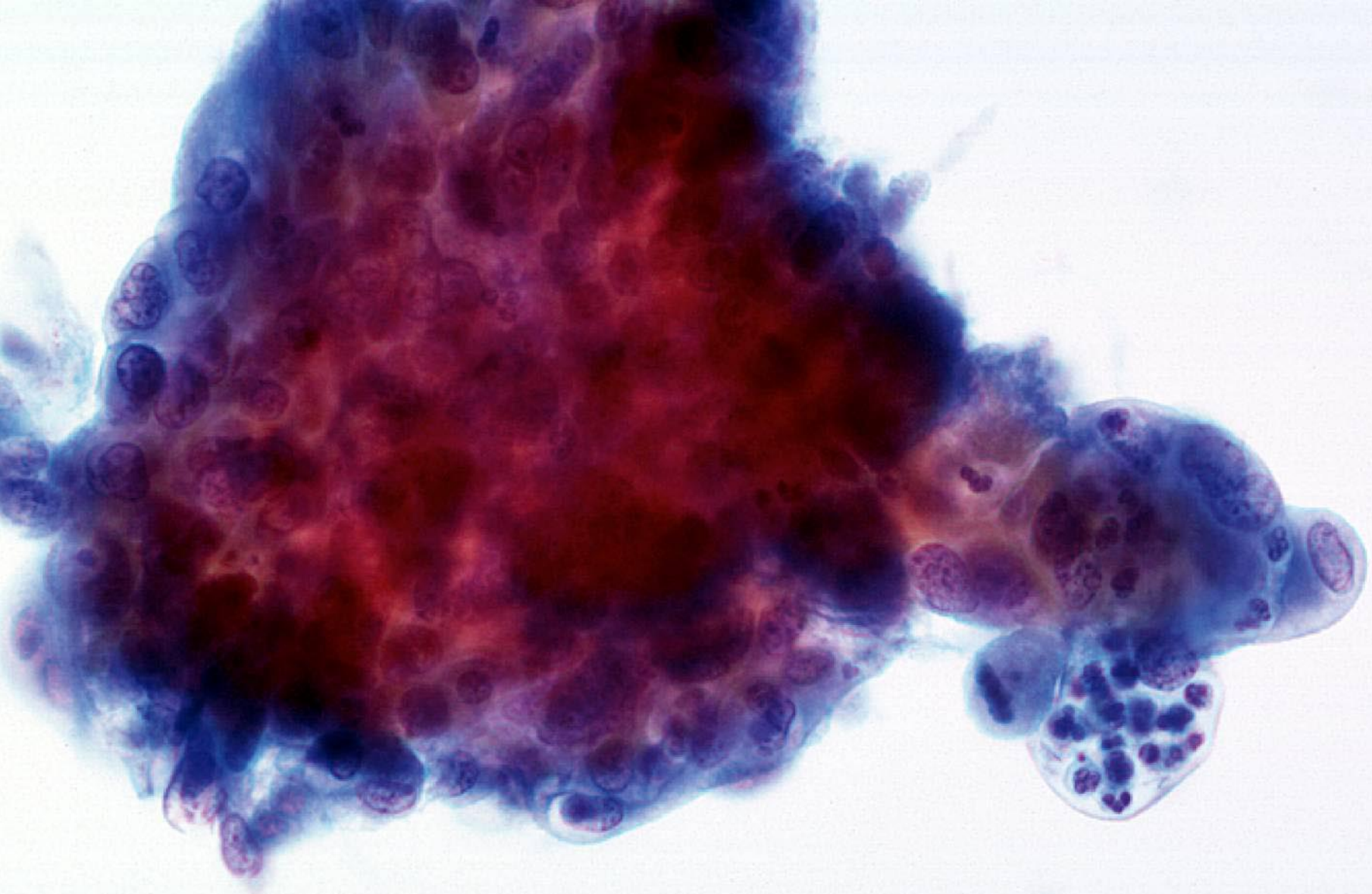




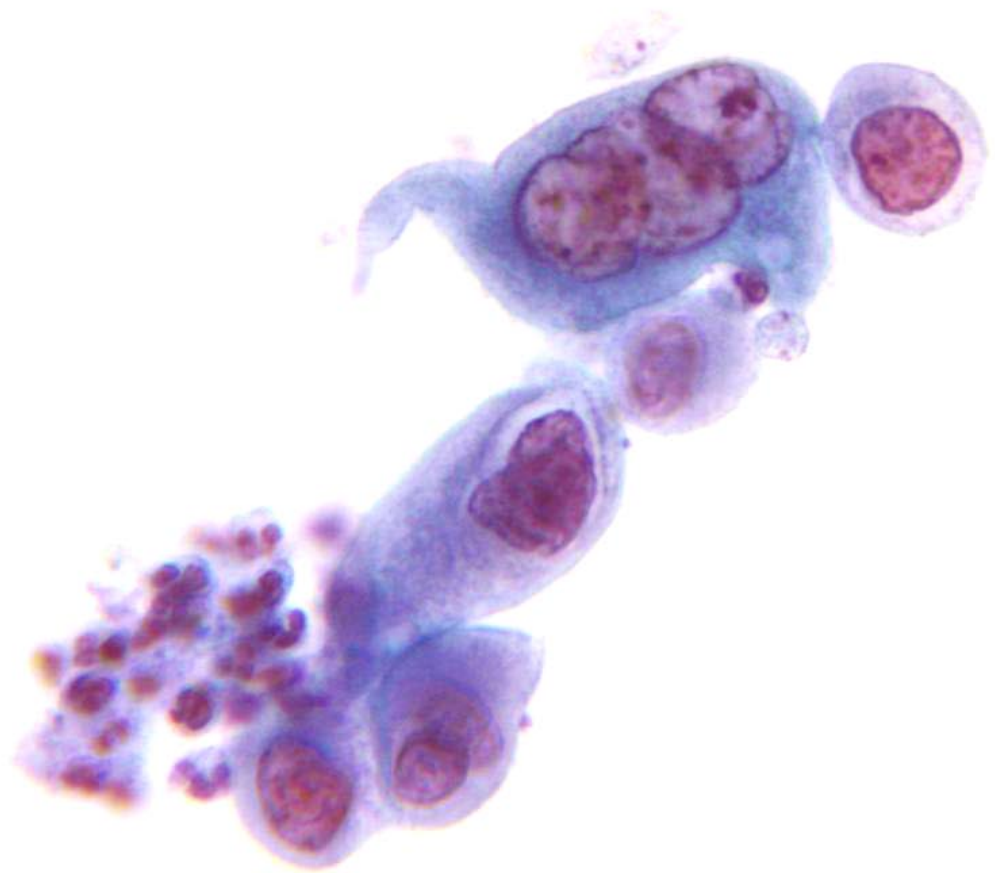20x



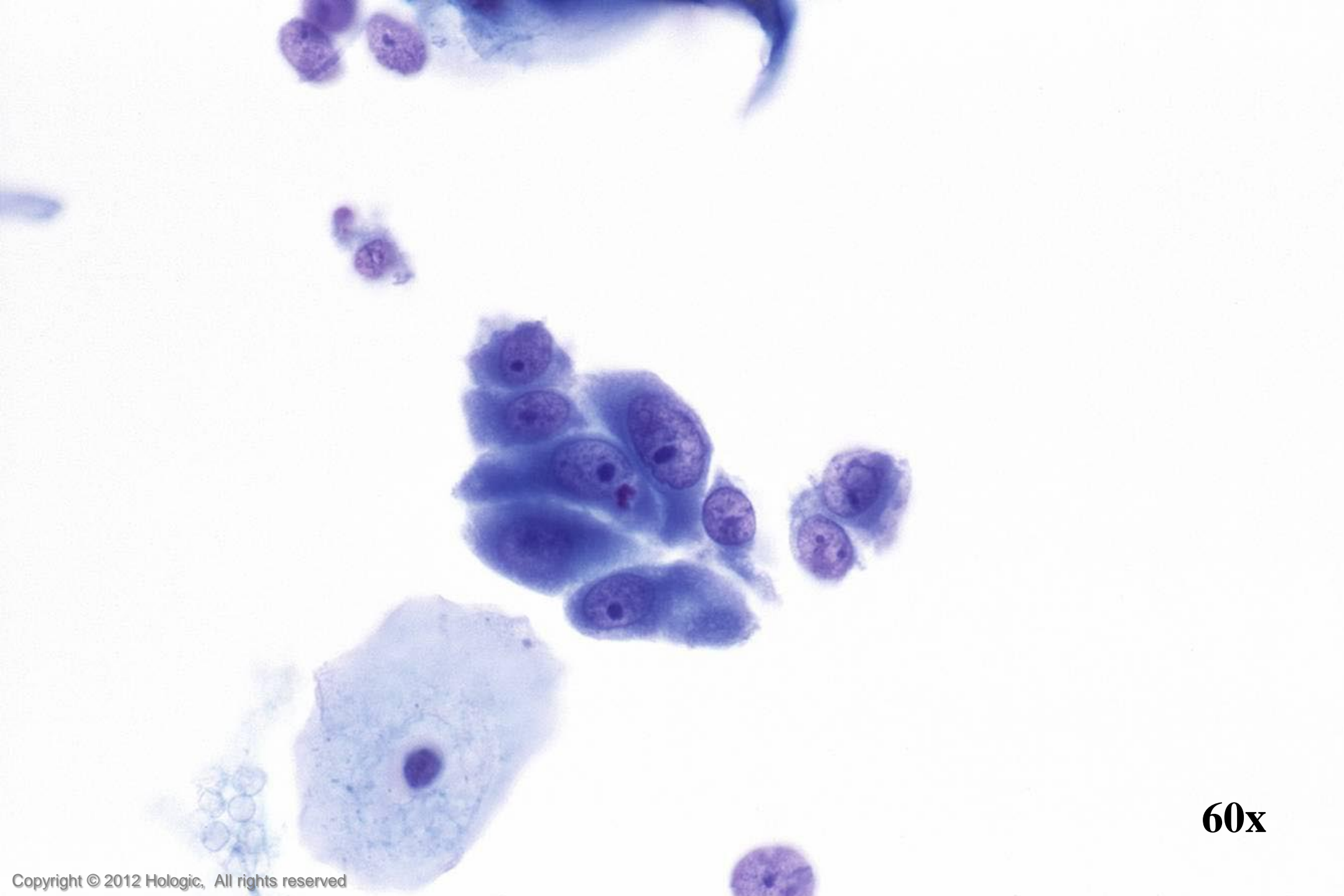
40x



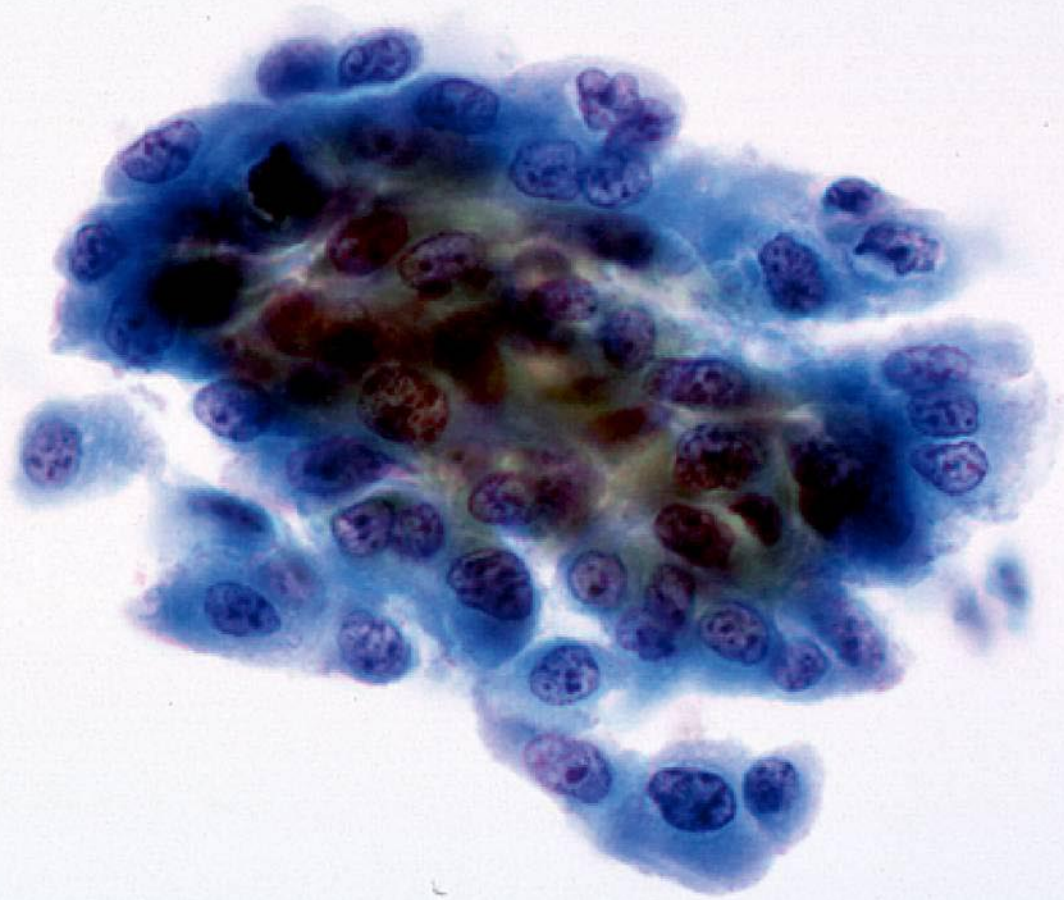
40x



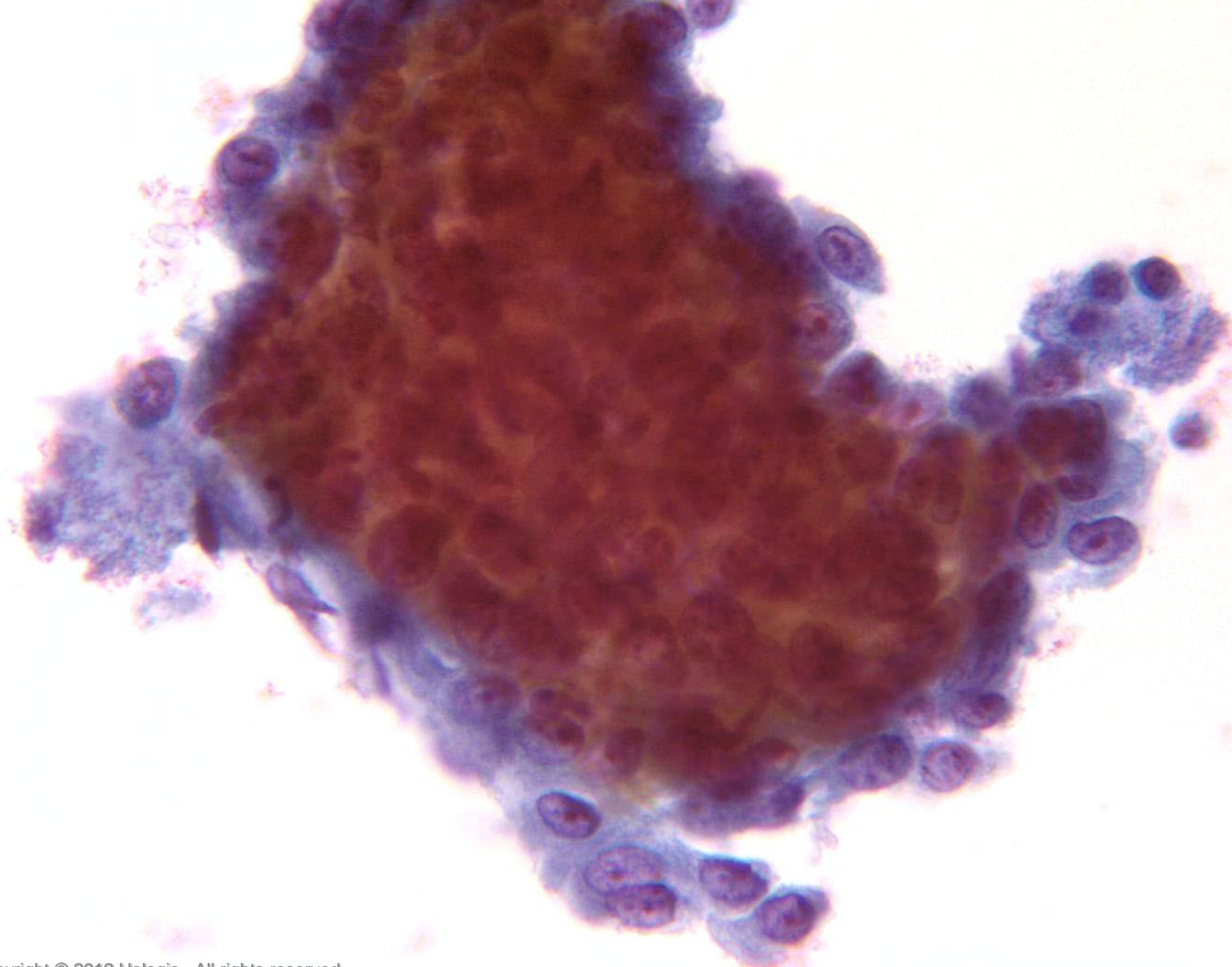
60x



60x



40x



60x

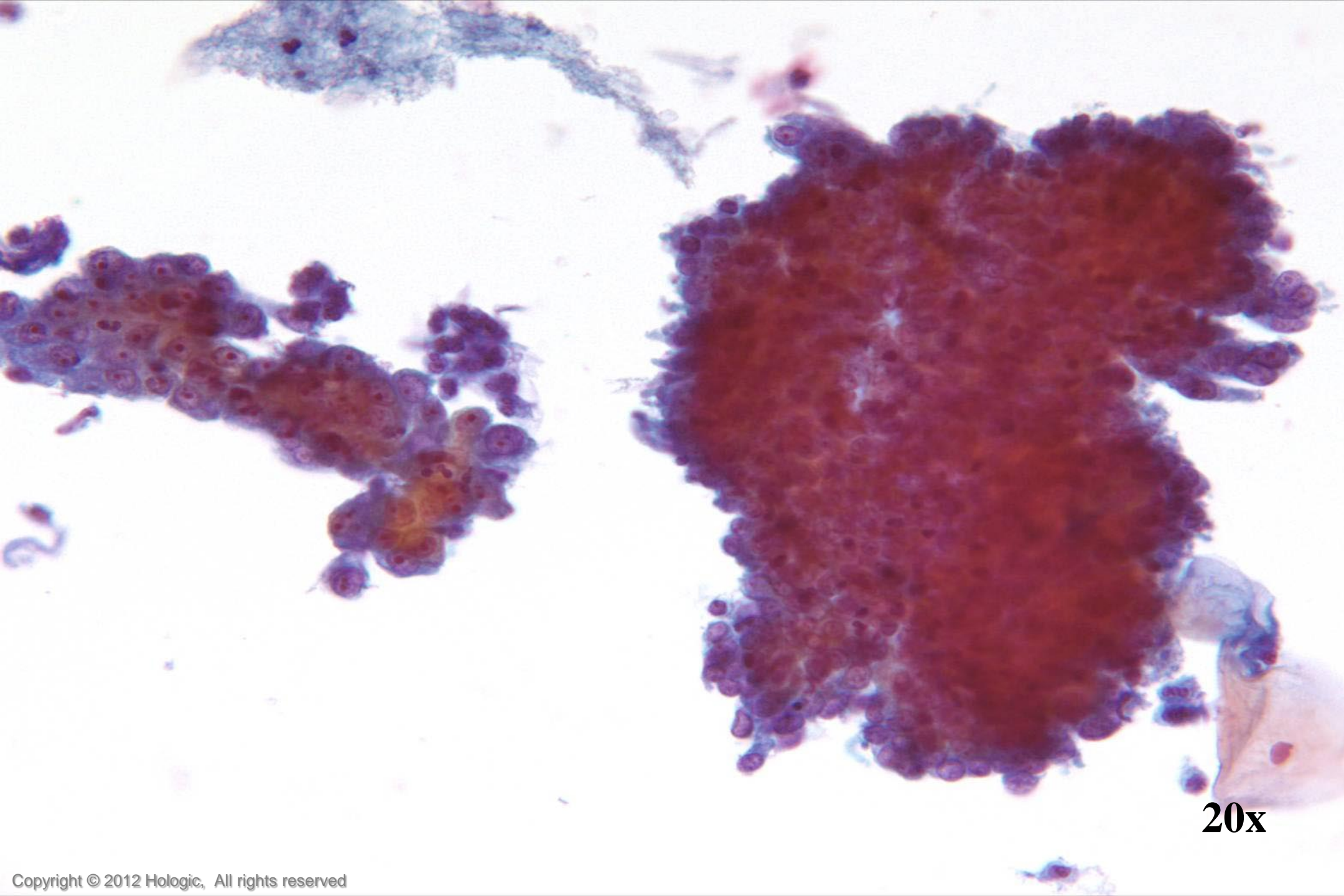
Endocervical Adenocarcinoma vs. Endometrial Adenocarcinoma

Endocervical Adenocarcinoma

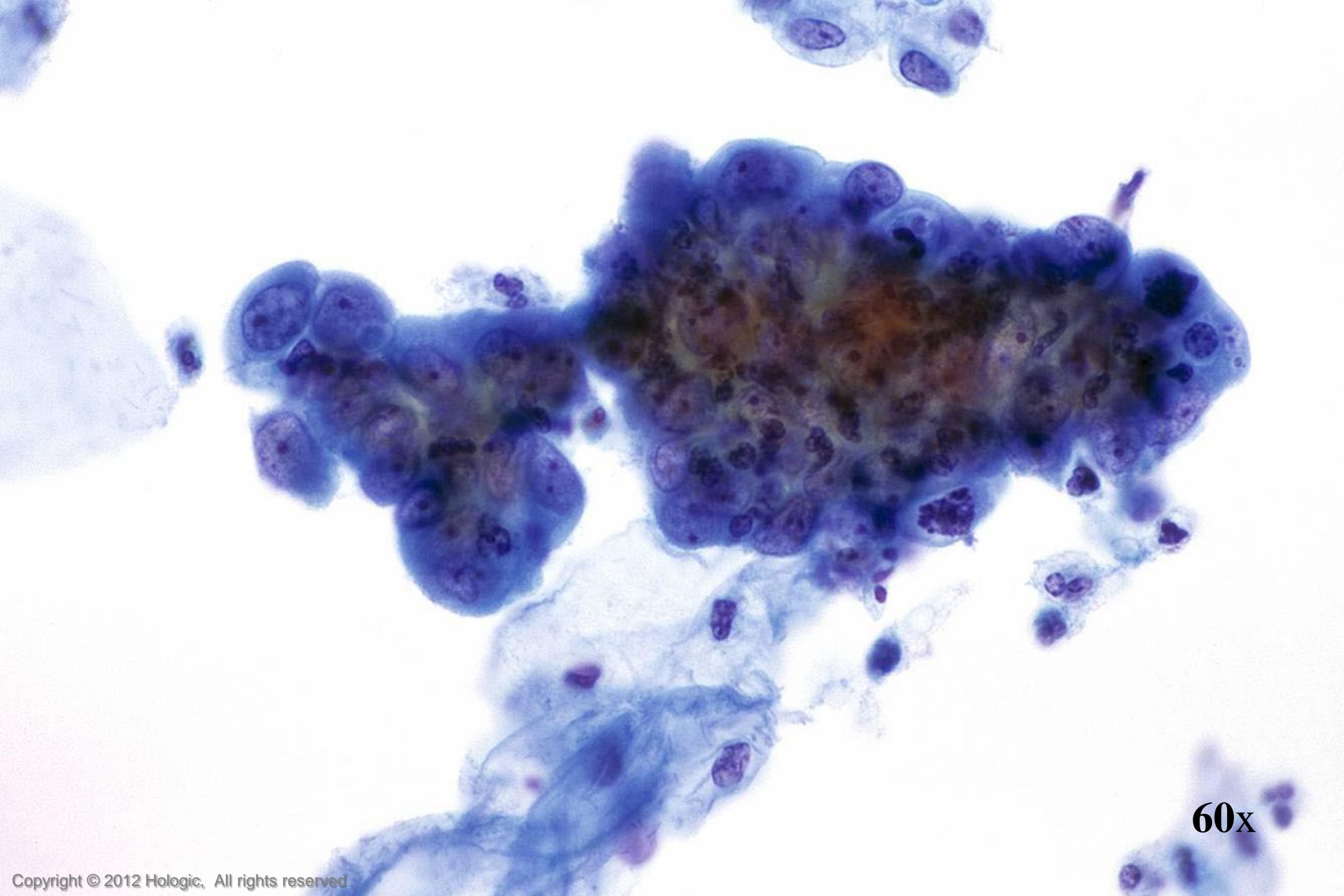
- Abundant abnormal material
 - directly scraped
- Well preserved material
- Cells and cell groupings generally larger in size
- Abundant, foamy cytoplasm, occasionally columnar shaped
- AIS precursor with endocervical architecture may be seen

Endometrial Adenocarcinoma

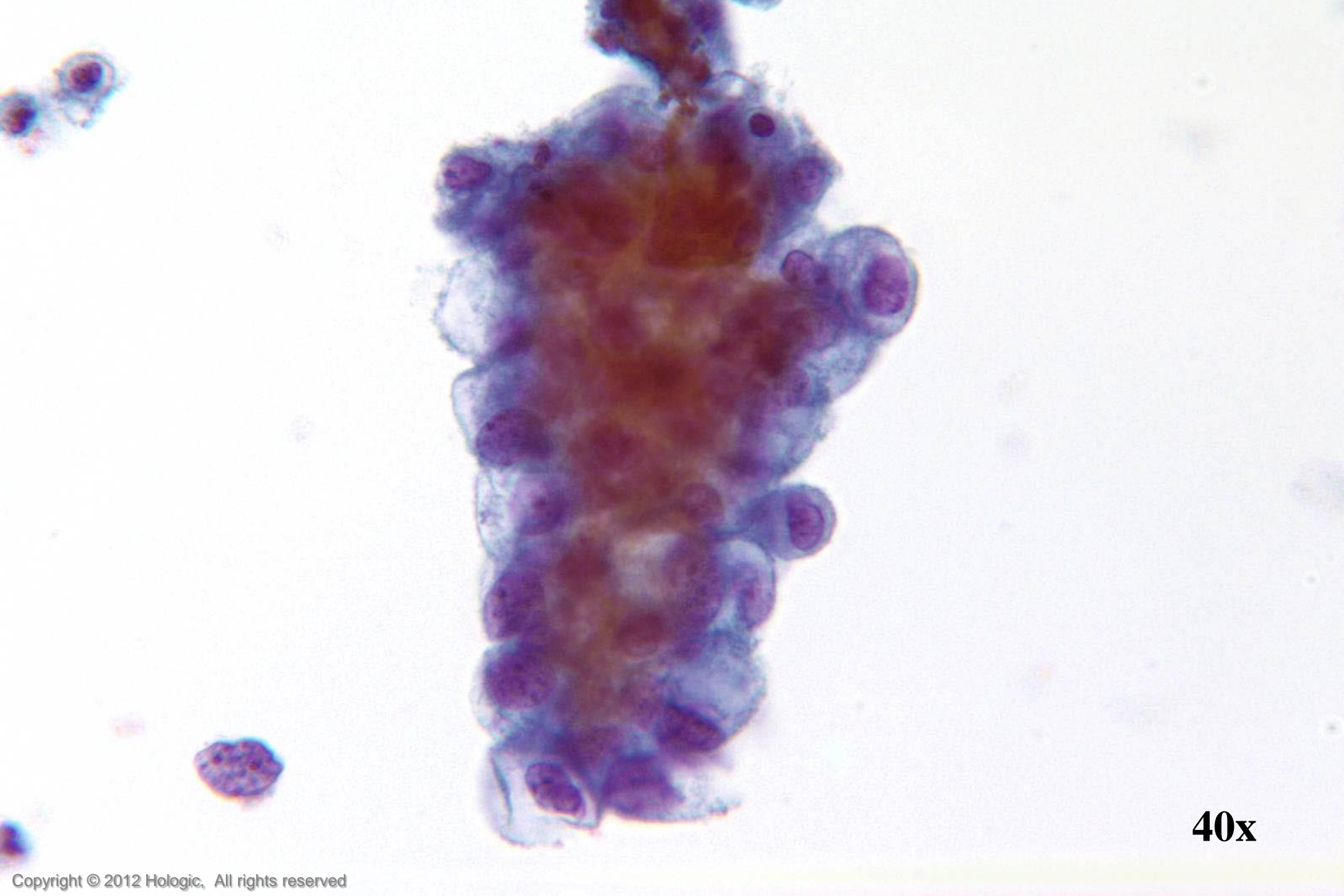
- Isolated abnormal groups
 - cell shedding
- Variable preservation of cells
- Cells and cell groupings generally smaller in size
- Scant, cyanophilic cytoplasm with occasional conspicuous vacuoles
- Mature hormonal pattern, watery transudate may be seen



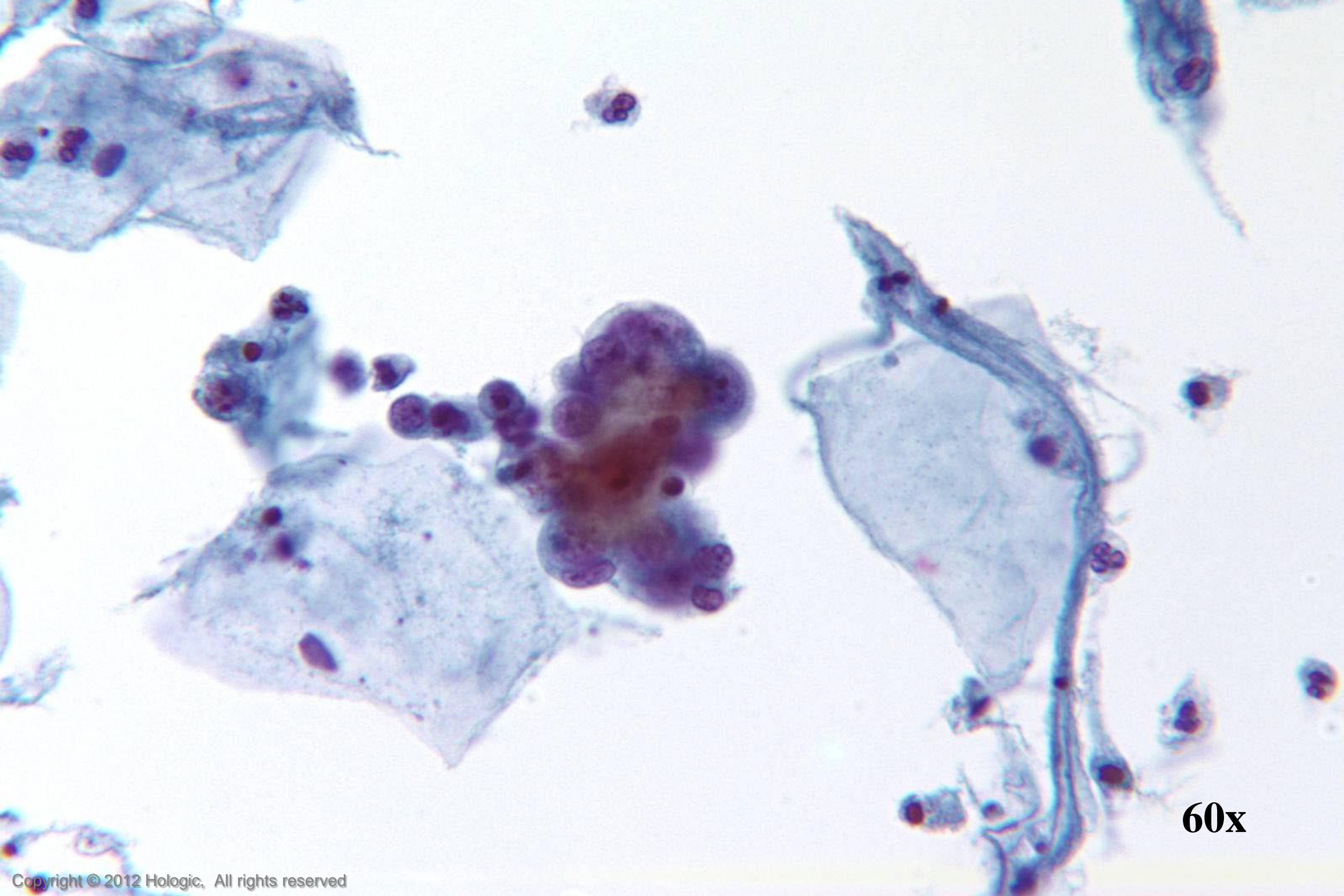
20x



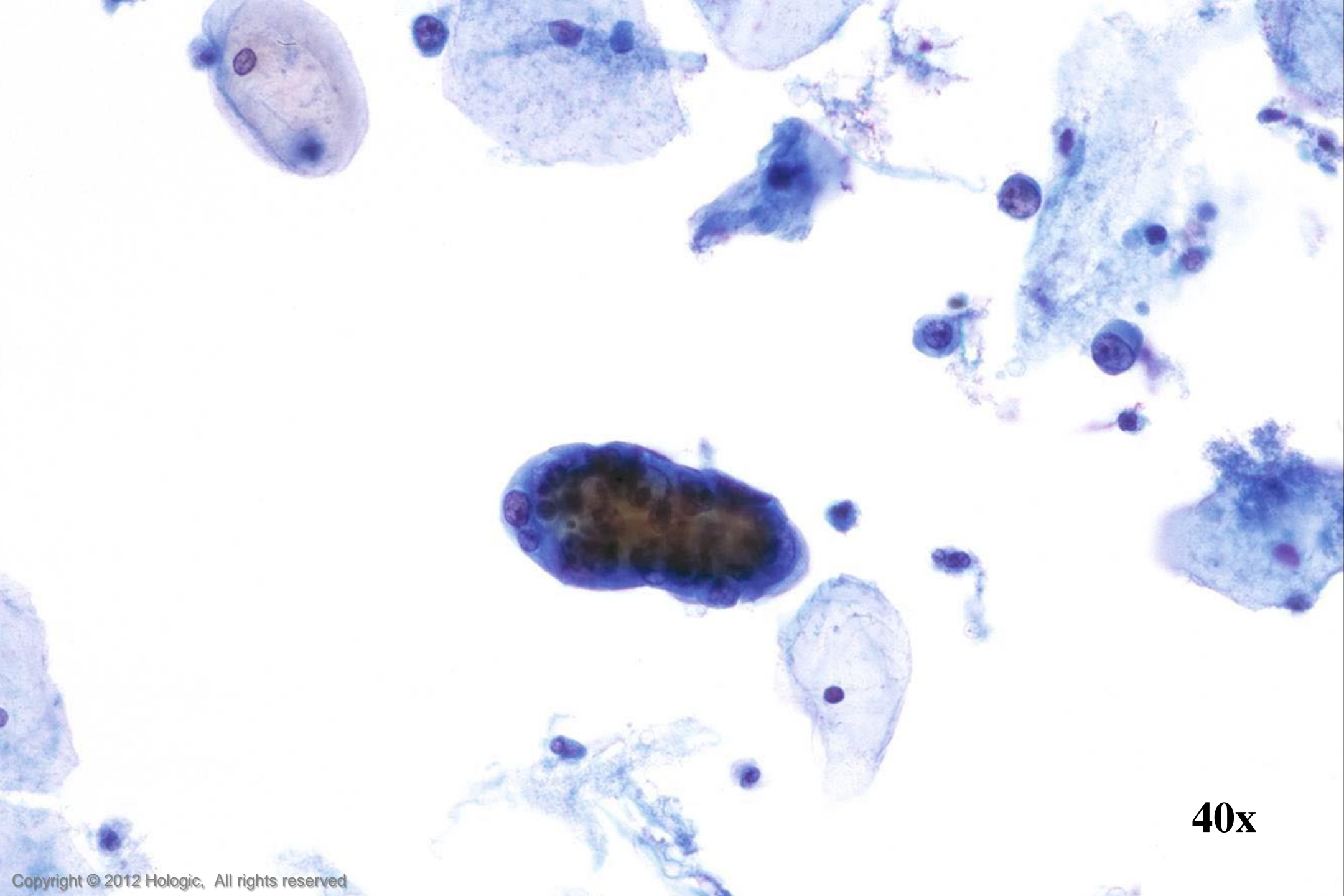
60x



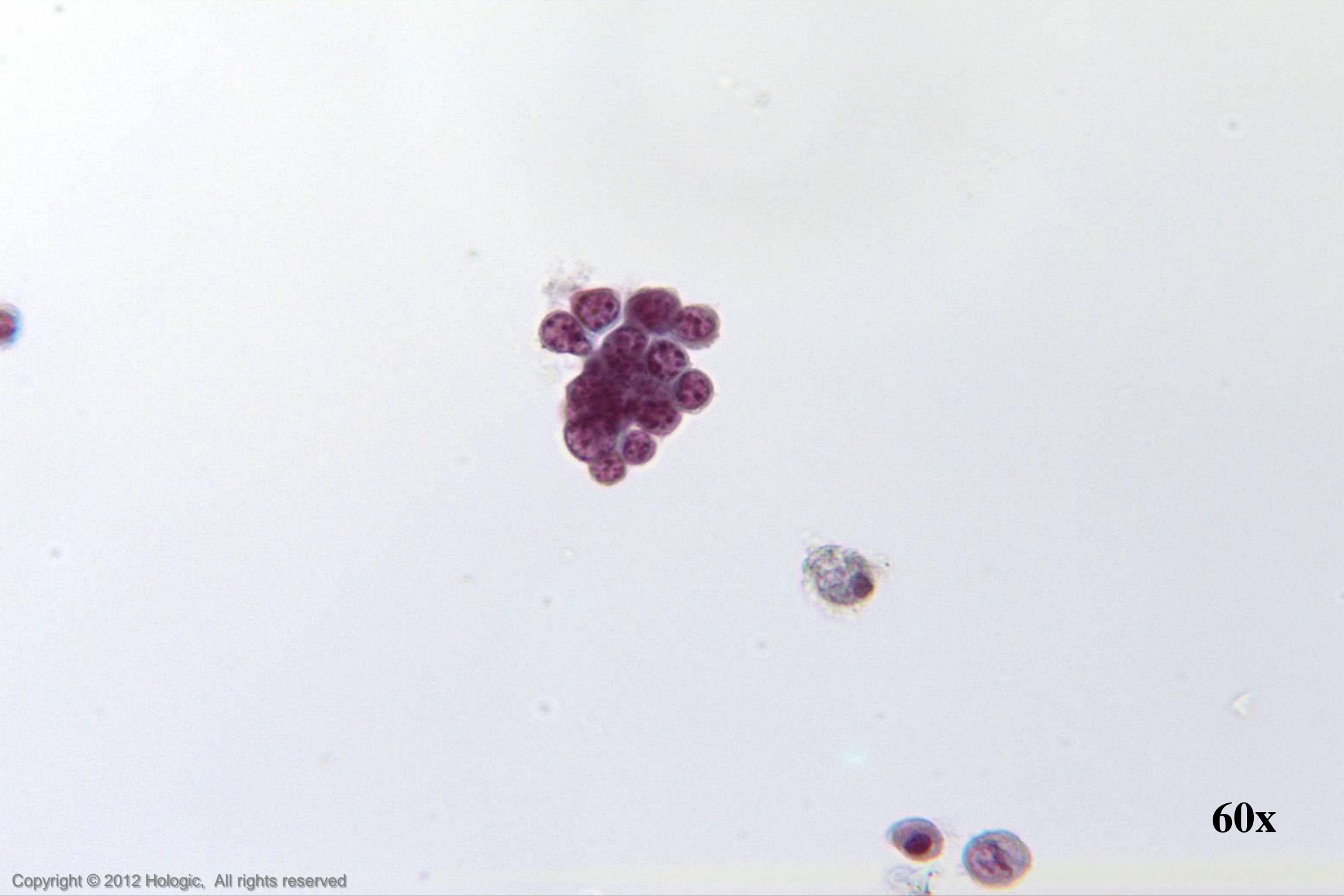
40x



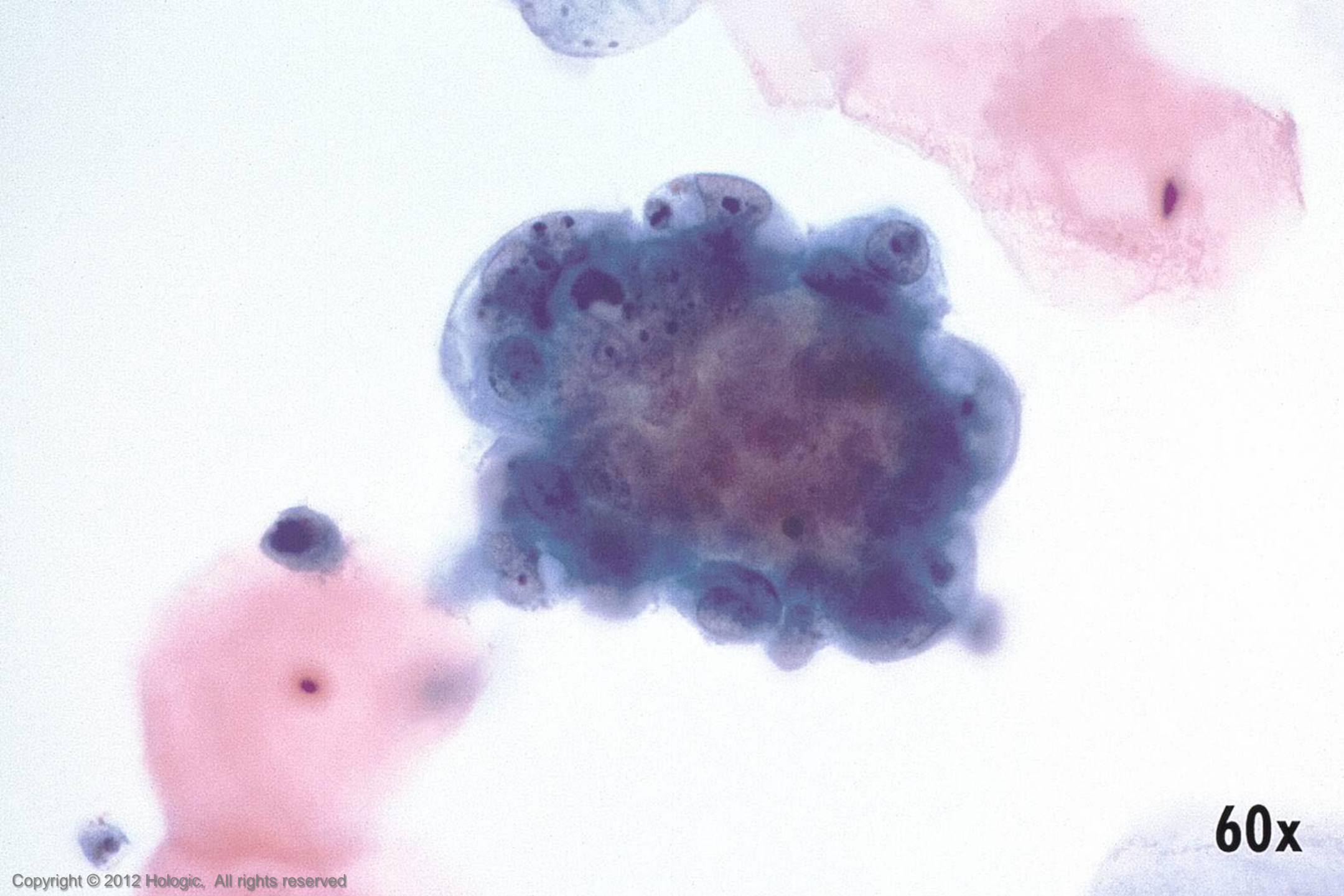
60x



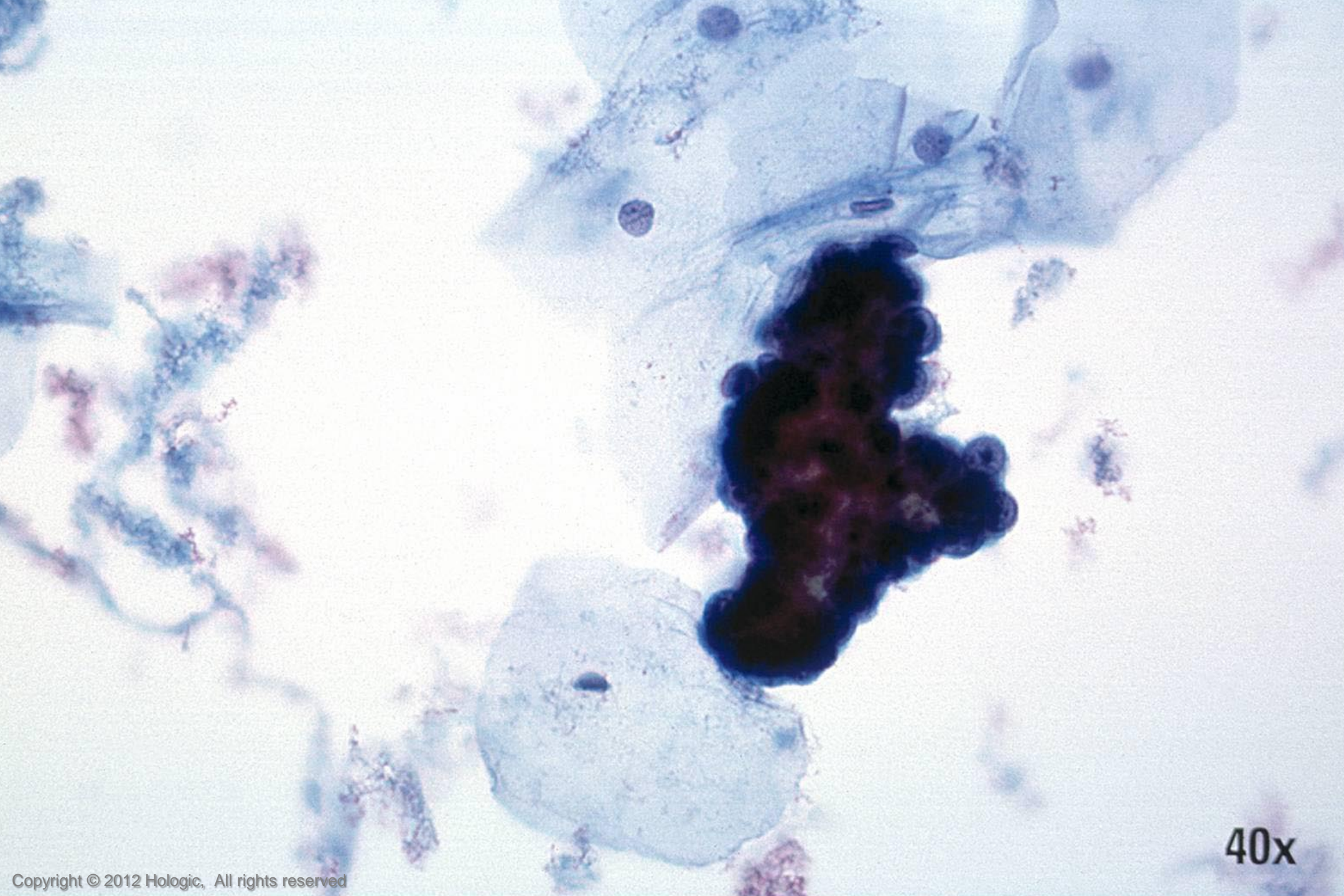
40x



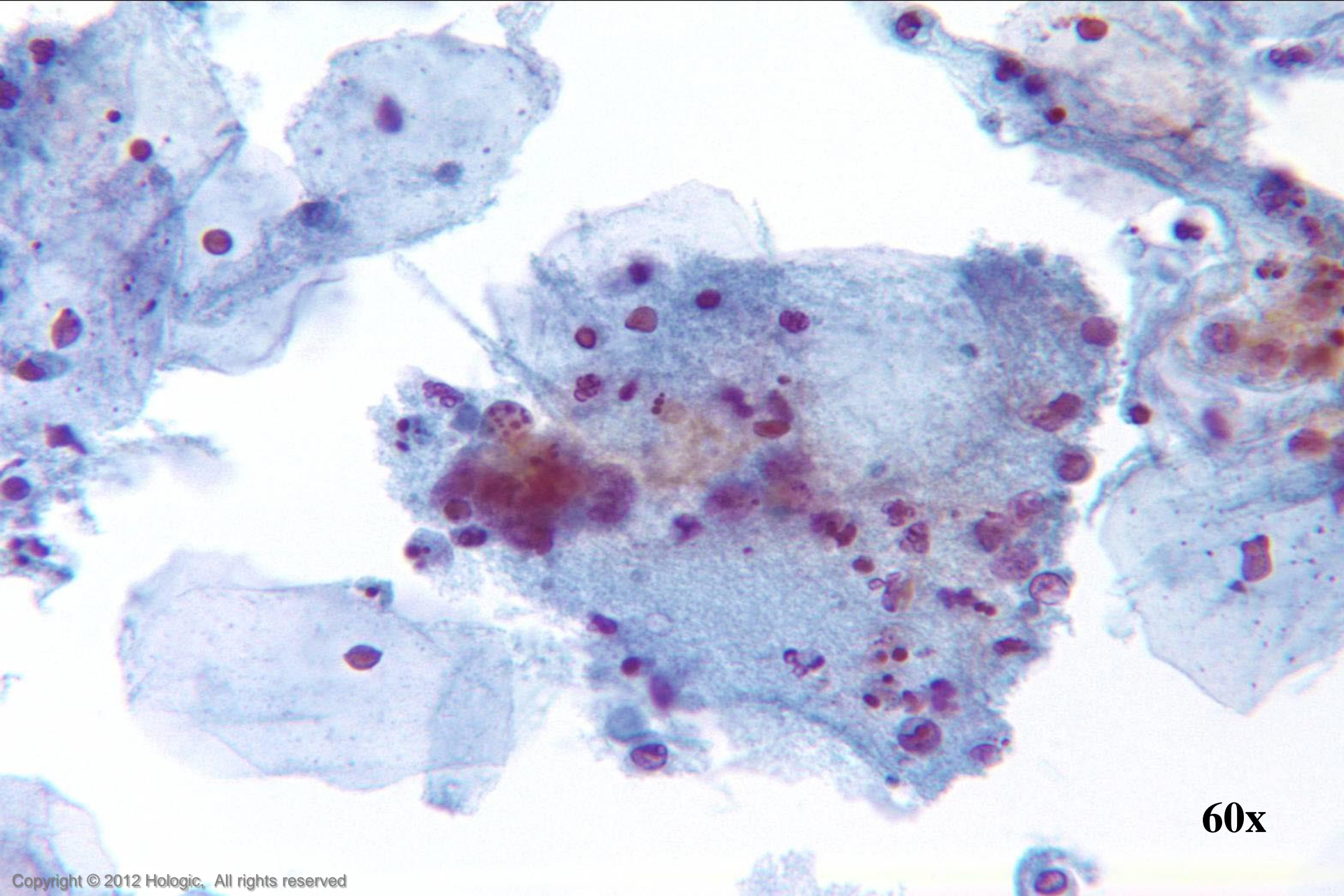
60x



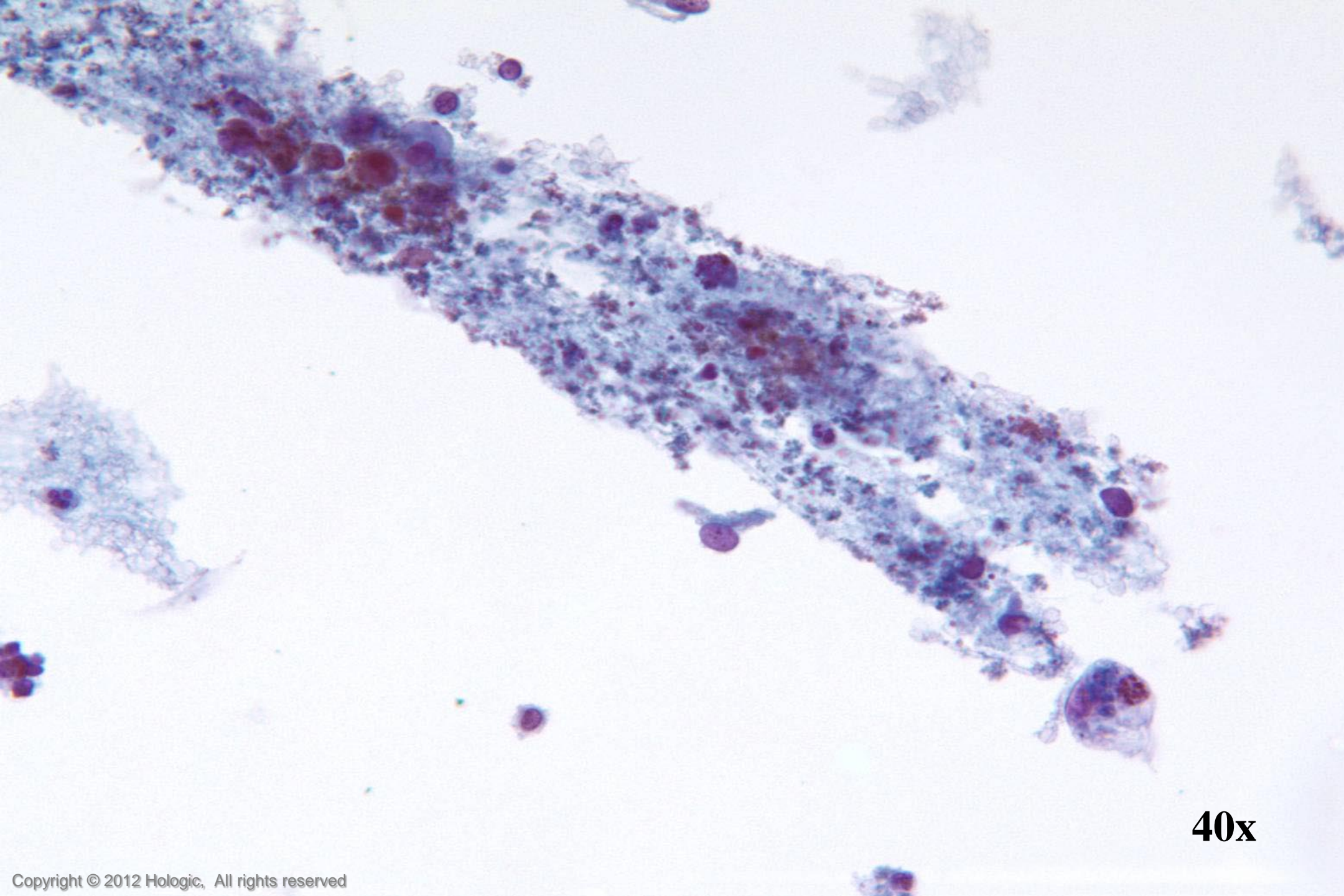
60x



40x



60x



40x

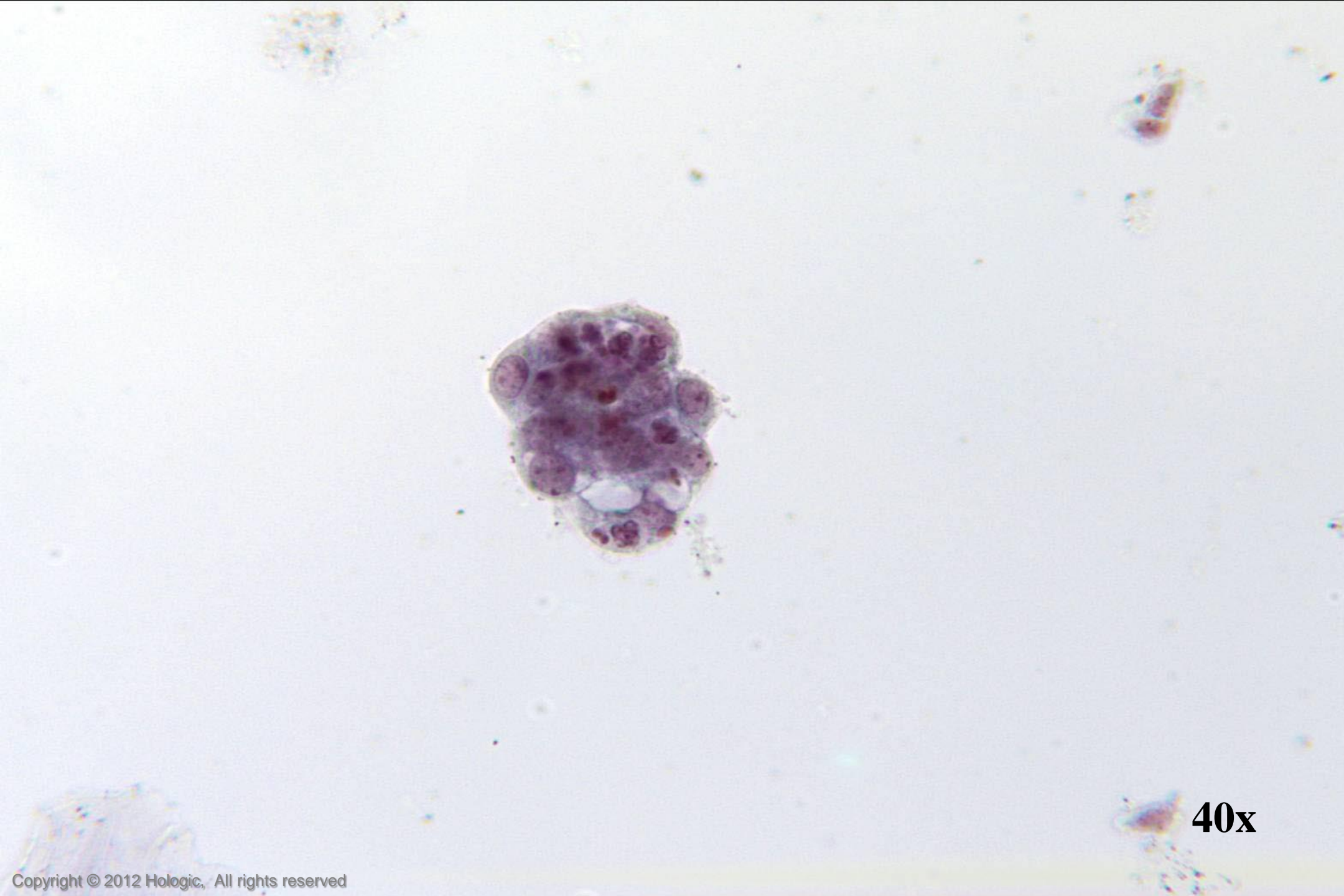Endometrial Adenocarcinoma vs. Small Cell SCC

Endometrial Adenocarcinoma

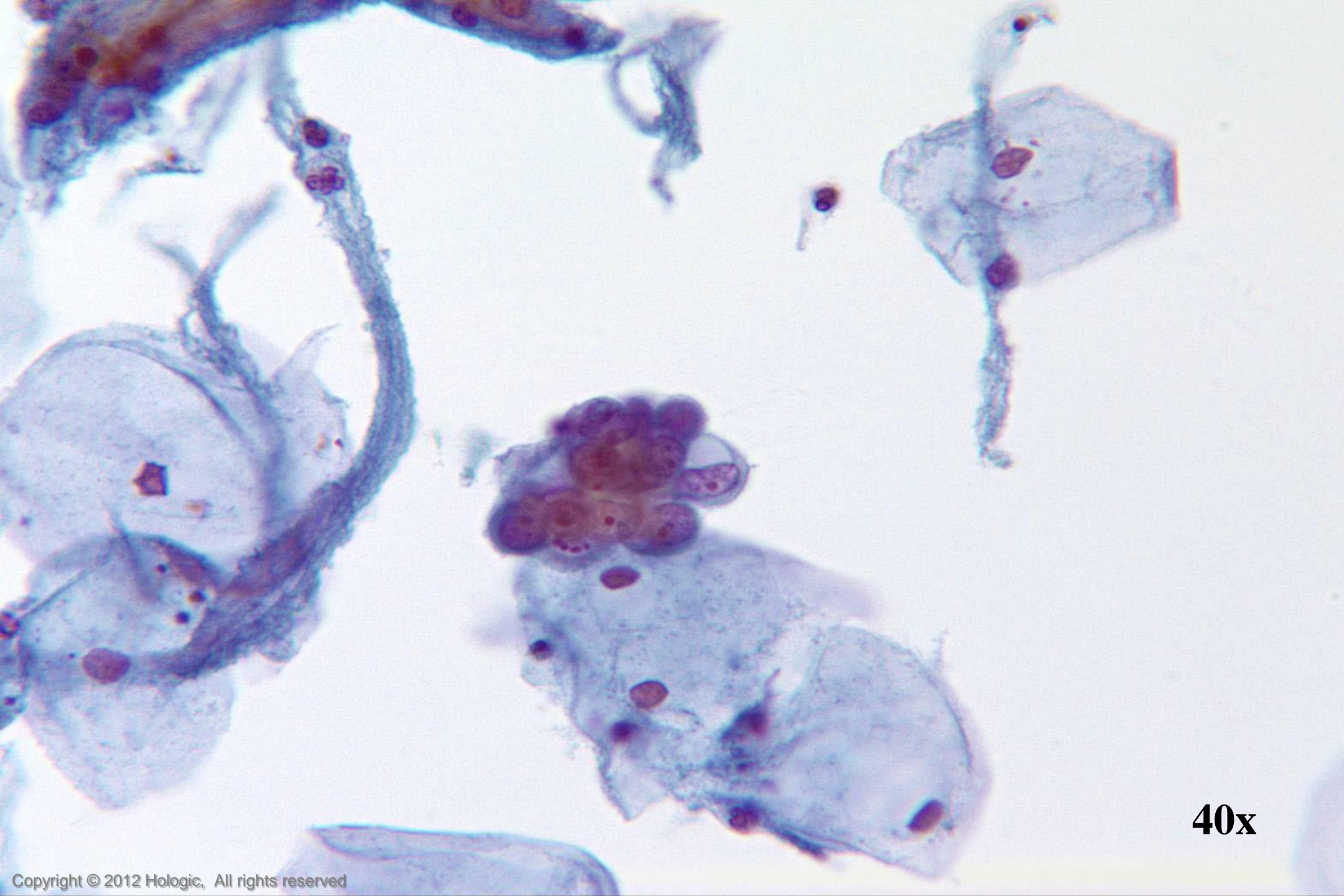- Isolated abnormal groups
 - cell shedding
- Occasional clusters, fewer single cells
- Scant, vacuolated cytoplasm
- Eccentrically located nuclei
- Parachromatin clearing
- Round, central, single or multiple macronucleoli

Small Cell SCC

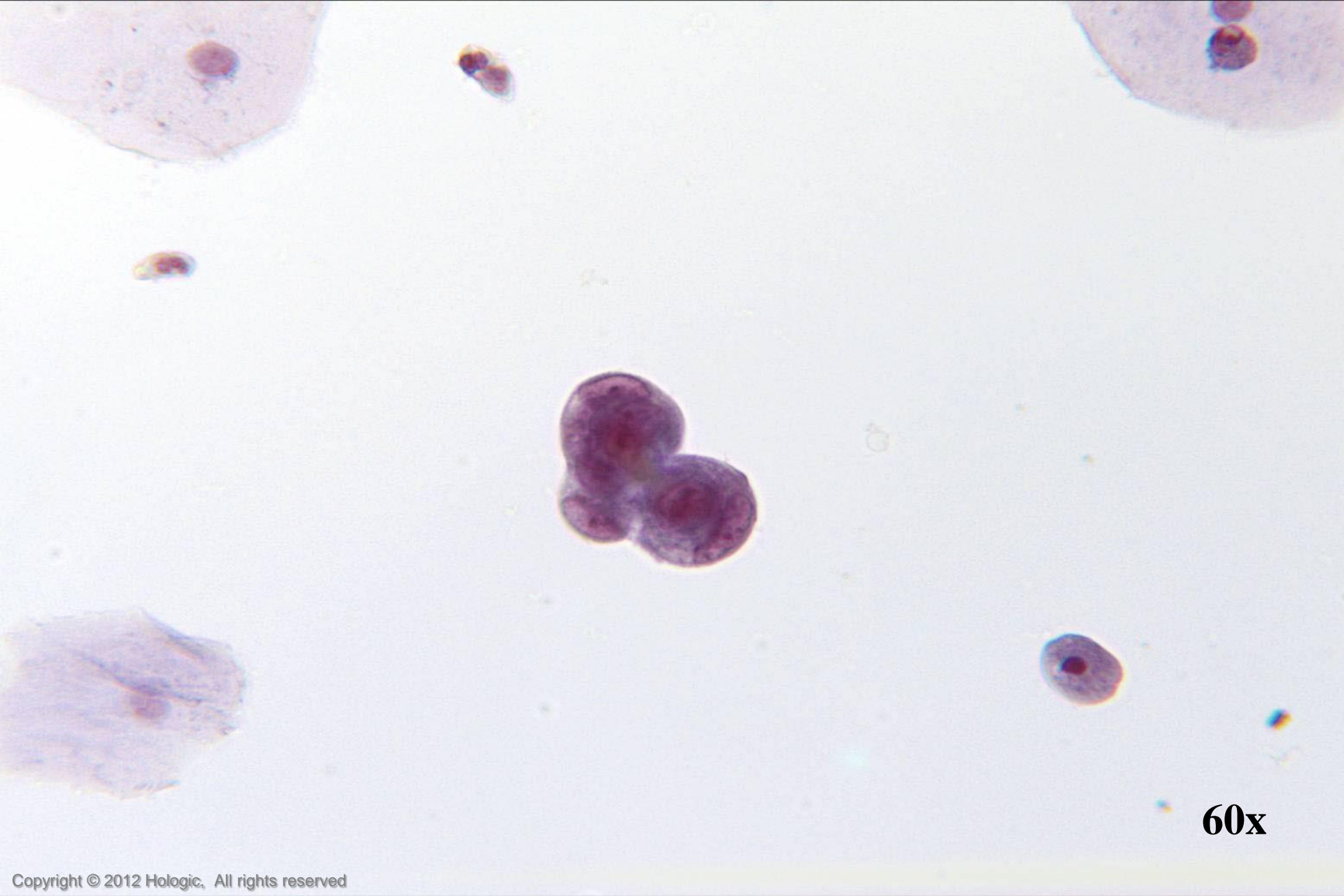
- Abundant abnormal material
 - directly scraped
- ++ Single cells, clusters
- Dense, homogenous cytoplasm
- Centrally located nuclei
- Irregular chromatin clumping
- Prominent, irregular nucleoli



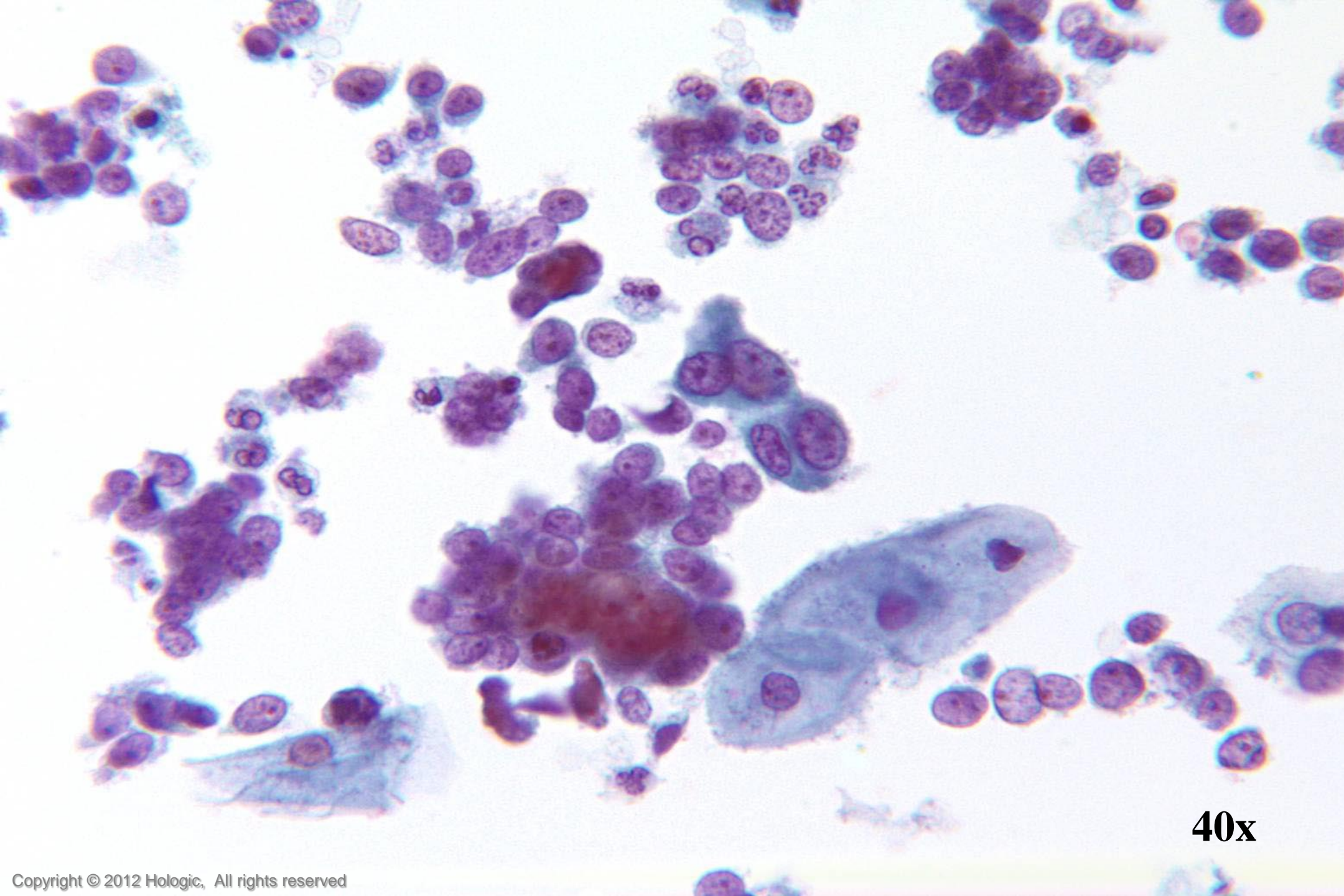
40x



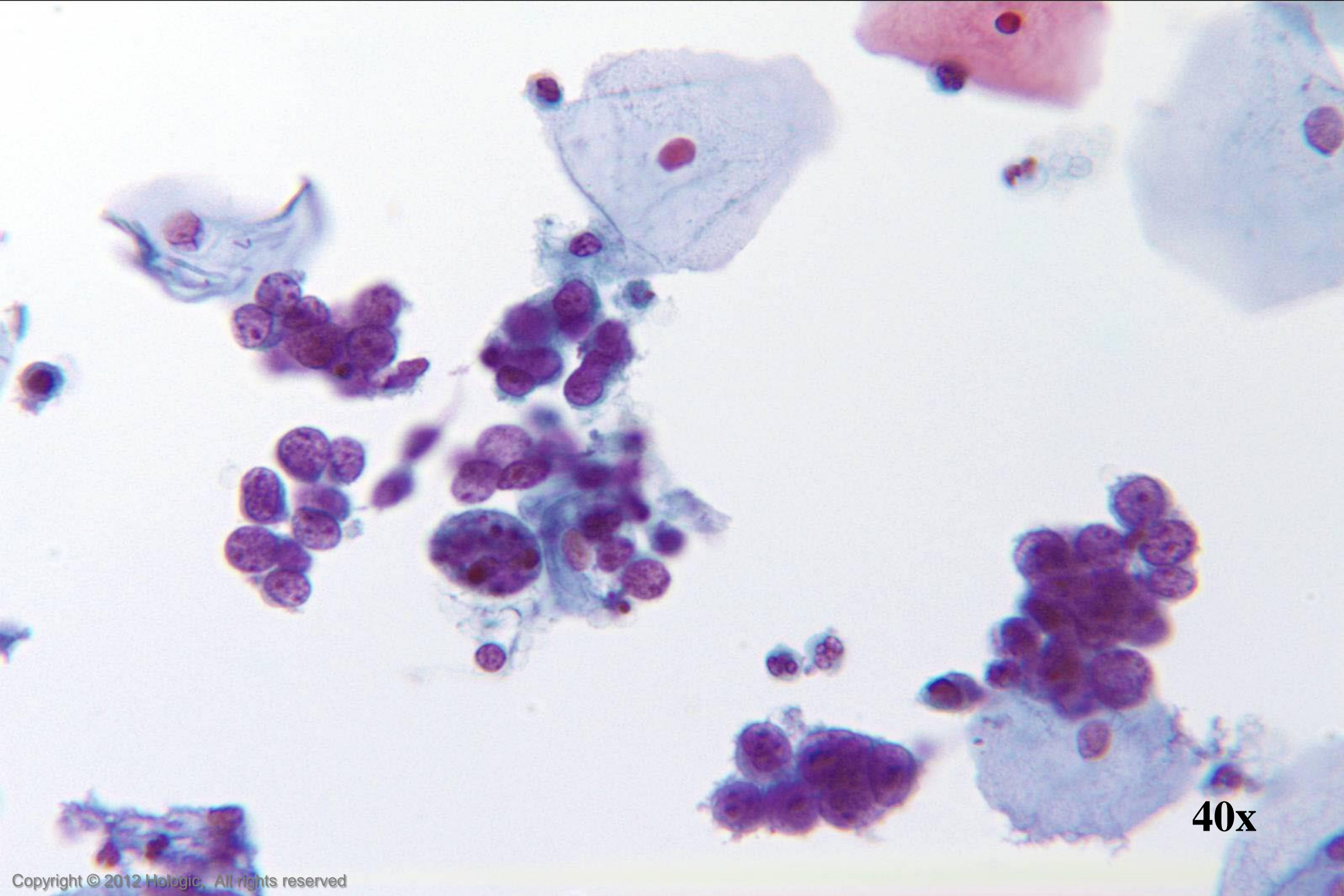
40x



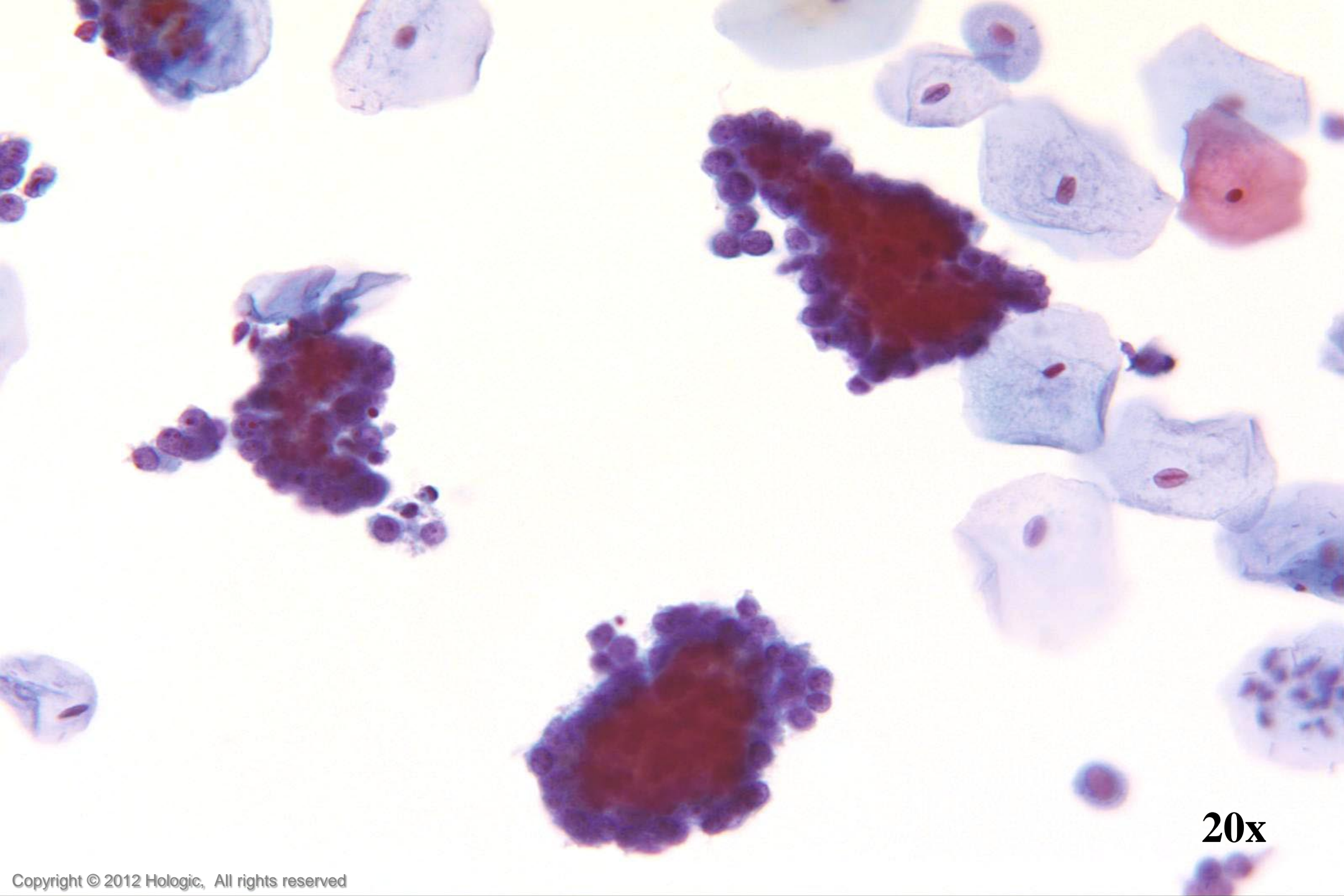
60x



40x



40x



20x

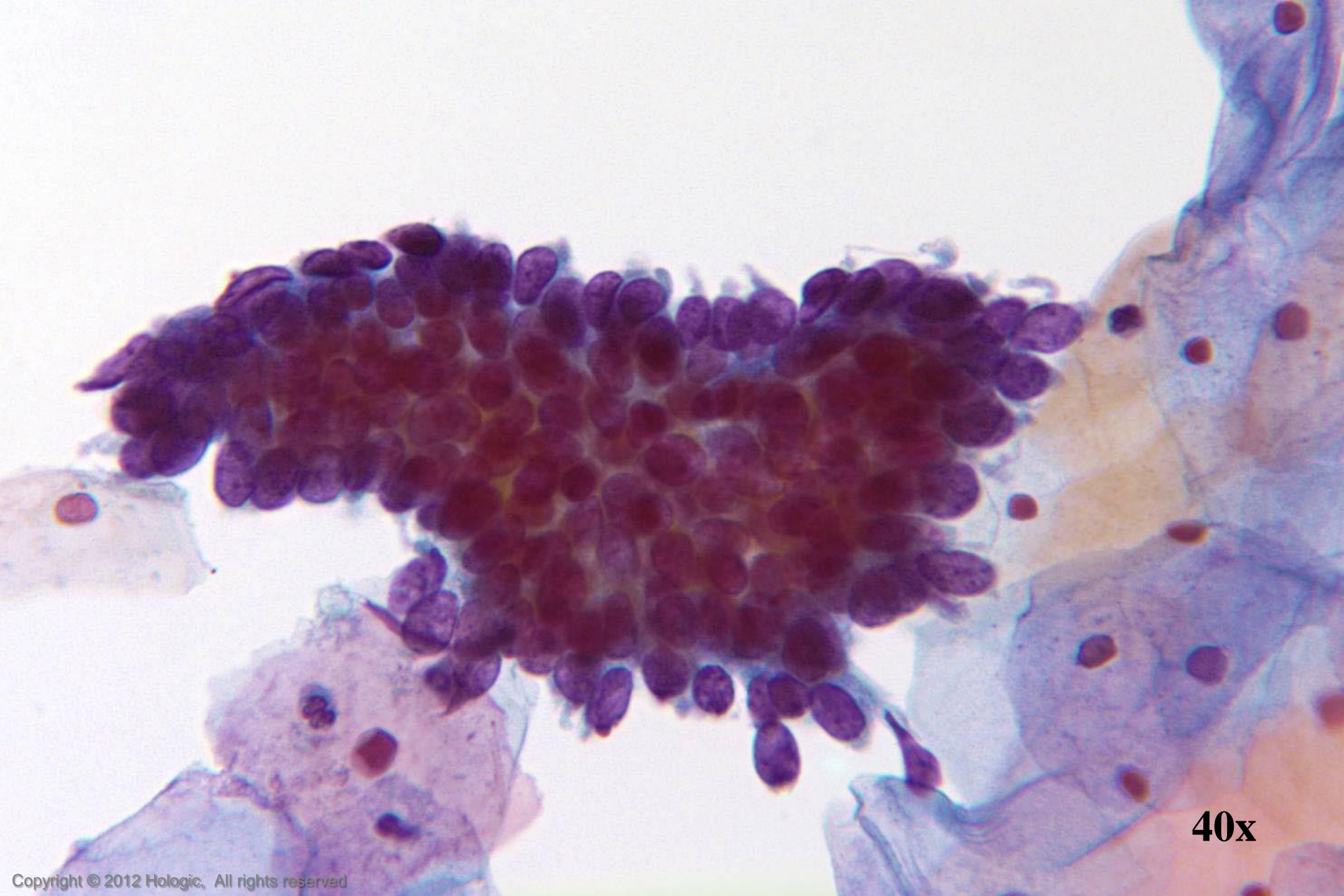
Adenocarcinoma In Situ vs. Tubal Metaplasia

Adenocarcinoma In Situ

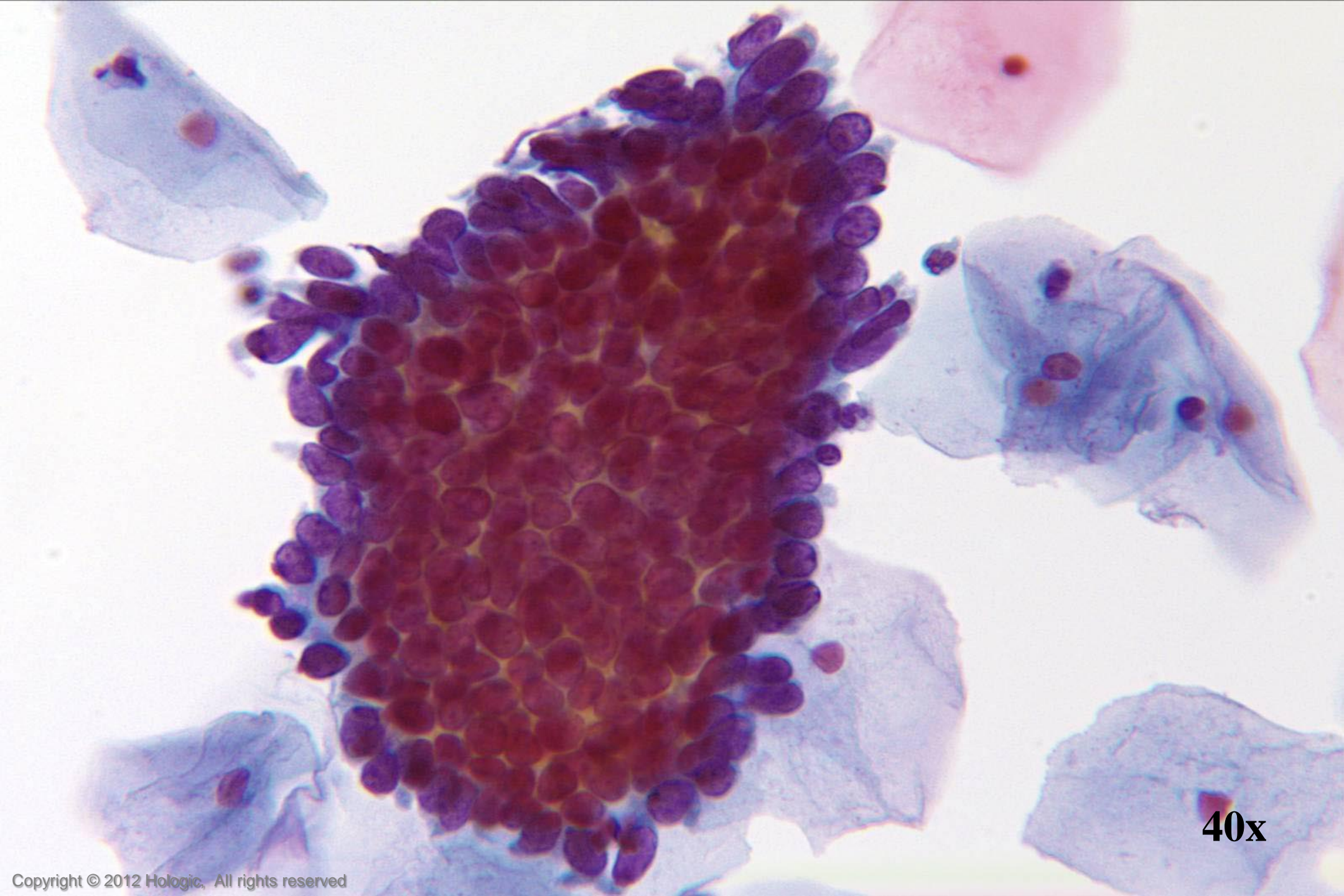
- Crowded sheets & strips
- Feathering & pseudostratification
- Relative hyperchromasia
- Uniformly stippled chromatin
- Nuclear size and shape variation
- Block-like nucleoli
- Mitoses and apoptotic bodies

Tubal Metaplasia

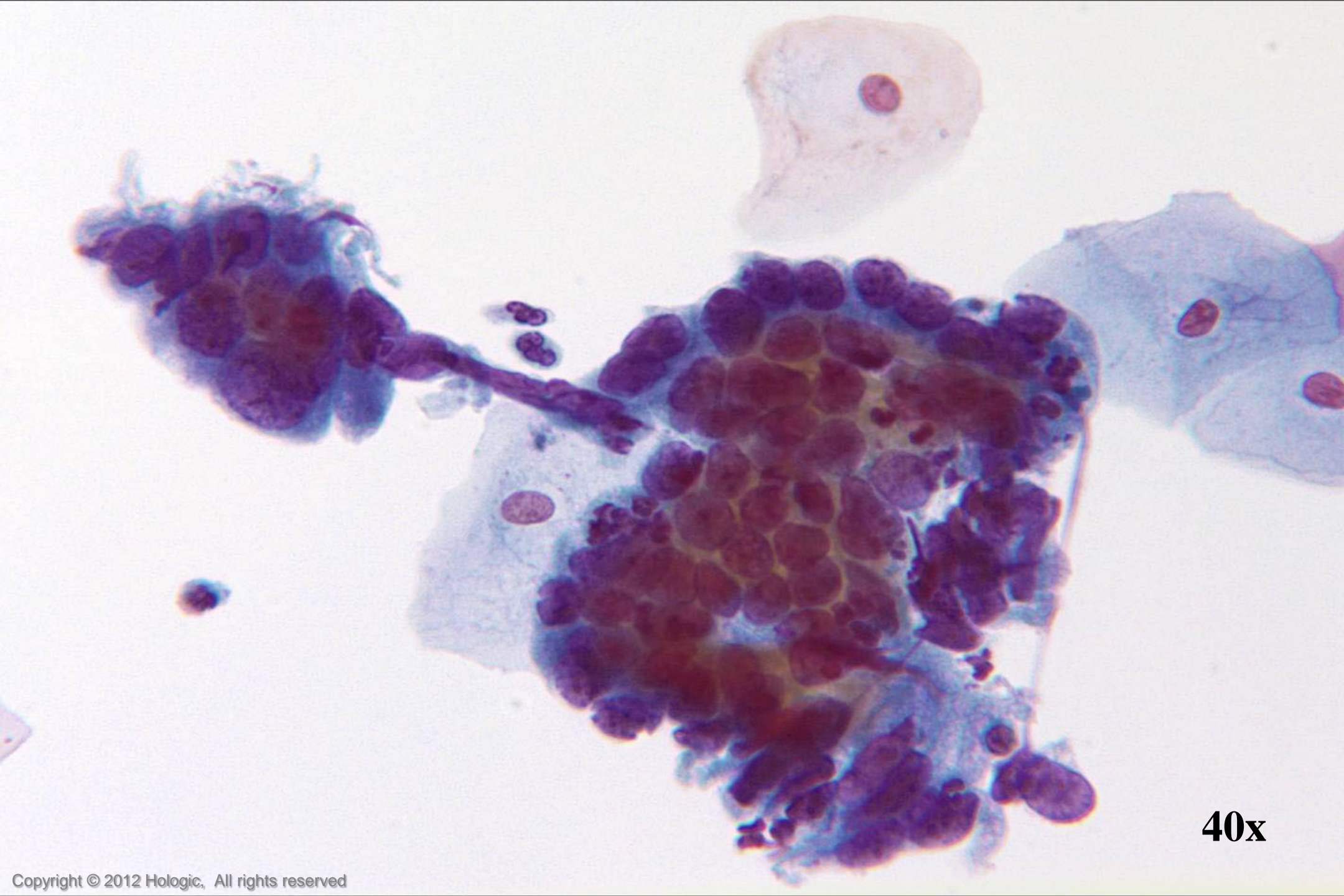
- Cilia and/or terminal bars reliably identified
- Crowding without overlap, lacking depth of focus
- Evenly distributed chromatin
- Cytoplasm dense and cuboidal
- Nucleoli absent
- Nuclear membrane irregularities and thickening absent
- Occasional elongate nuclear forms



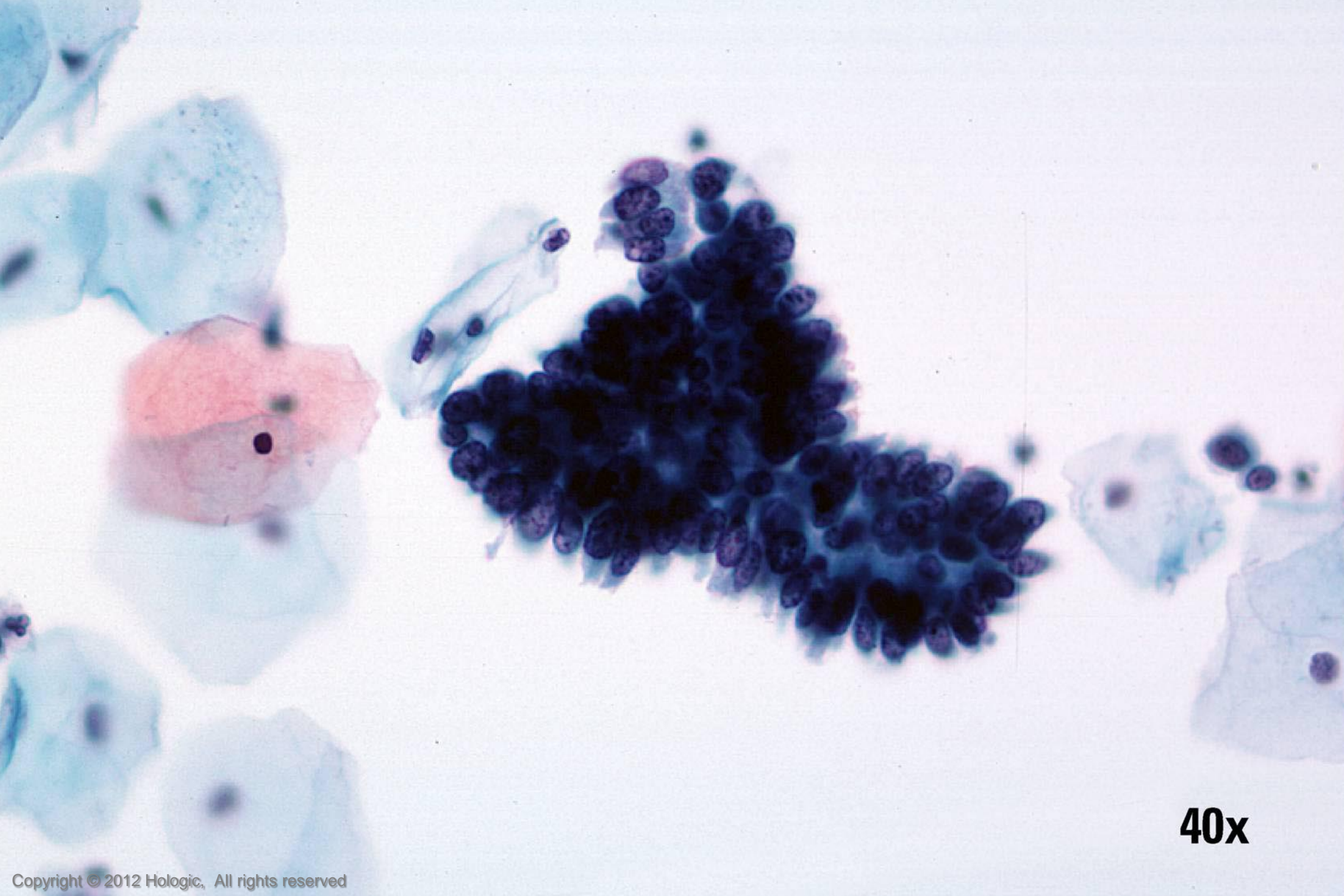
40x



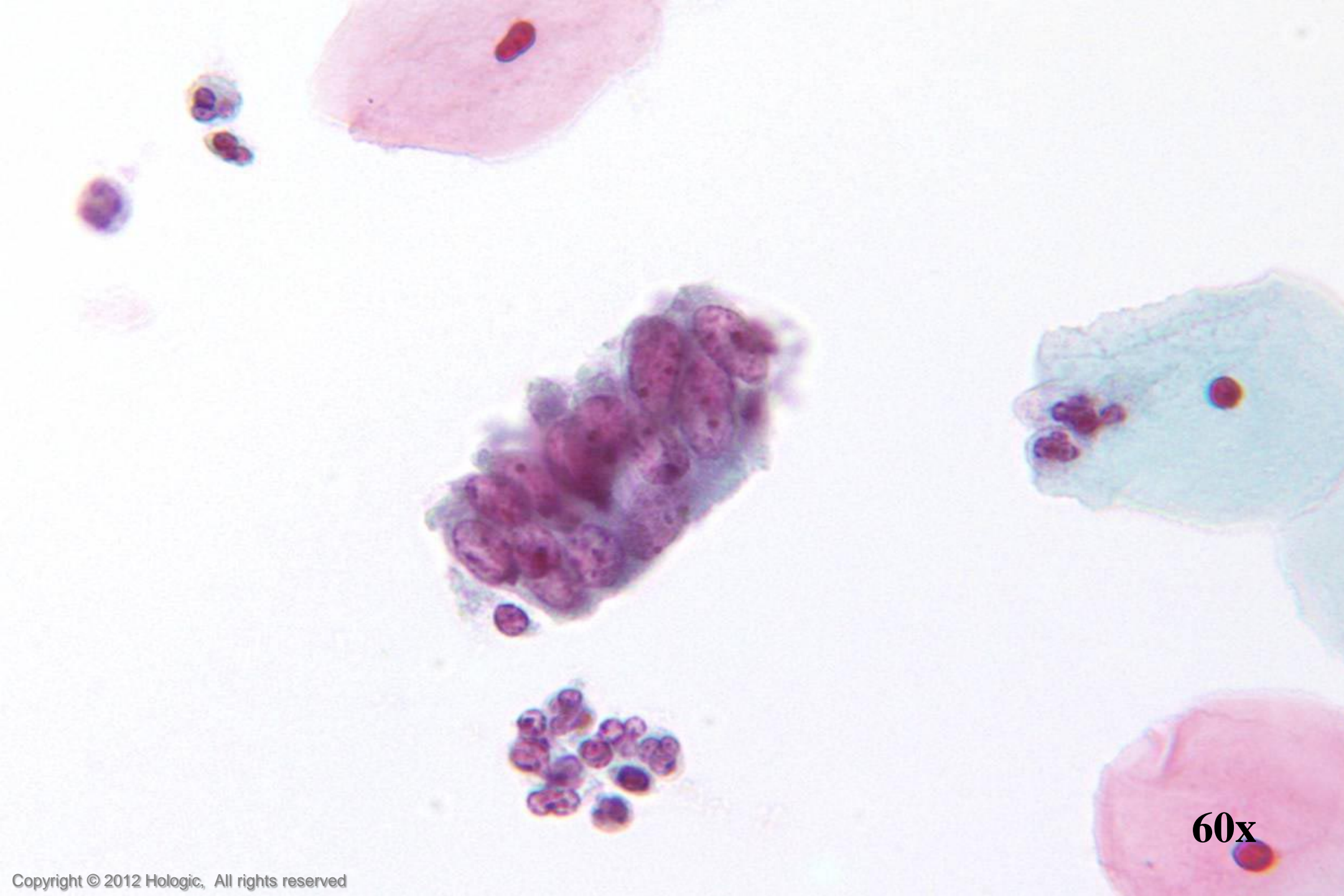
40x



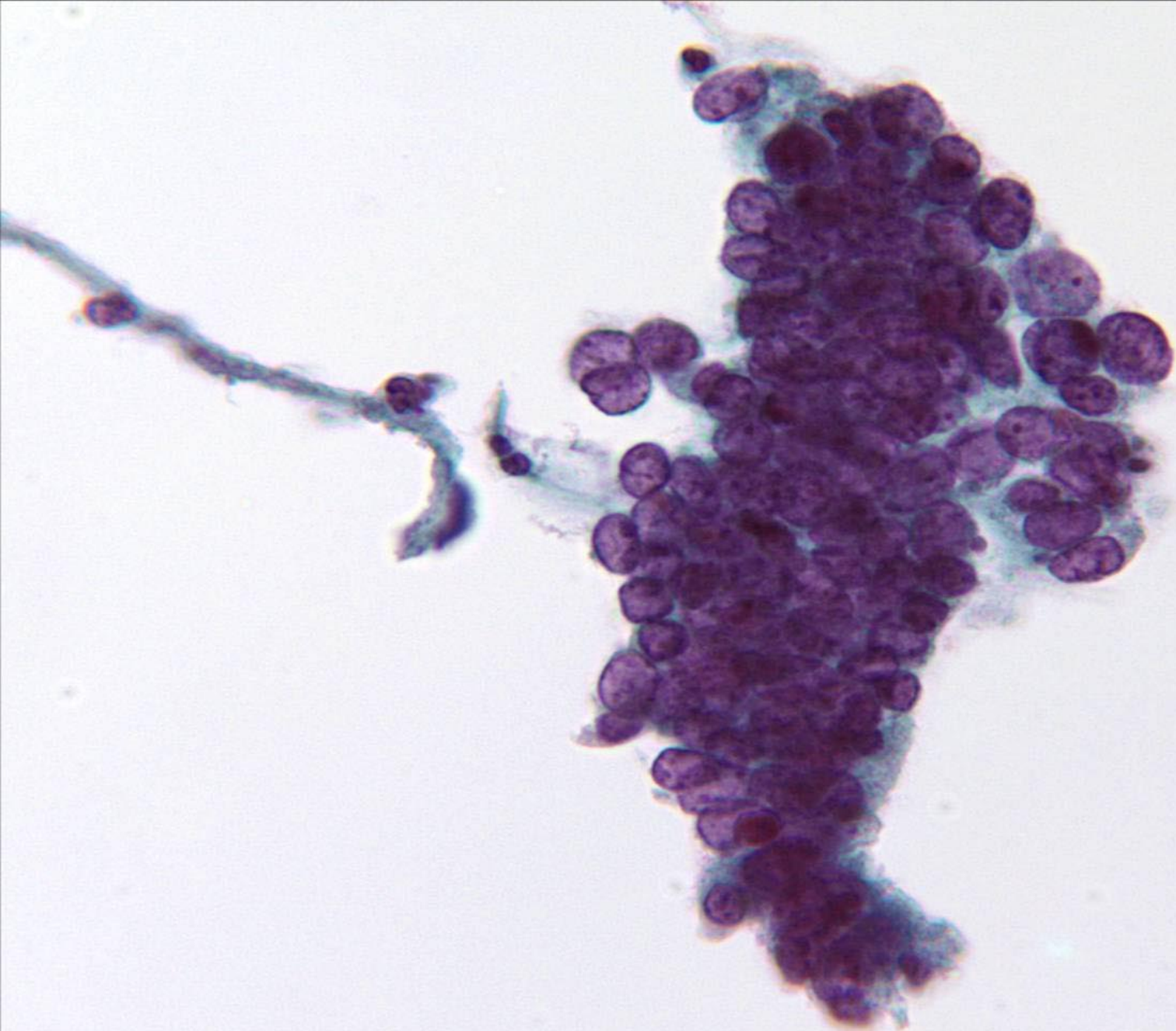
40x



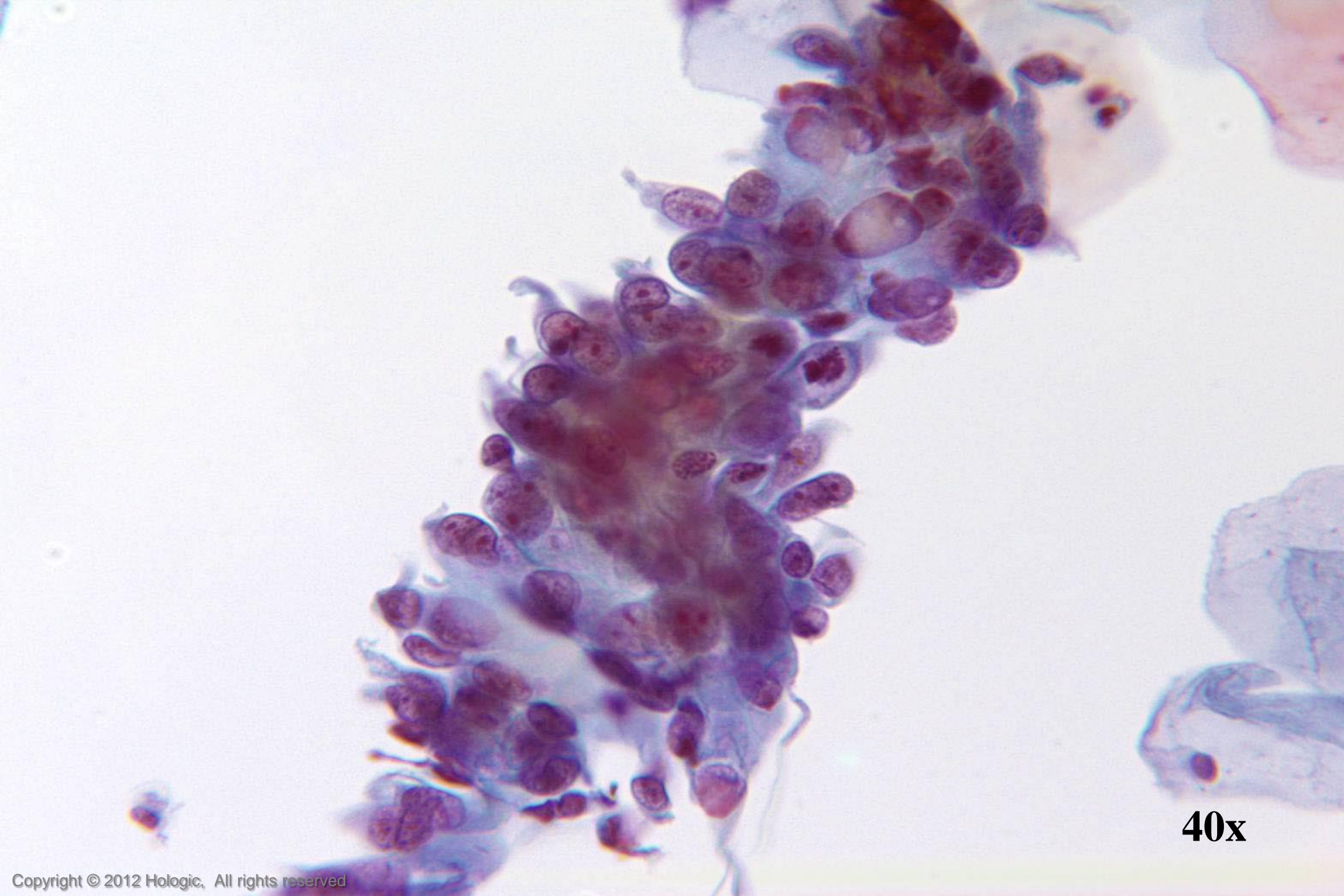
40x



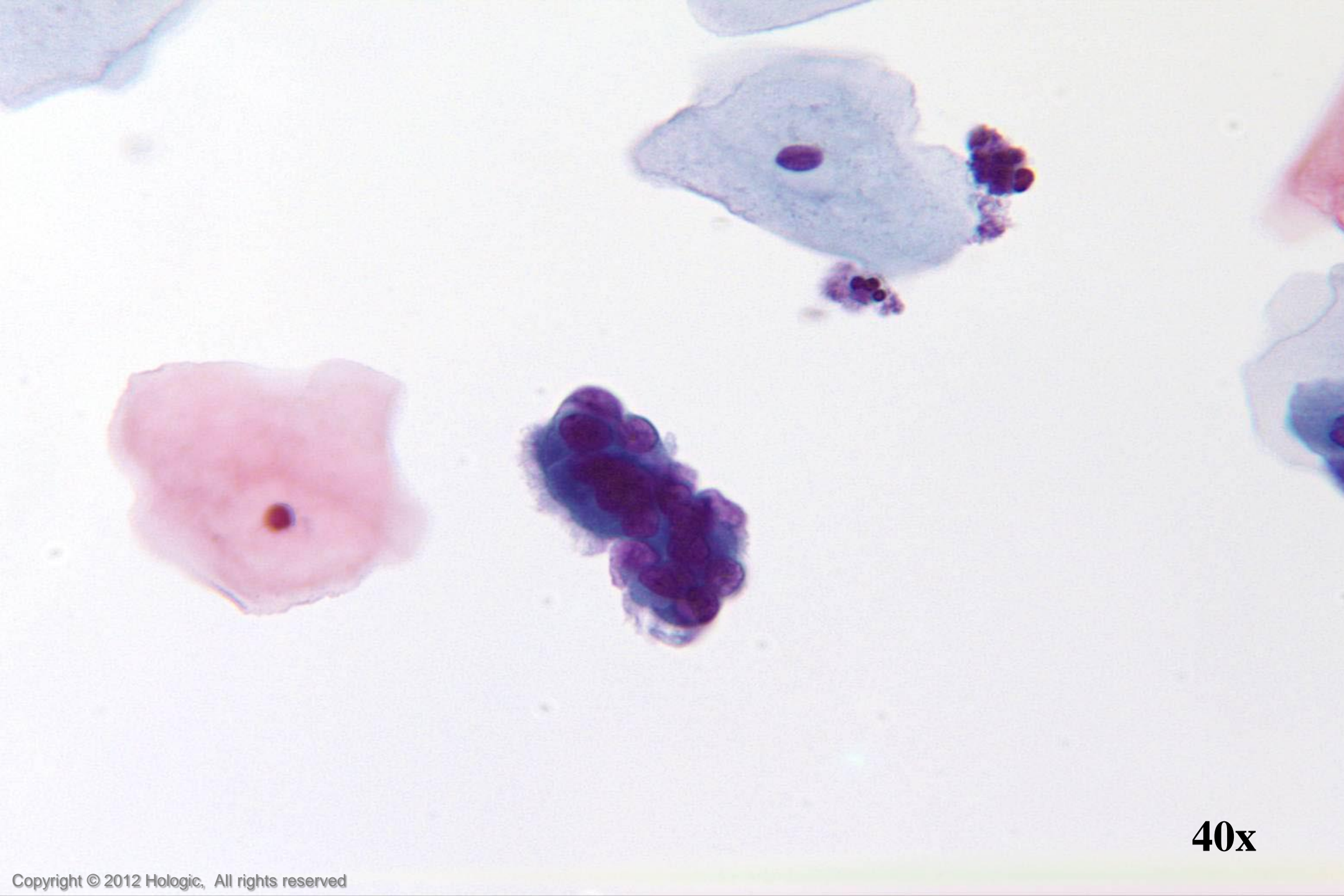
60x



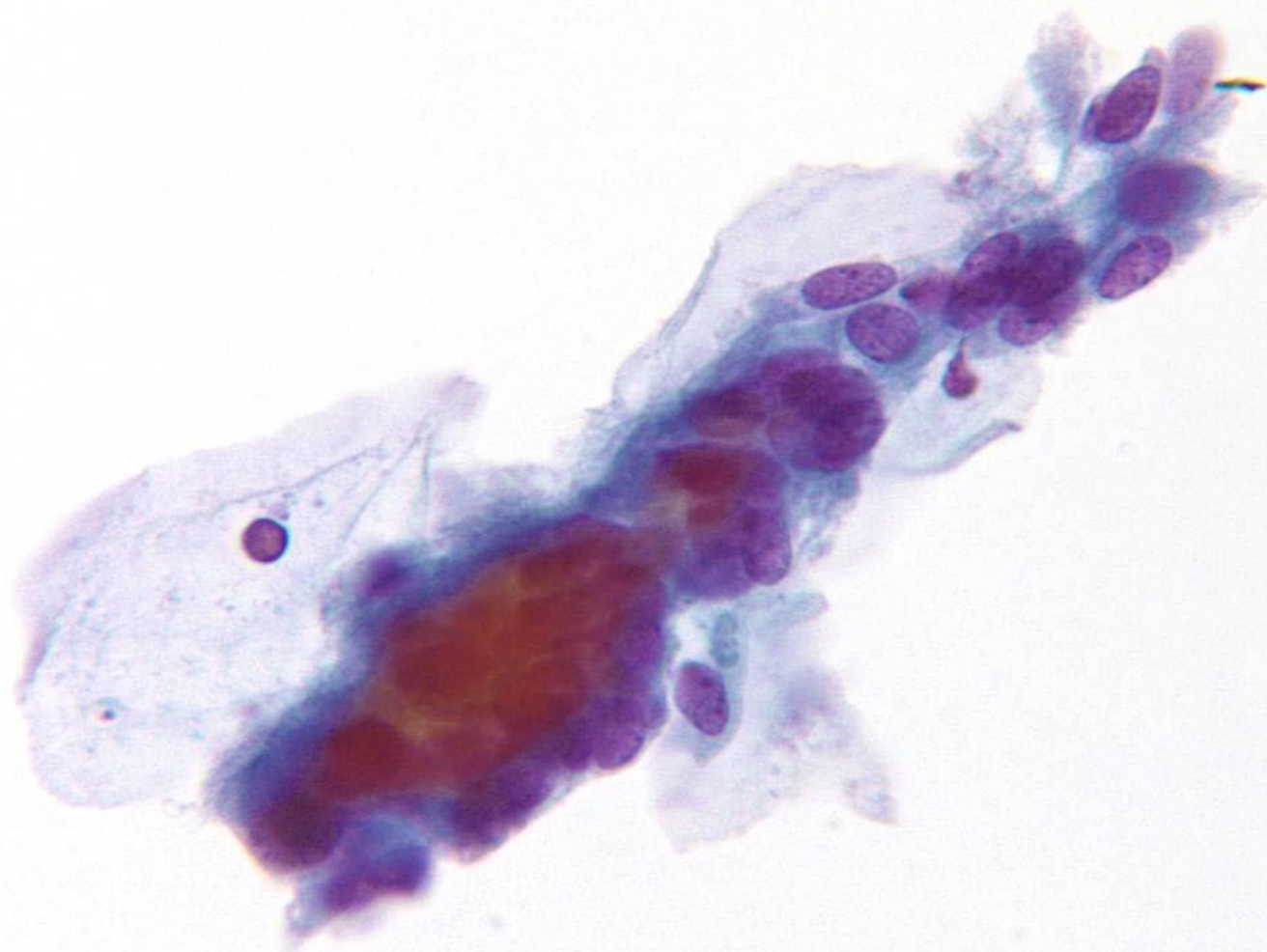
40x



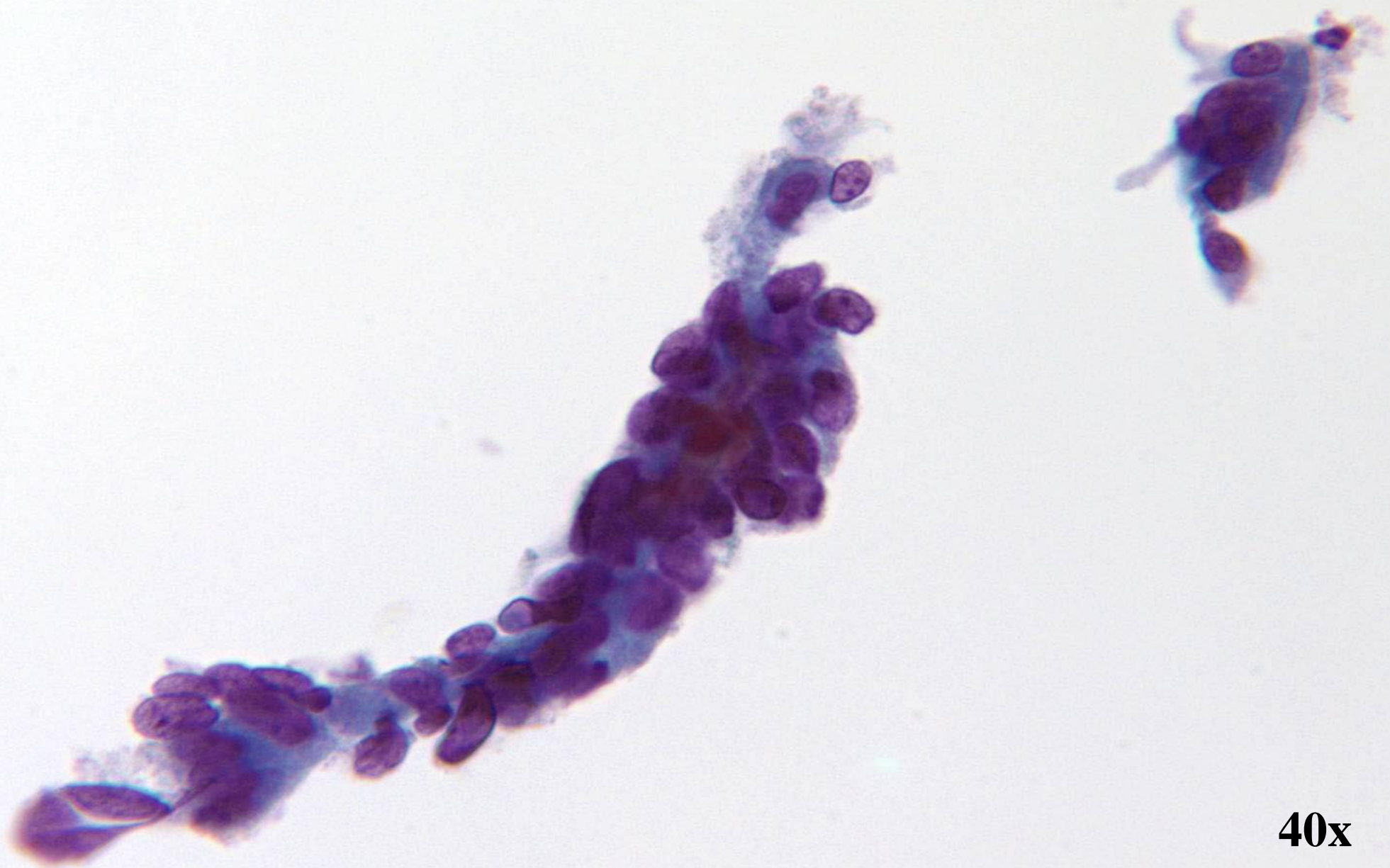
40x



40x



40x



40x

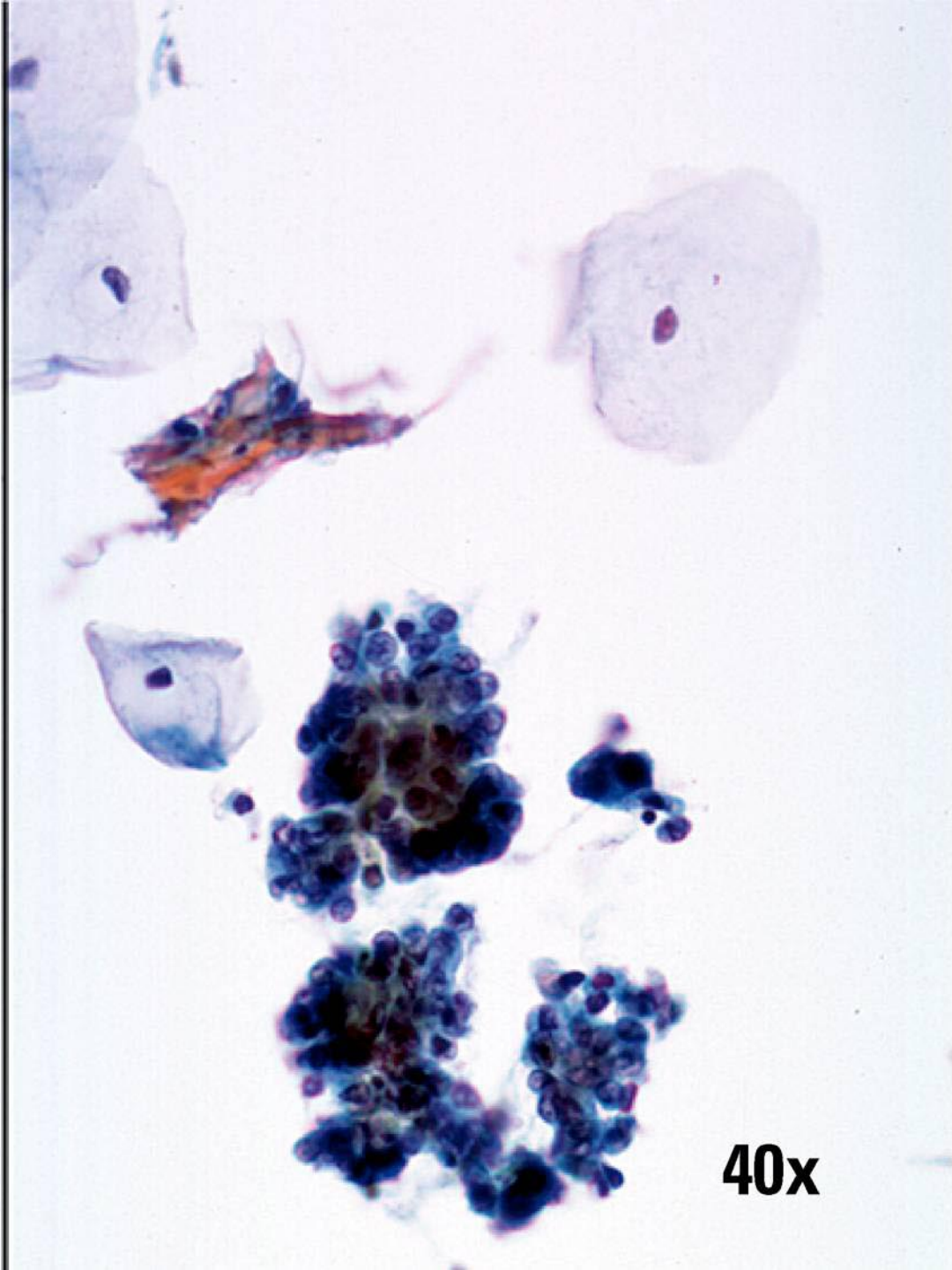
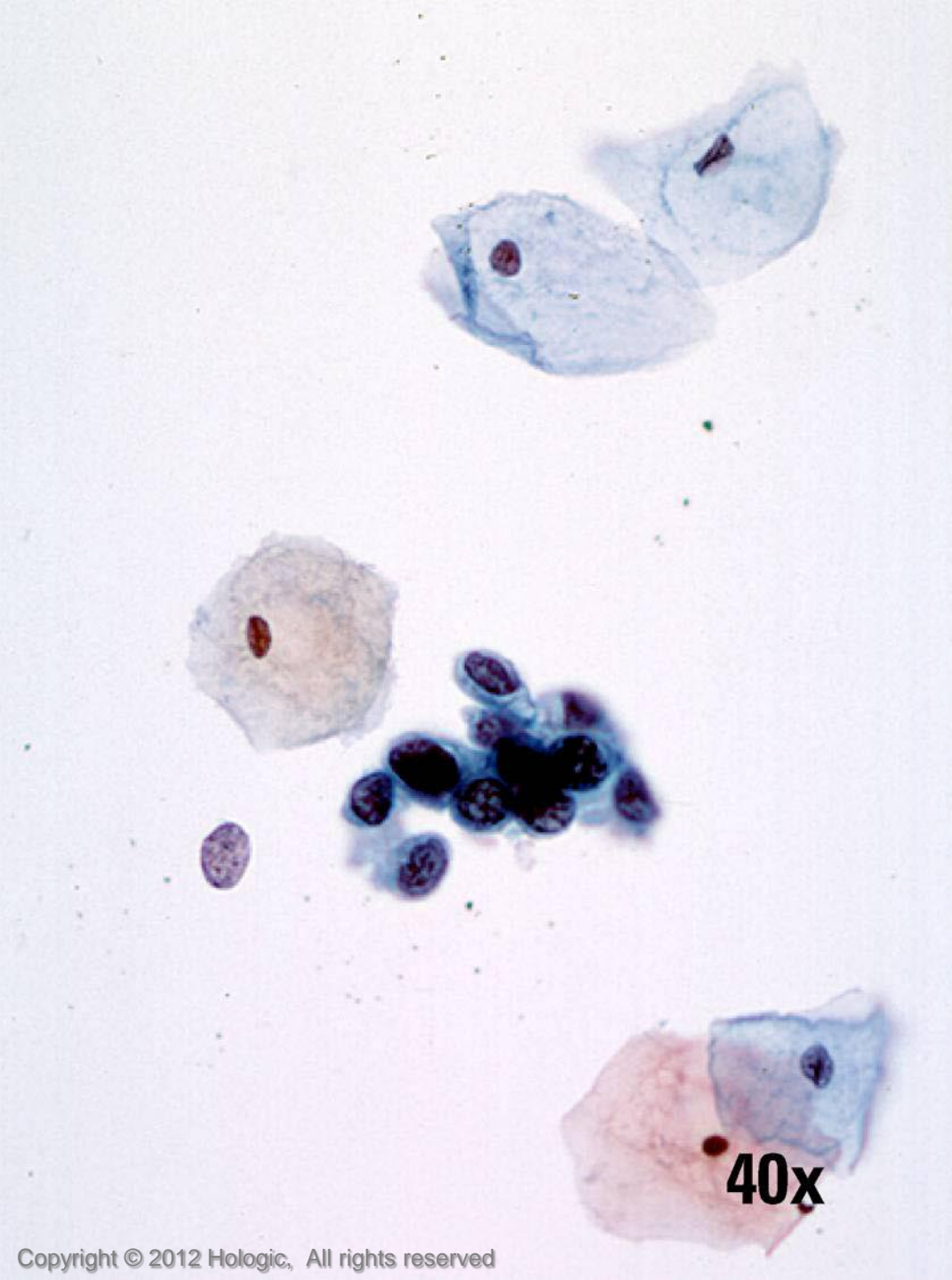
HSIL vs. Endometrial Cells

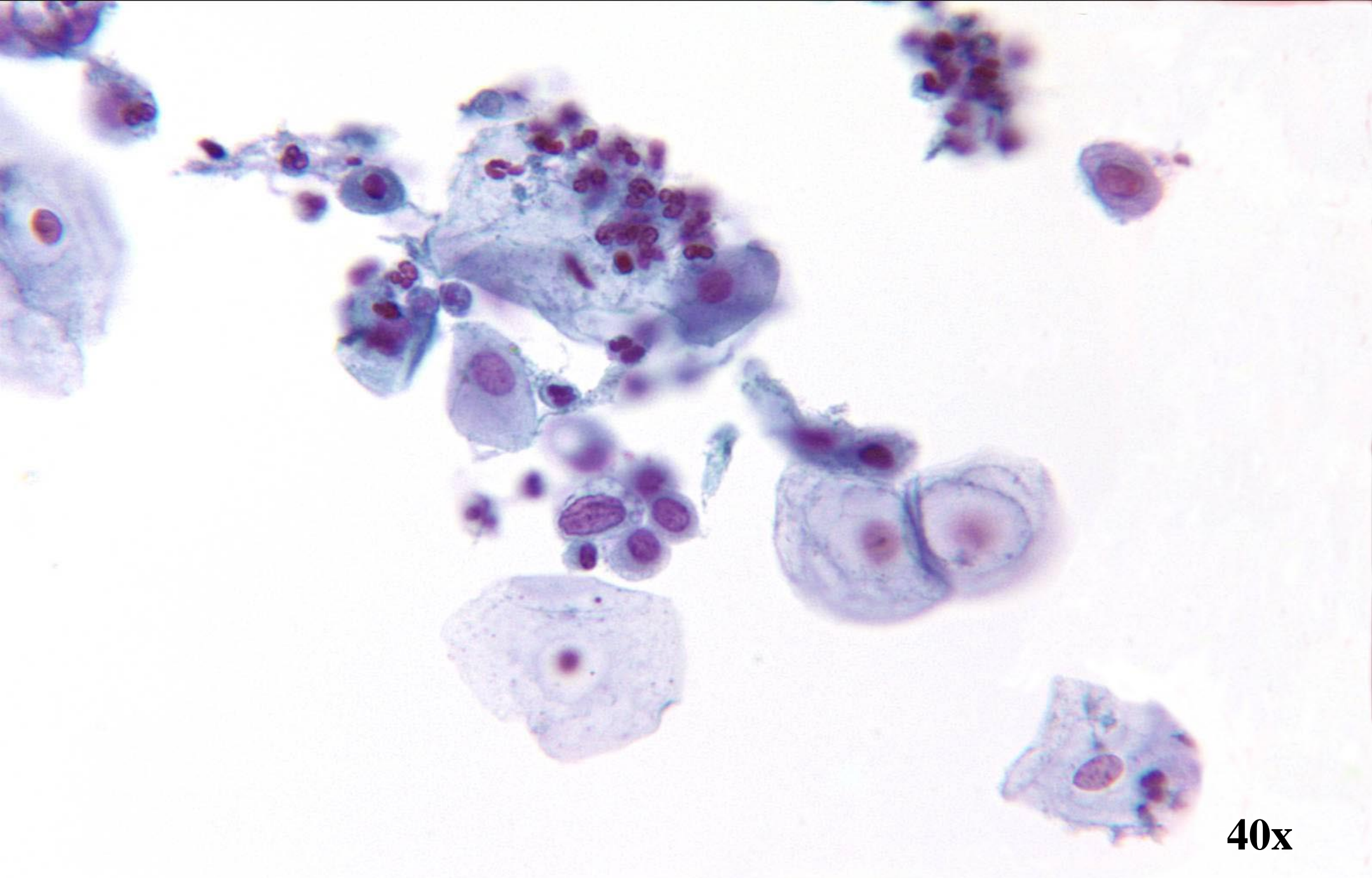
HSIL

- Sheets, syncytia; thick plaques rather than 3D ball-like clusters
- Hyperchromasia
- Irregular nuclear membranes
- Single cells have centrally located nuclei
- Dense homogenous cytoplasm

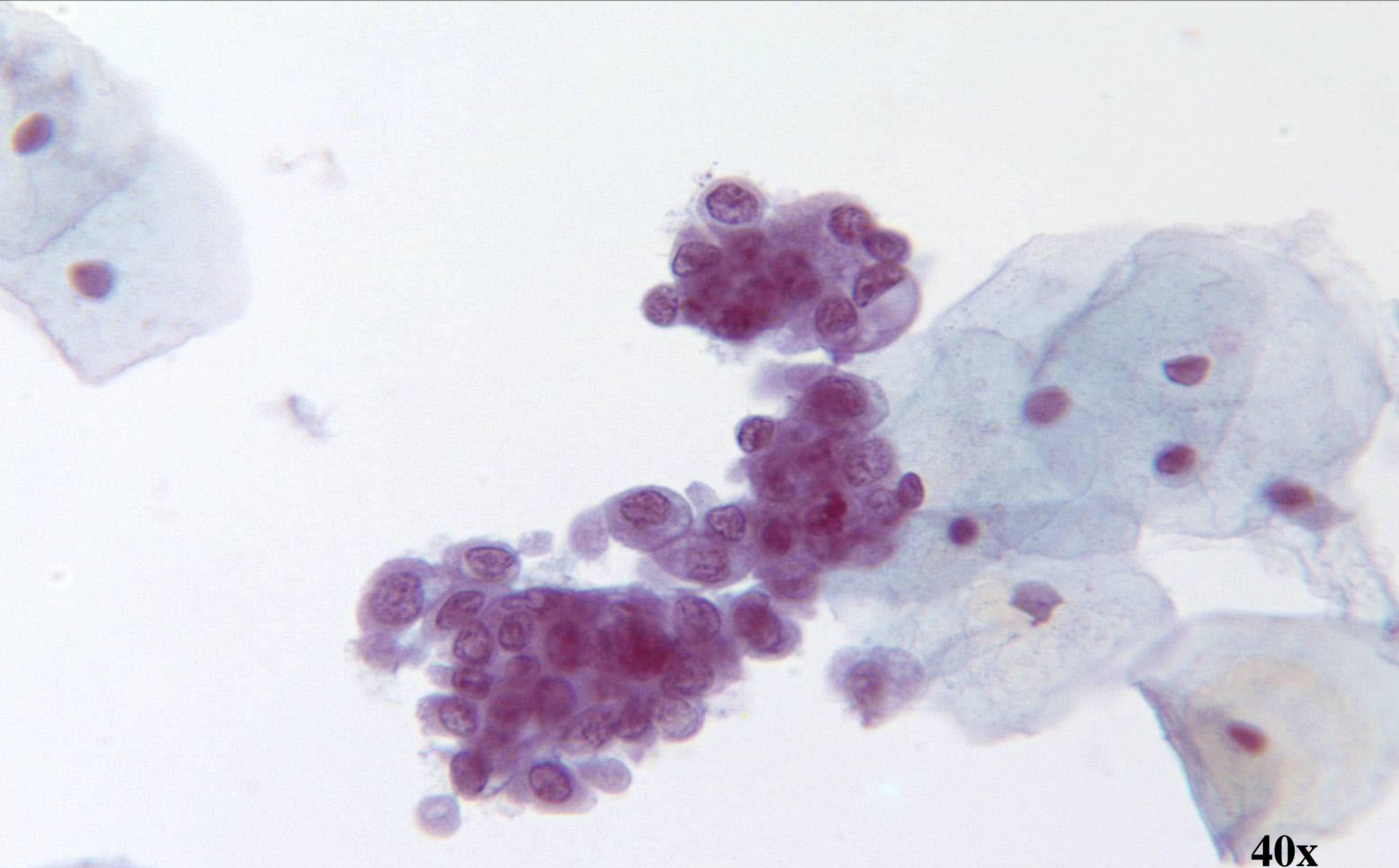
Endometrial Cells

- 3D ball-like clusters and small, single cells
- Relative hyperchromasia
- Regular nuclear membranes
- Single cells with eccentrically located nuclei
- Scant basophilic cytoplasm with cytoplasmic “blebs”

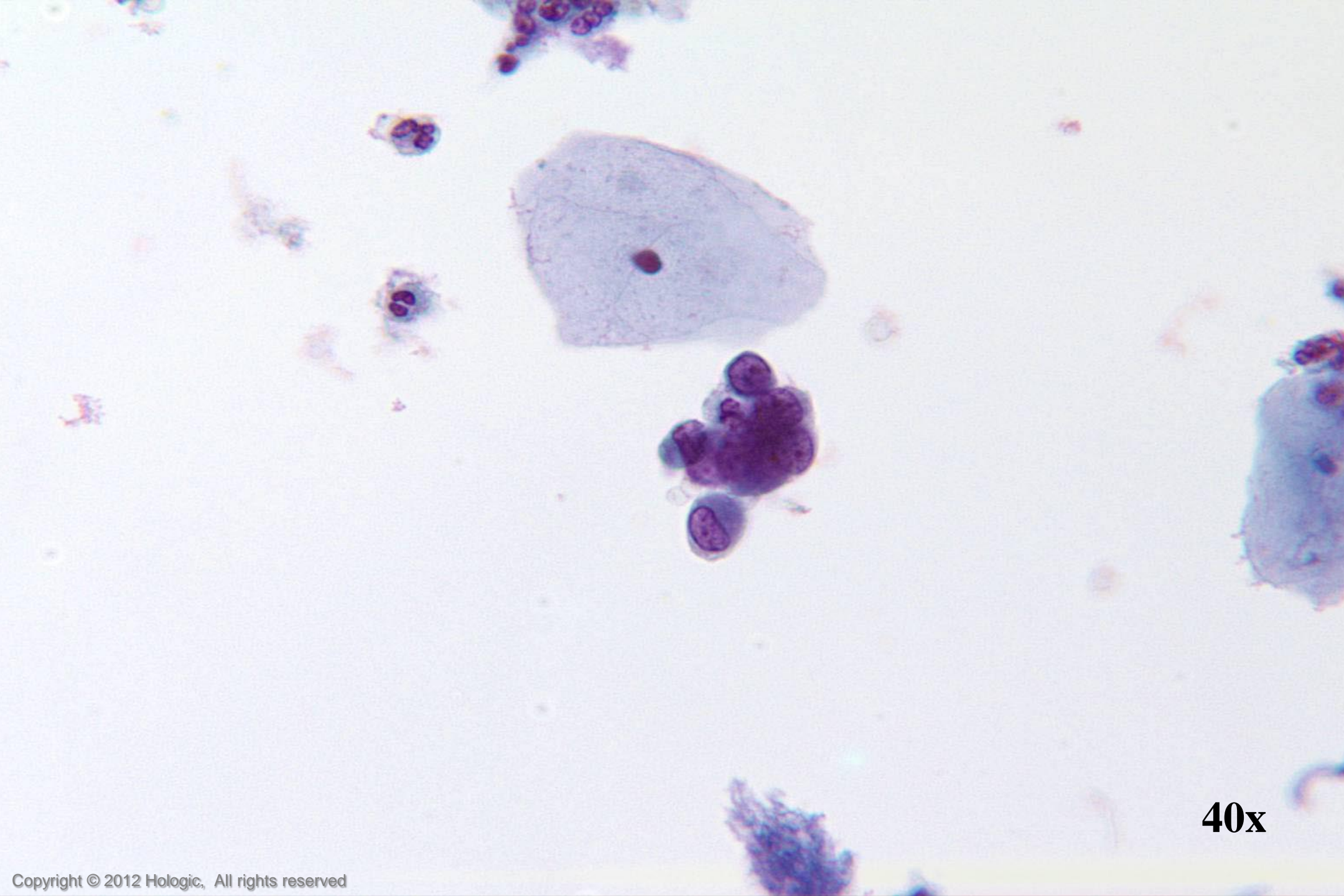




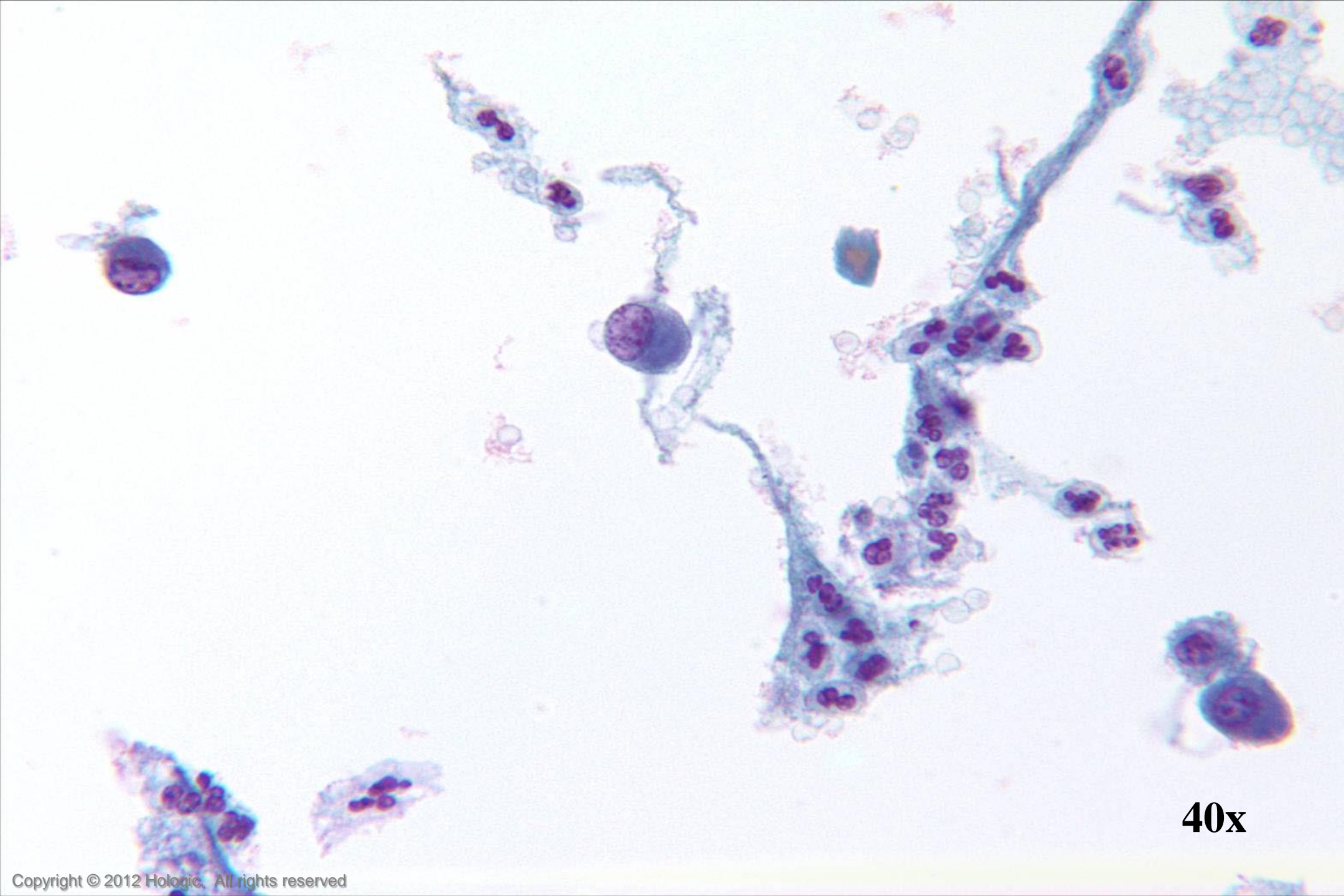
40x



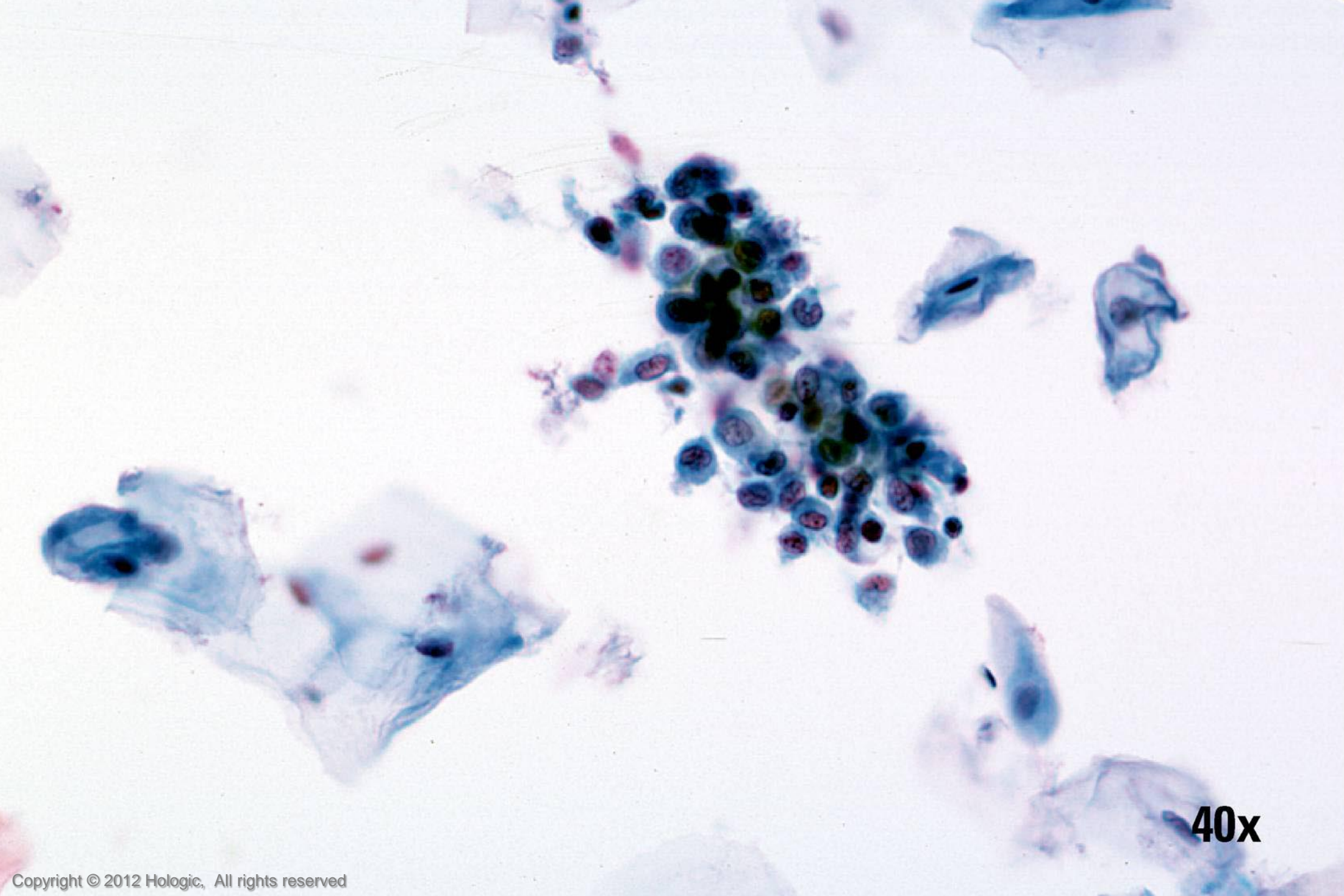
40x



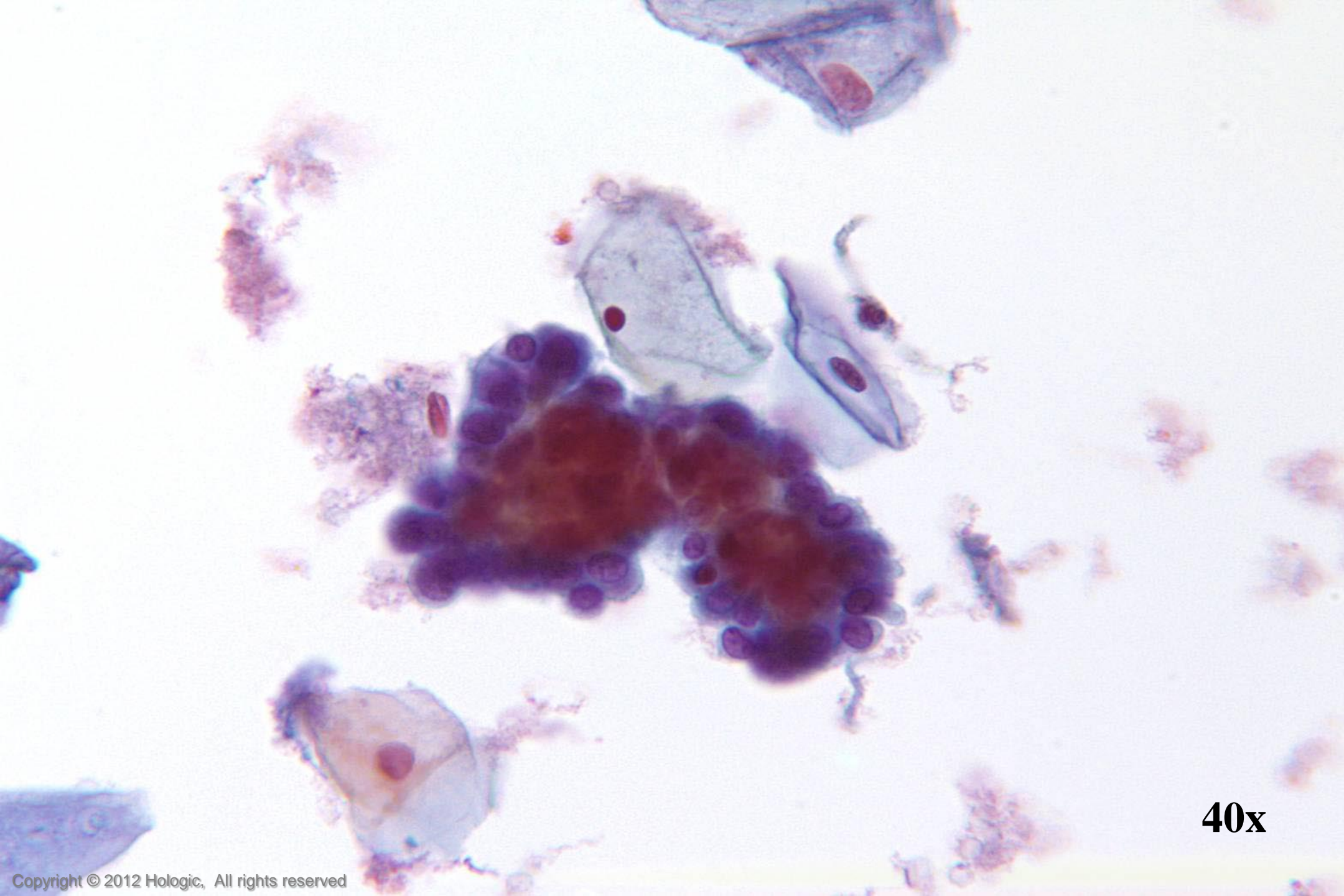
40x



40x



40x



40x

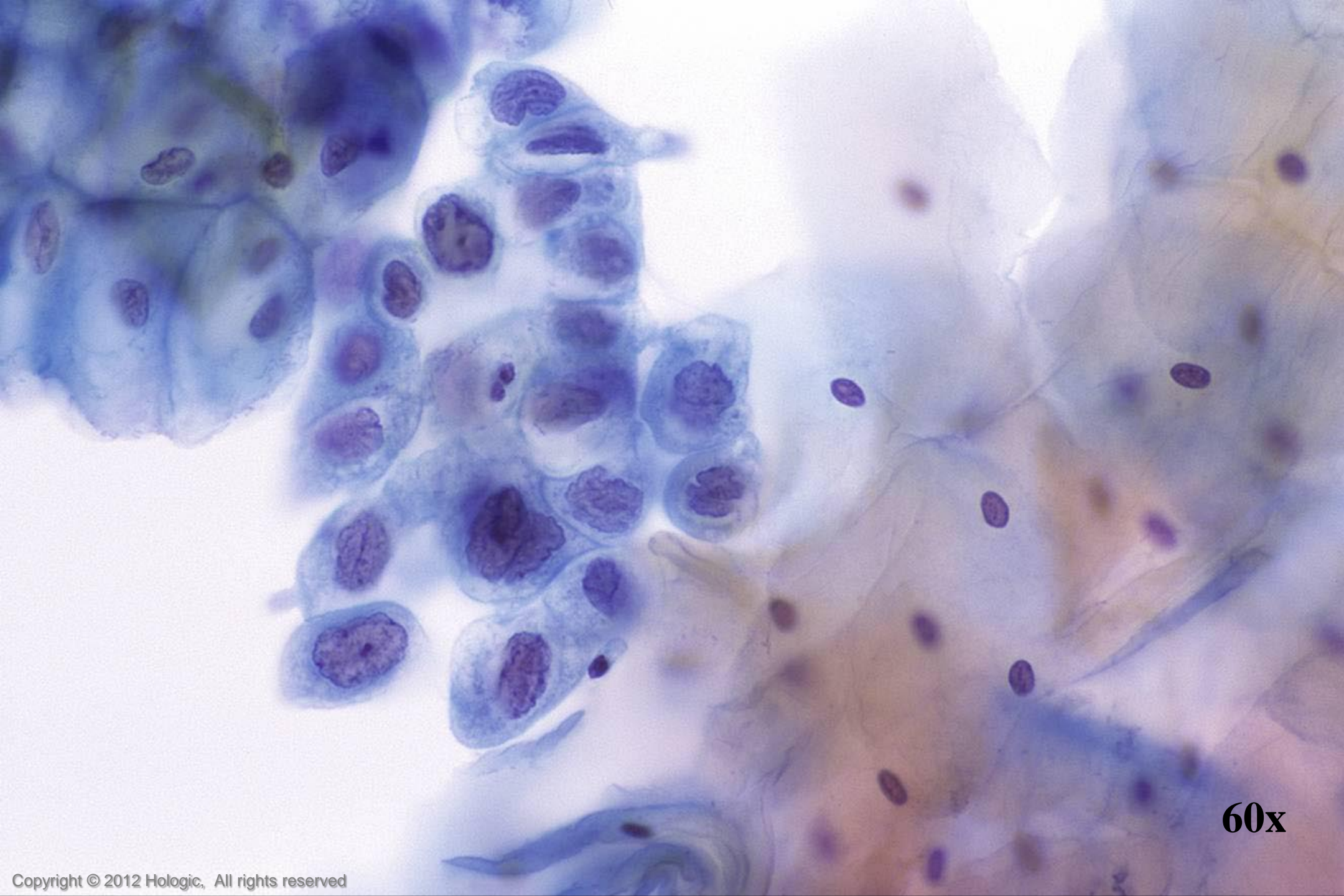
HSIL vs. Immature Squamous Metaplasia

HSIL

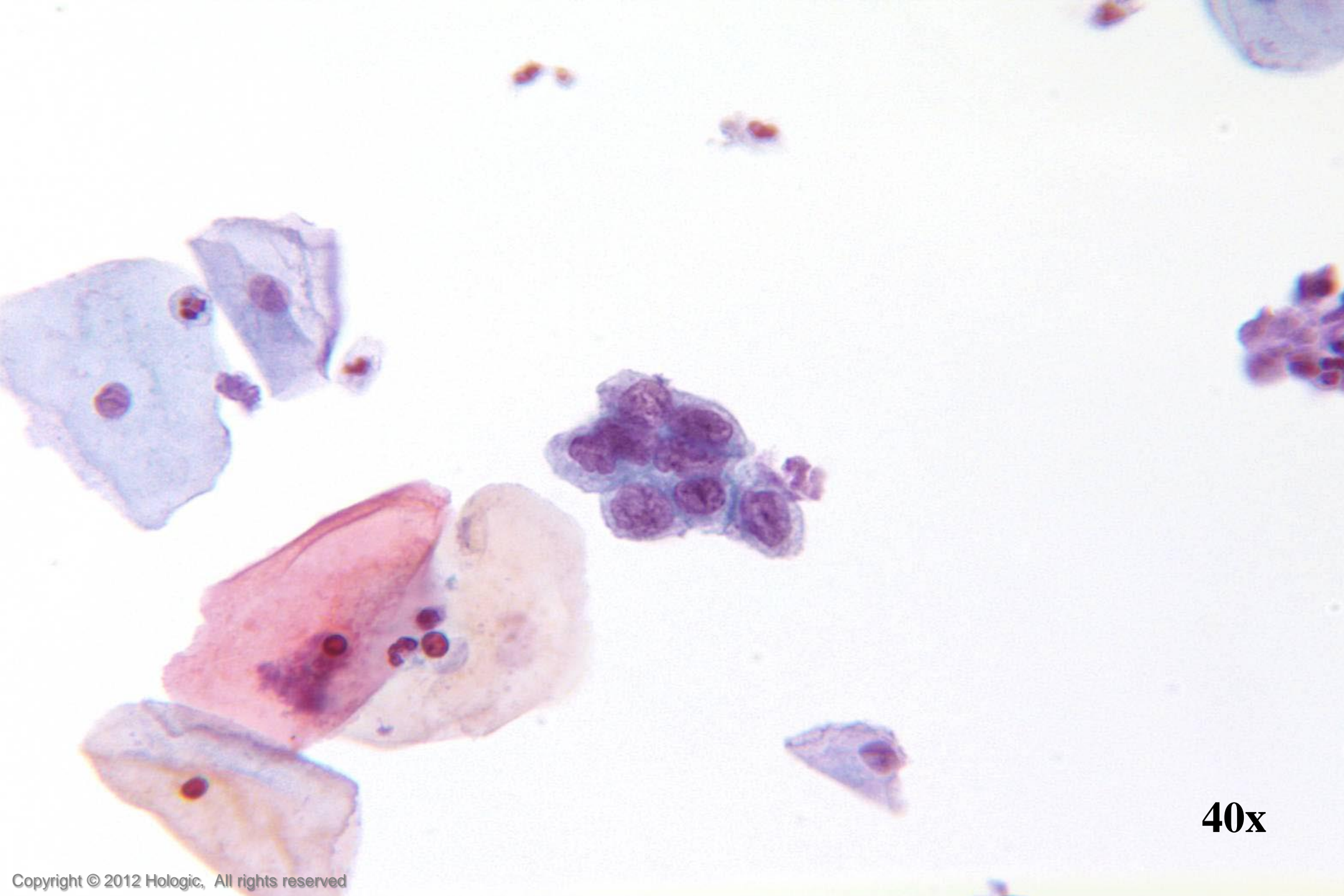
- Single cells, clusters, and thickened plaques
- Variable hyperchromasia
- Irregular nuclear membranes
- Coarse clumped chromatin
- Variation in nuclear size within a cluster

Immature Squamous Metaplasia

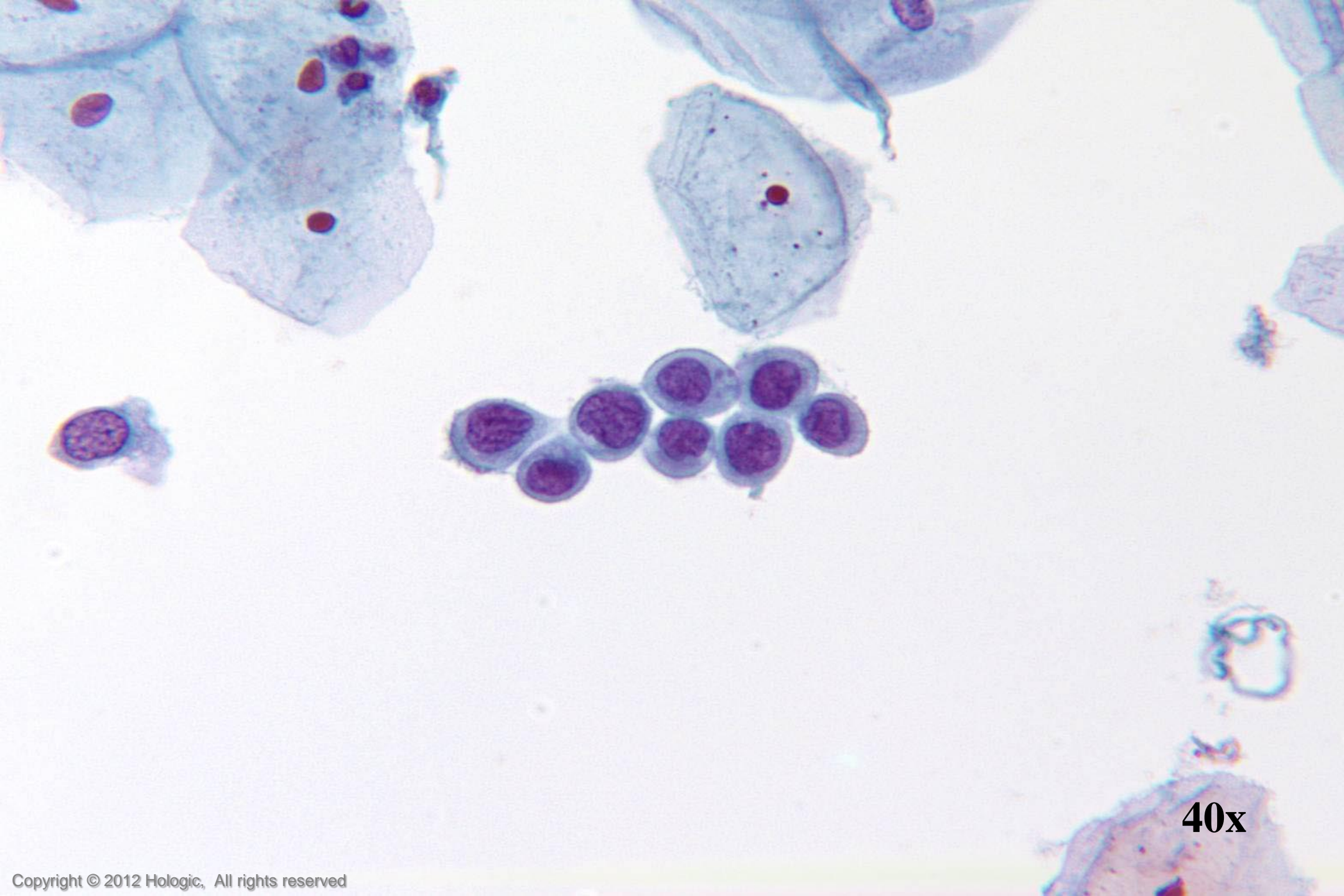
- Single cells & cobblestone sheets
- Normochromatic
- Regular nuclear membranes
- Evenly distributed chromatin with pinpoint chromocenters
- Nuclear size & shape consistent



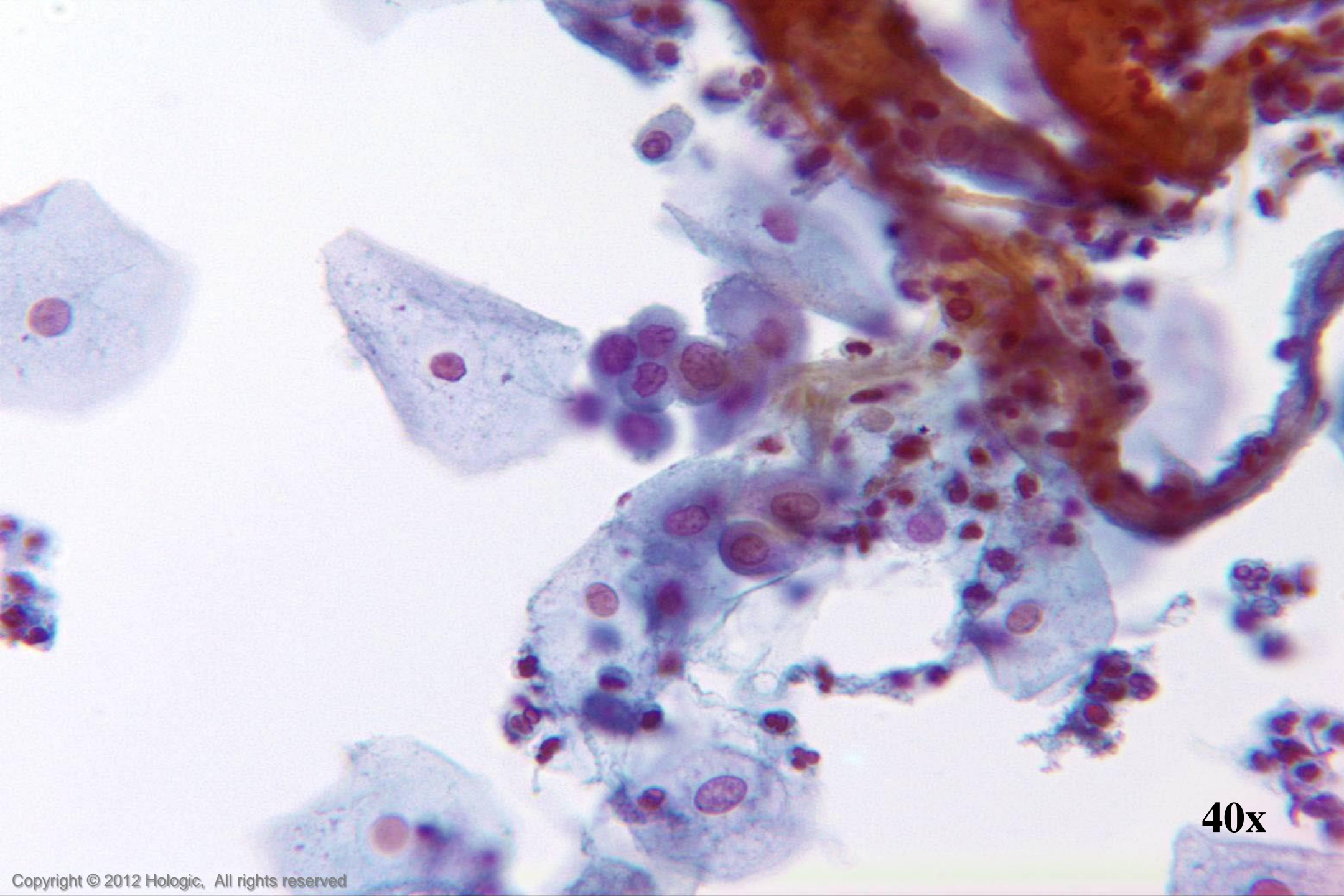
60x



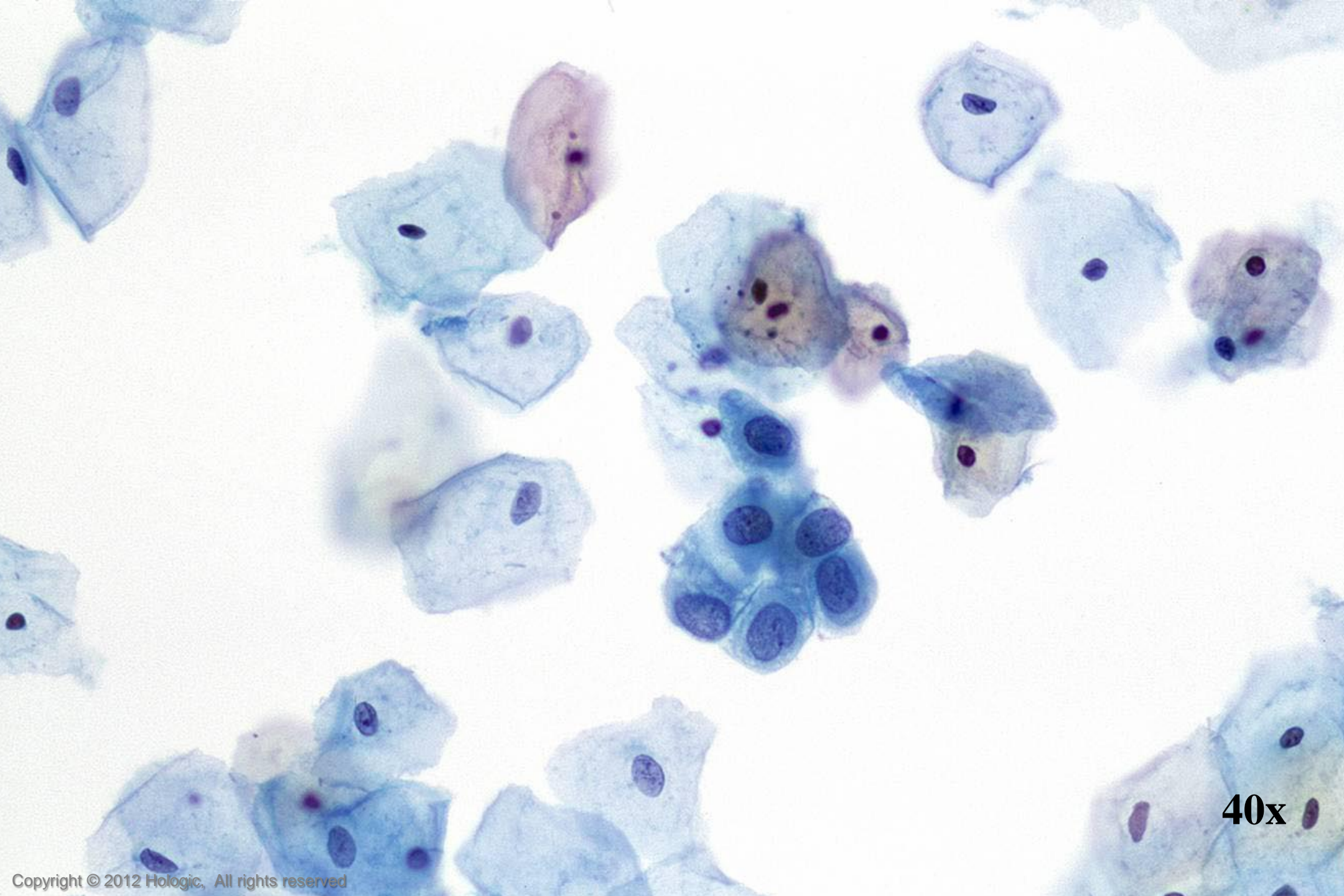
40x



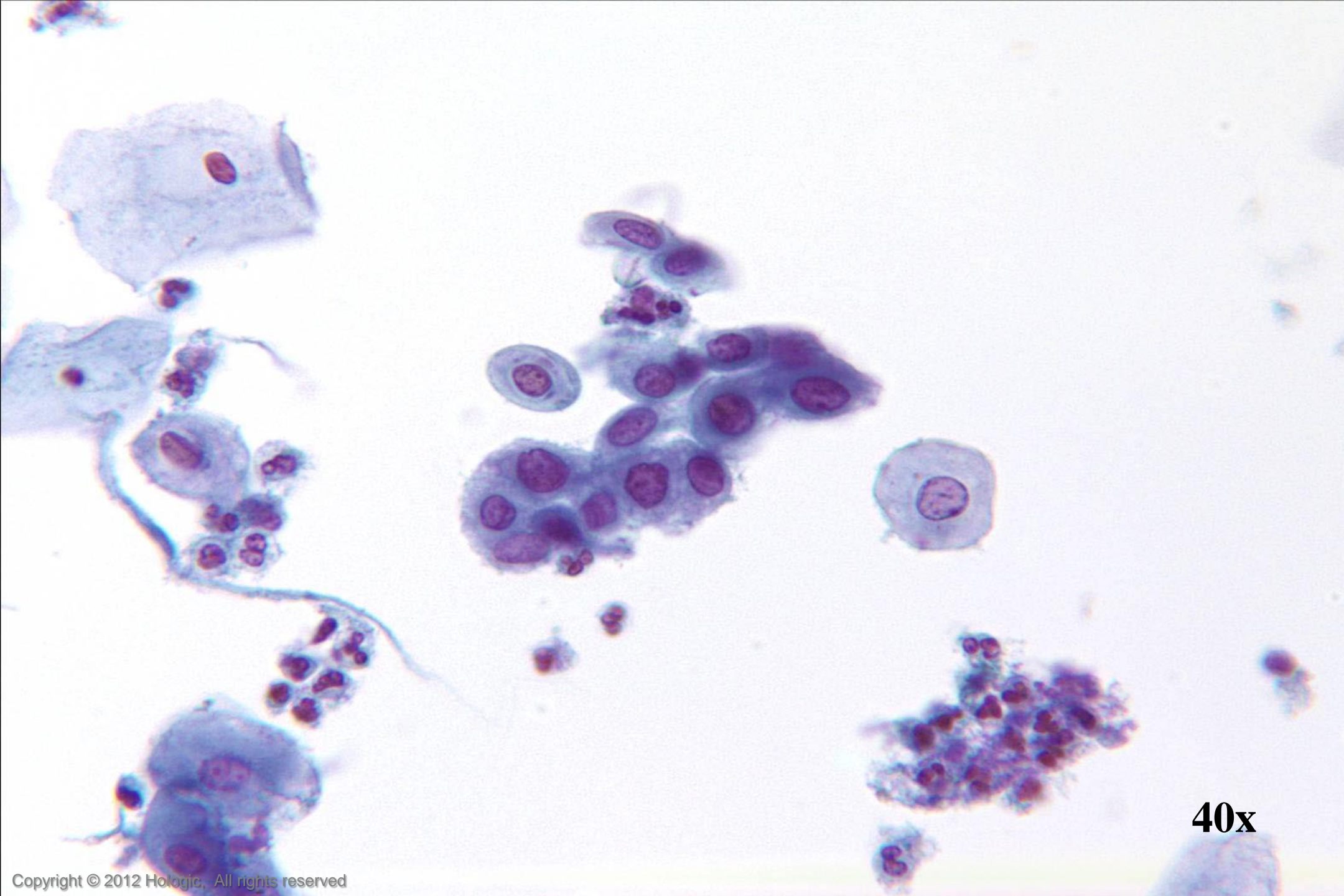
40x



40x



40x



40x

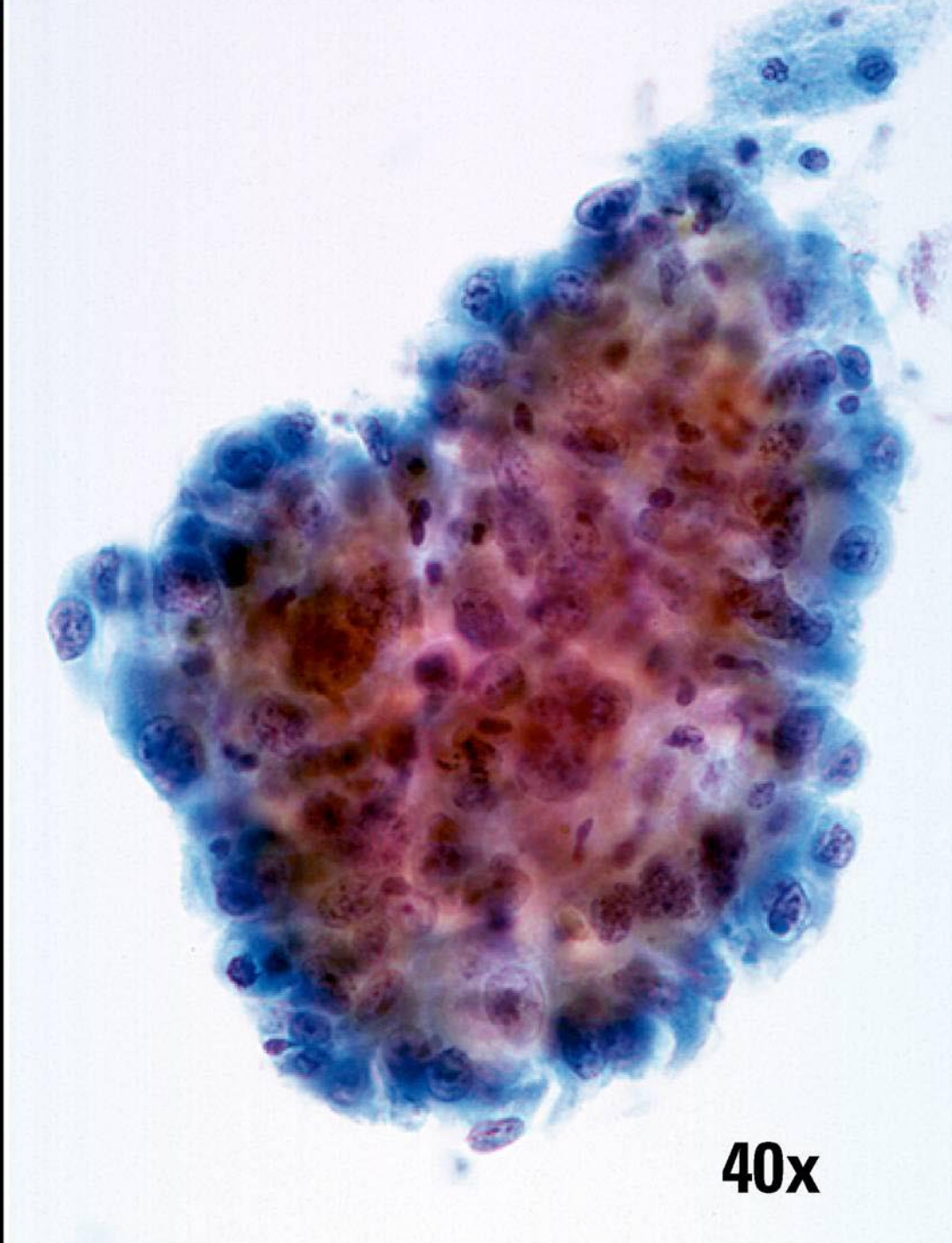
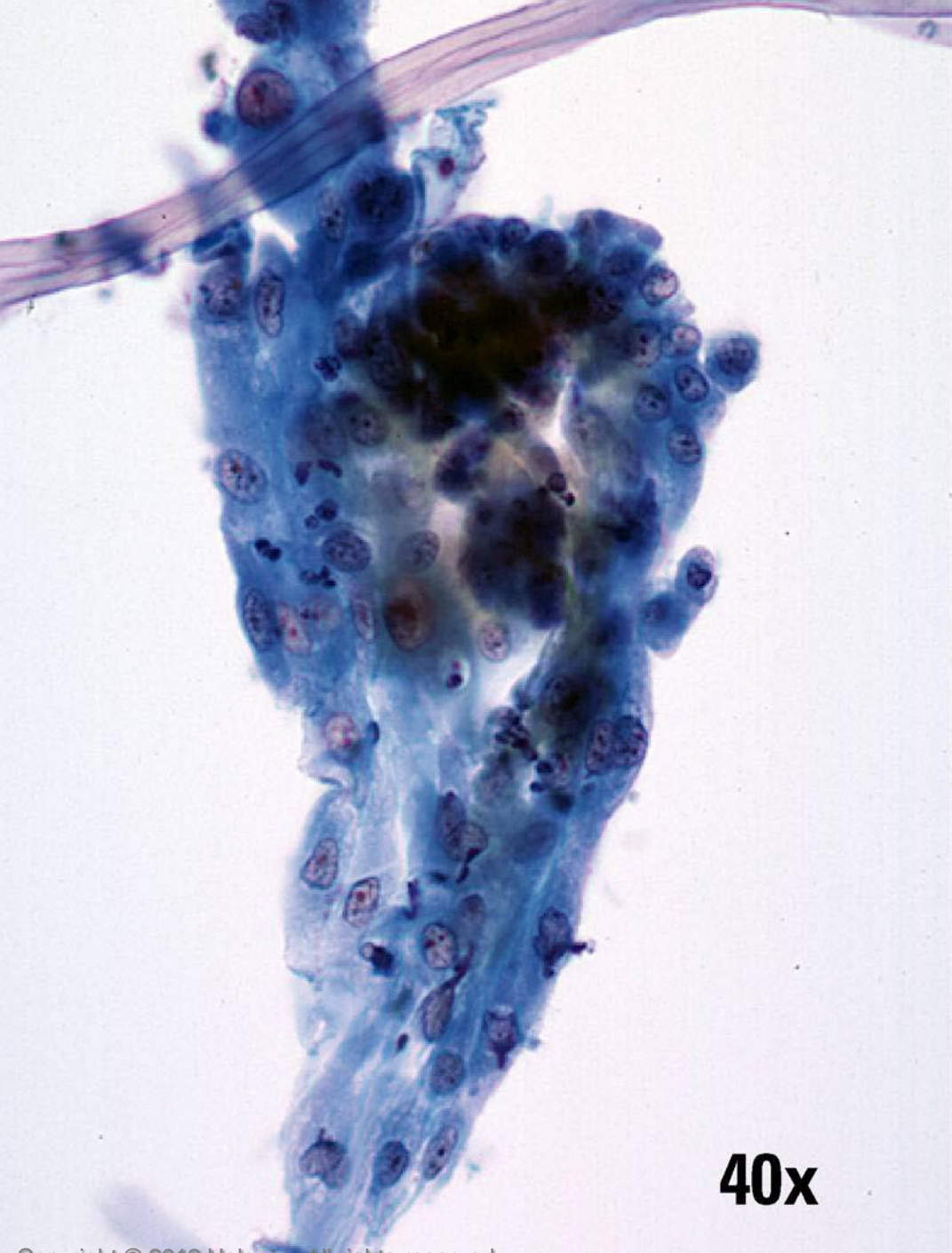
Repair vs. Poorly Differentiated SCC

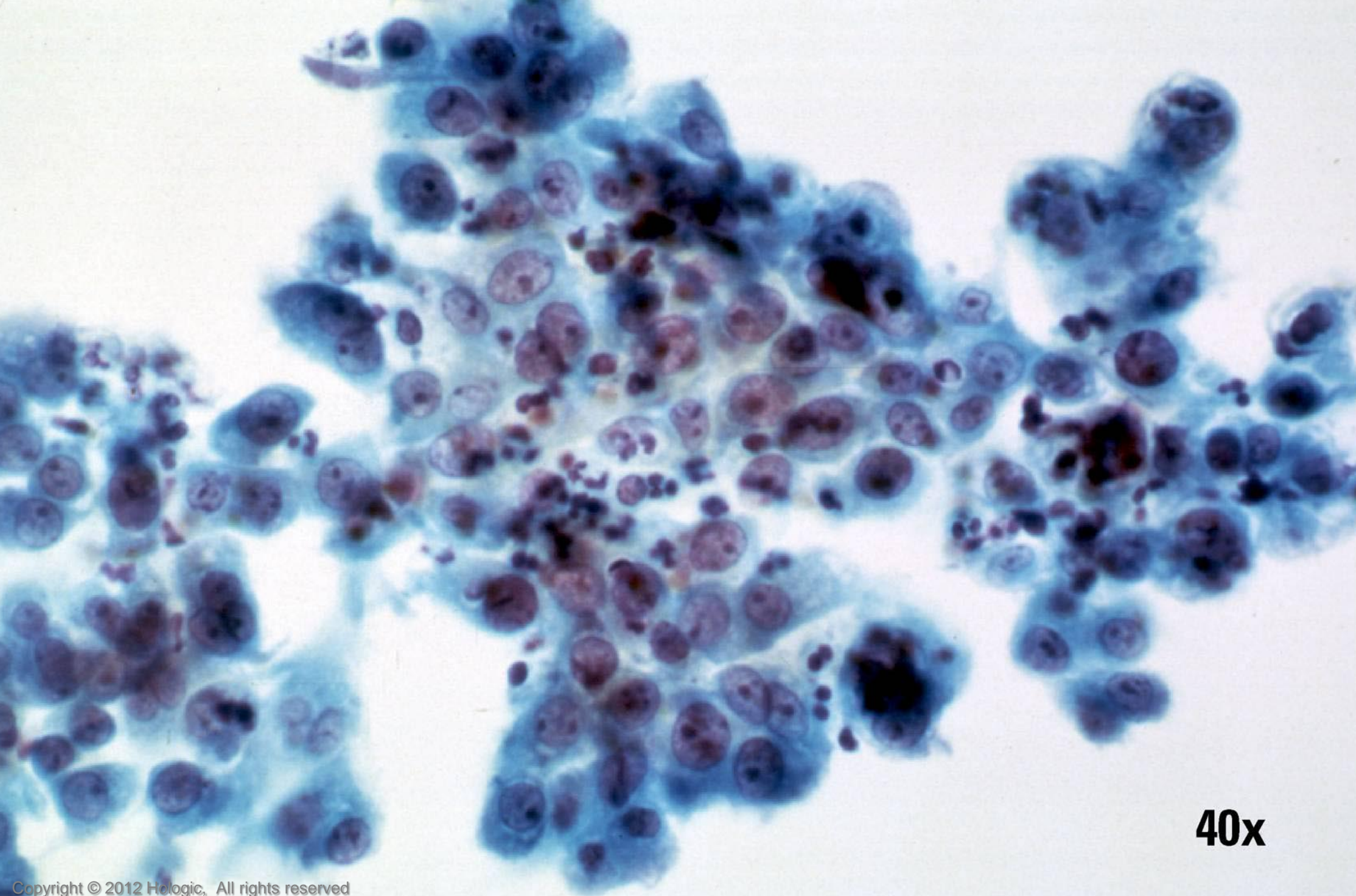
Repair (typical)

- Cohesive sheets
- Significant nuclear size variation but typically round/oval in shape
- Thin, well defined nuclear membranes
- More open chromatin pattern with minimal variability
- Centrally located macronucleoli with smooth, round contours
- Virtually all nuclei display nucleoli

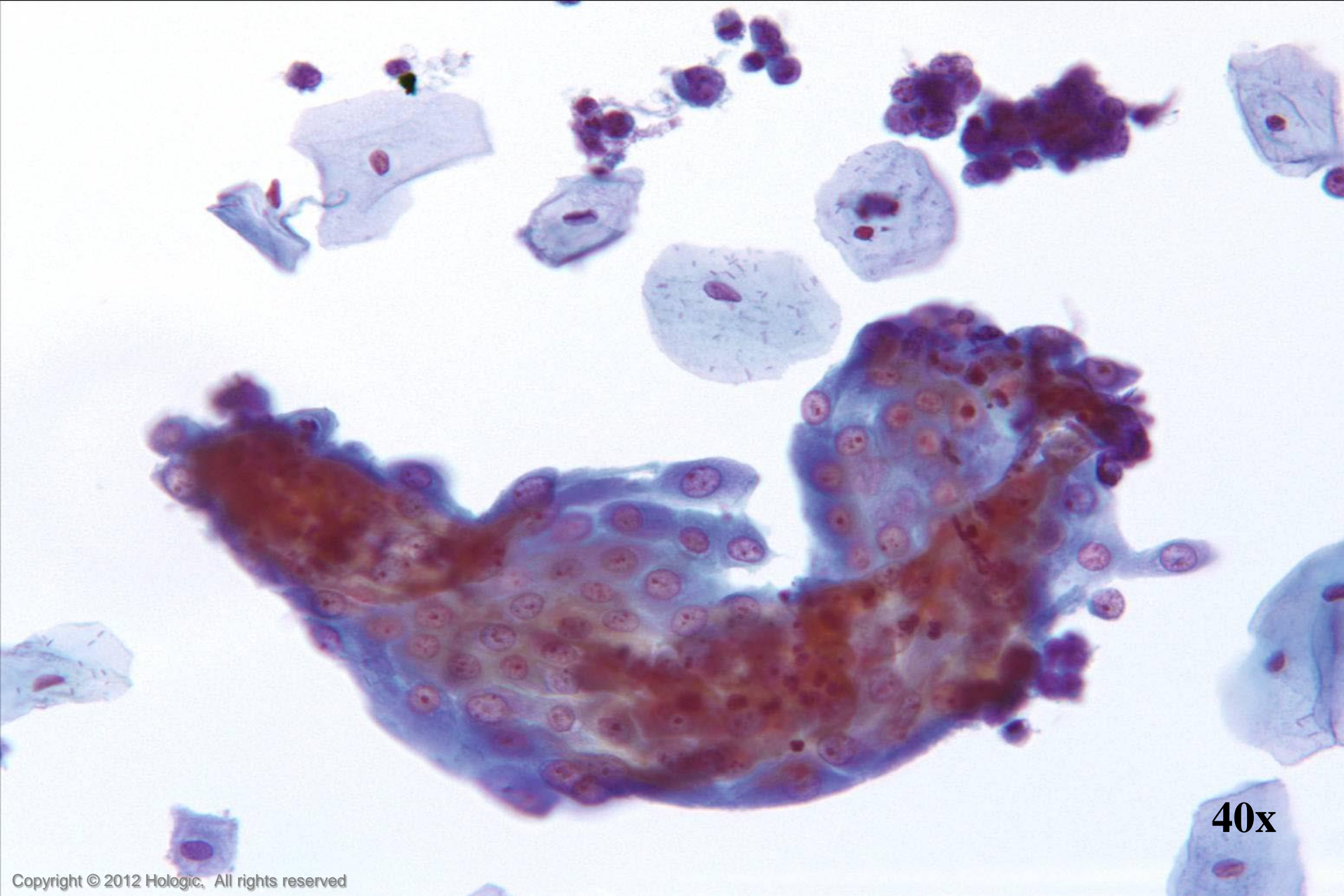
Poorly Differentiated SCC

- Poorly cohesive sheets and single cells
- Irregular nuclear shapes & sizes
- Thickened nuclear membranes
- Irregular chromatin clumping
- Nucleoli variable in shape, size, number and position
- Some nuclei display nucleoli, some nuclei do not

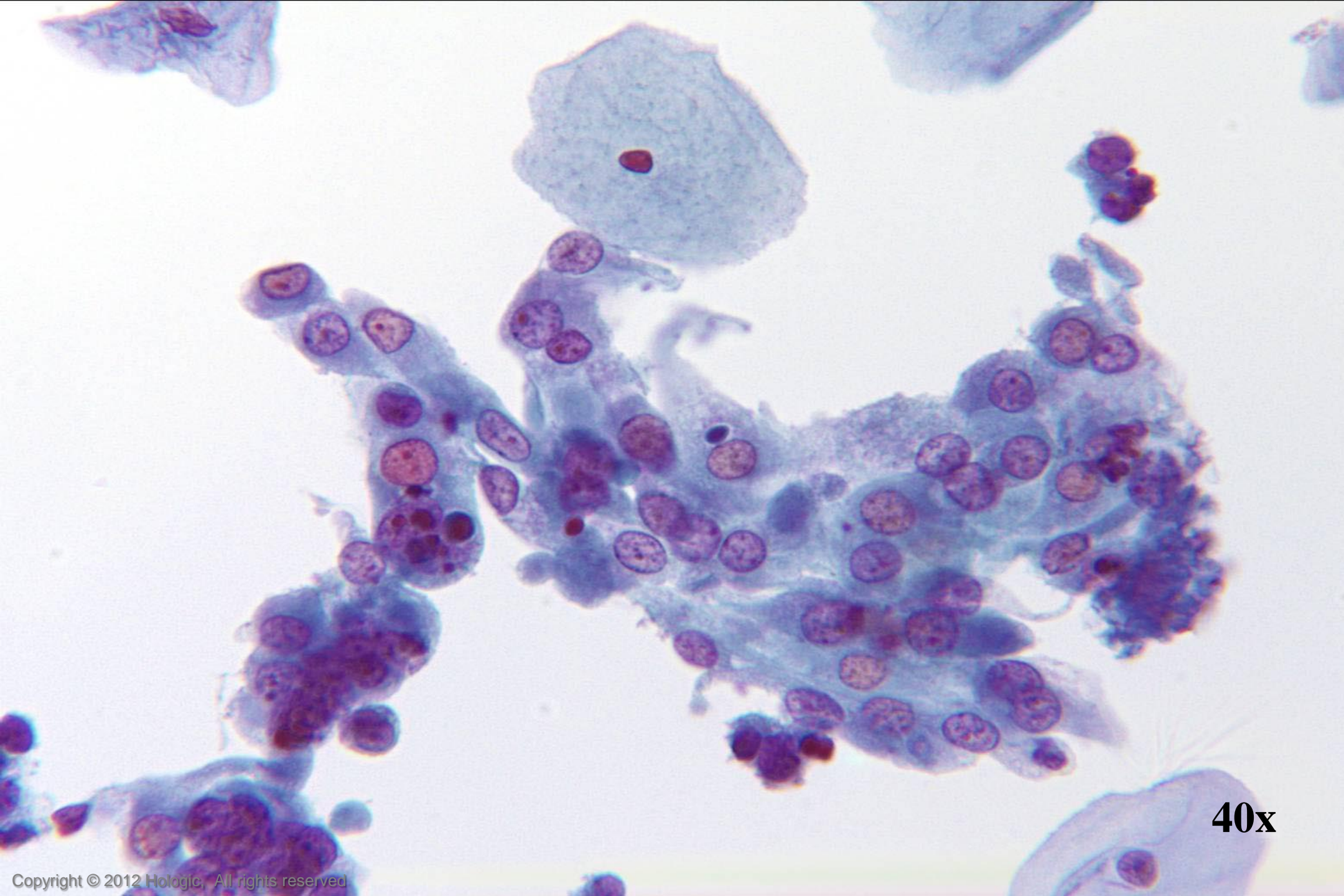




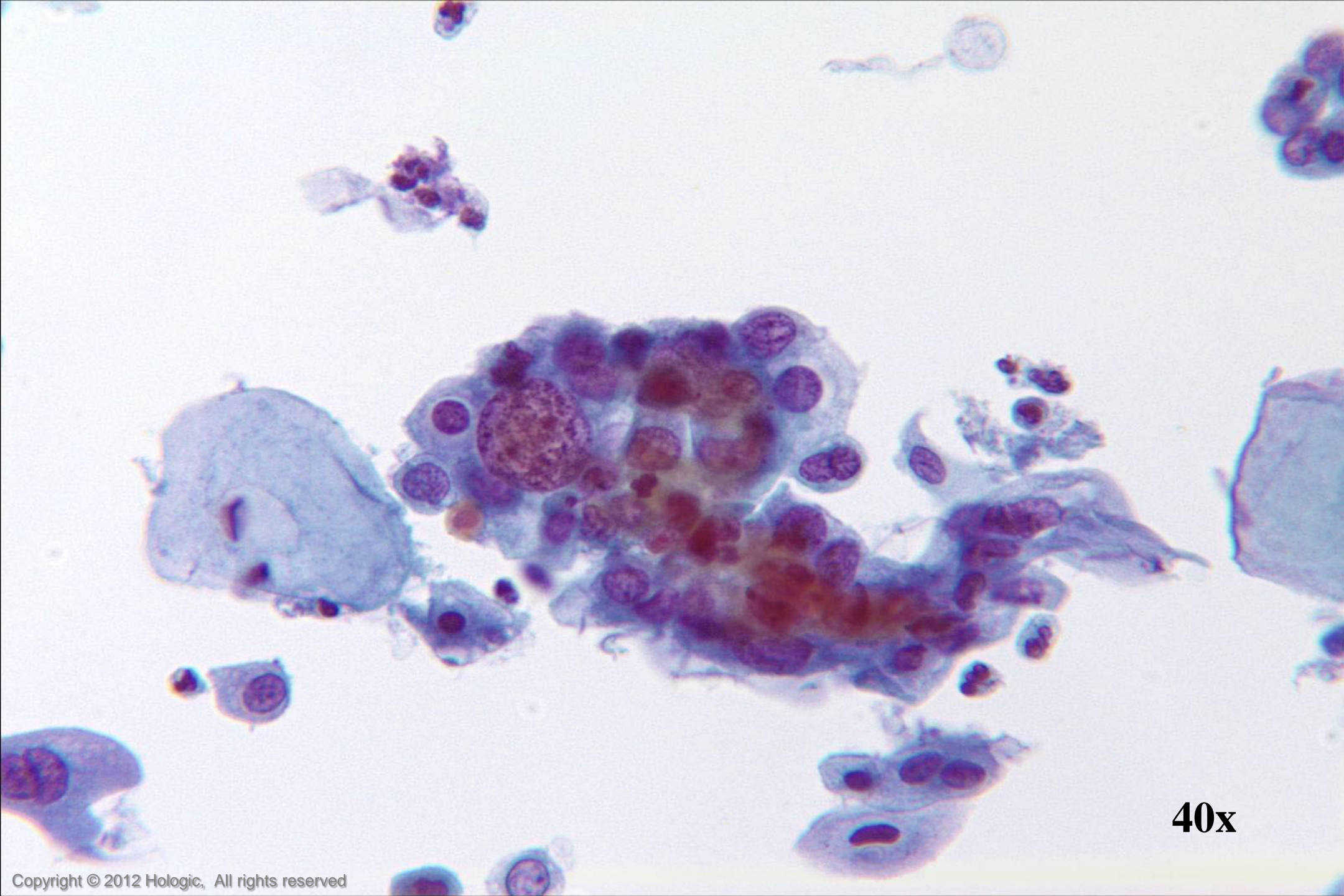
40x



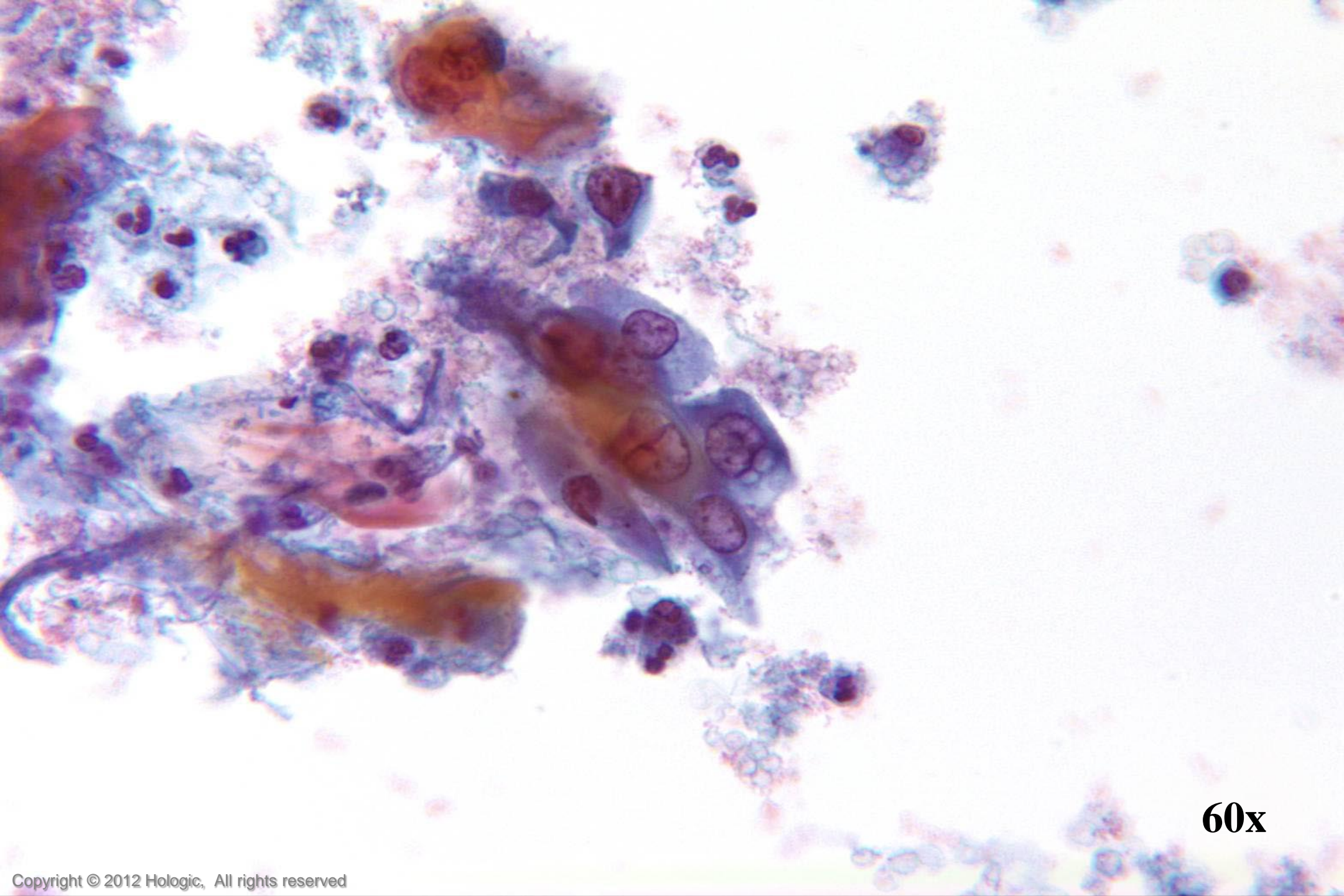
40x



40x



40x



60x

Trademark Statement

CytoLyt, Hologic, PreservCyt, ThinPrep, and UroCyte are registered trademarks of Hologic, Inc. and/or its subsidiaries in the United States. CytoLyt, Hologic, PreservCyt, ThinPrep, UroCyte and associated logos are trademarks of Hologic, Inc. and/or its subsidiaries in other countries.

All other trademarks are the property of their respective owners.

Any Questions?