



ThinPrep[®] Non-Gyn Lecture Series

Respiratory Cytology

Benefits of ThinPrep[®] Technology

Benefits of ThinPrep Non-Gyn for Respiratory (Muroid) specimens:

- Control cellular density
- Eliminate preparation artifact
- Minimize number of slides per patient
- Eliminate muroid glycoprotein



Required Materials

- ThinPrep[®] 2000 Processor or ThinPrep 5000 Processor
- ThinPrep Microscope Slides
- ThinPrep Non-Gyn Filters (Blue)
- Multi-Mix[™] Racked Vortexor
- CytoLyt[®] and PreservCyt[®] Solutions



Required Materials

- 50 ml capacity swing arm centrifuge
- 50 ml centrifuge tubes
- Slide staining system and reagents
- 1 ml plastic transfer pipettes
- 95% alcohol
- Coverslips and mounting media



Optional: Glacial acetic acid, DTT and saline for troubleshooting

Recommended Collection Media

- CytoLyt[®]
- Plasma-Lyte[®]
- Polysol[®]
- Balanced electrolyte solutions



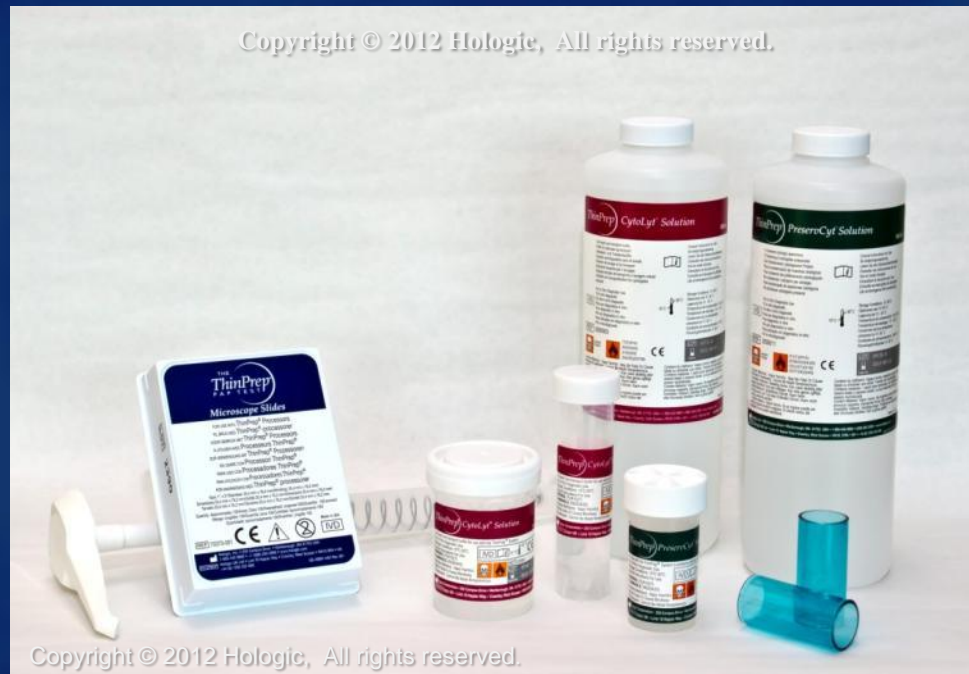Non-Recommended Collection Media

- Sacomanno and other solutions containing carbowax
- Alcohol
- Mucollexx[®]
- Culture Media, RPMI Solution
- PBS
- Solutions containing formalin



Hologic[®] Solutions

- CytoLyt[®]
- PreservCyt[®]



Hologic[®] Solutions

CytoLyt[®] Solution

- Methanol-based, buffered preservative solution
 - Lyses red blood cells
 - Prevents protein precipitation
 - Dissolves mucus
 - Preserves morphology for **8 days** at room temperature
- Intended as transport medium
- Used in specimen preparation prior to processing



Hologic[®] Solutions

PreservCyt[®] Solution

- Methanol based, buffered solution
- Specimens must be added to PreservCyt Solution prior to processing
- PreservCyt Solution cannot be substituted with any other reagents
- Cells in PreservCyt Solution are preserved for up to **3 weeks** in a temperature range between 4 -37 C



Specimen Types

- Sputum
- Bronchial Brushing
- Bronchial Washing
- Bronchoalveolar Lavage
- Fine Needle Aspiration (FNA) Biopsy, Transbronchial FNA, Endobronchial Ultrasound (EBUS) FNA



Sputum

- Easily obtained if spontaneous
- 3 to 5 consecutive day, early morning, deep cough specimens preferred
- Can be induced if not spontaneous by inhalation of an aerosolized solution
- Good for detection of central tumor



Bronchial Brushing

- Collected with a small brush under visual control using a fiberoptic bronchoscopic instrument
- Good for detection of peripheral tumors



Bronchial Washing

- Collected by instilling 3 to 5 mL of balanced salt solution through the bronchoscope and re-aspirating the resulting material
- Good for detection of peripheral tumors



Bronchoalveolar Lavage (BAL)

- Collected by infusing and re-aspirating a sterile saline solution in the distal segments of the lung using a fiberoptic bronchoscope
- Utilized in the therapy of diseases such as pulmonary alveolar proteinosis, cystic fibrosis, pulmonary alveolar microlithiasism and asthma
- Good for detection of peripheral cancers as well as opportunistic infections in immunocompromised patients



Transbronchial FNA (TFNA)

- Transbronchial FNA is a special modification of needle aspiration used when the lung neoplasm has not invaded through the bronchial mucosa and is not accessible through sputum or bronchial brushing/washing
- An endobronchial aspirate may also be preformed under ultrasound guidance to reach these lesions, commonly referred to as Endobronchial Ultrasound (EBUS)
- Good for detection of lesions that are not visible during conventional bronchoscopy



Percutaneous FNA Biopsy

- A fine needle attached to a syringe is passed through the chest wall into the pulmonary mass visualized either by fluoroscopy, computed tomography, or ultrasound
- Good as an alternative to surgery for detection of pulmonary lesions that are not accessible during conventional bronchoscopy



Sample Collection

Mucoid Specimens

- Sputum: Collect directly into 30 ml CytoLyt[®] solution
- Bronchial Brushing: Deposit collection brush directly into a 30 ml prefilled CytoLyt solution tube
- Bronchial Washing/Lavage: Collect with a balanced electrolyte solution



Sample Collection

Fine Needle Aspirates

- Deposit and rinse the entire sample into a centrifuge tube containing 30 ml of CytoLyt[®] solution or a balanced electrolyte solution, such as Polysol[®] or Plasma-Lyte[®]



Sample Preparation

Mucoid Specimens

1. Sample Collection
Optional: If DTT is being used, add stock before agitation.
See next slide for stock preparation.
2. Mechanical agitation
3. Concentrate by centrifugation
4. Pour off supernatant and vortex to re-suspend cell pellet
5. Evaluate cell pellet
If cell pellet is not in liquid form do a CytoLyt[®] wash and repeat steps 2-4
6. Add recommended # of drops of specimen to PreservCyt[®] Solution Vial
7. Allow to stand for 15 minutes
8. Run on ThinPrep[®] 2000 using Sequence 3 or ThinPrep 5000 using Sequence Non-Gyn
9. Fix, Stain, and Evaluate



Sample Preparation

DTT Protocol for Muroid Specimens

Preparing a DTT Stock Solution:

- Add 2.5g DTT to 30 ml of CytoLyt[®] Solution
- This solution is suitable for use for 1 week when stored at room temperature (15-30 C)
- Add 1 ml of stock solution to the sample prior to vortexing



Sample Preparation

DTT Protocol for Muroid Specimens

Preparing a DTT Single Use Solution:

- Add 0.08g DTT in individual 50 ml conical tubes. Place in freezer
- When ready for use, add 30 ml of CytoLyt[®] Solution and shake/vortex to dissolve
- Add specimen to DTT
- Vortex and continue processing protocol



Sample Preparation

Fine Needle Aspiration

1. Collection
2. Concentrate by centrifugation - 600g for 10 minutes
3. Pour off supernatant and vortex to re-suspend cell pellet
4. Evaluate cell pellet
 - If cell pellet is not free of blood, add 30 ml of CytoLyt[®] Solution to cell pellet and repeat from step 2
5. Add recommended # of drops of specimen to PreservCyt[®] Solution Vial
6. Allow to stand for 15 minutes
7. Run on ThinPrep[®] 2000 Processor using Sequence 3 or ThinPrep 5000 using Sequence Non-Gyn
8. Fix, Stain, and Evaluate



Sample Preparation Protocol Summary

- **ThinPrep[®] Non-Gyn Respiratory Protocol**
 - Sputum
 - Bronchial Washing
 - Bronchial Brushing
 - Bronchoalveolar Lavage
- **ThinPrep Non-Gyn FNA Protocol**
 - FNA, Transbronchial FNA, EBUS



Sample Preparation Techniques

- Mechanical Agitation
 - Mucoïd specimens require vigorous agitation in CytoLyt[®] solution to break up the mucus.
- Two recommended methods:
 - Vortex for 5 minutes
 - Blend for a few seconds

Note: Agitation times for both methods may vary depending on specimen consistency



Sample Preparation Techniques

- Centrifugation - 600g for 10 minutes or 1200g for 5 minutes
 - Concentrates the cellular material in order to separate the cellular components from the supernatant



Refer to Centrifuge Speed Chart in the ThinPrep[®] 2000 or ThinPrep 5000 Processor Manual, Non-Gynecologic section, to determine the correct speed for your centrifuge to obtain force of 600g or 1200g

Sample Preparation Techniques

- Pour off supernatant
 - Invert the centrifuge tube 180° in *one smooth movement*, pour off all supernatant and return tube to its original position

(Note: Failure to completely pour off the supernatant may result in a sparsely cellular sample due to dilution of the cell pellet).



Sample Preparation Techniques

- Vortex to re-suspend cell pellet
 - Randomizes the cell pellet and improves the results of the CytoLyt[®] solution washing procedure
 - Place the centrifuge tube onto a vortexor and agitate the cell pellet for 3 seconds or vortex manually by syringing the pellet back and forth with a plastic pipette



Sample Preparation Techniques

- CytoLyt[®] Solution Wash
 - Preserve cellular morphology while lysing red blood cells, dissolving mucus and reducing protein precipitation
 - Add 30 ml of CytoLyt Solution to a cell pellet, vortex for 5 minutes (*muroid specimens only*), concentrate by centrifugation, pour off the supernatant and vortex to resuspend the cell pellet



Sample Preparation Techniques

- Evaluate cell pellet
 - If cell pellet is white, pale pink, tan or not visible add specimen to PreservCyt[®] Solution vial (# of drops added is dependant on sample volume and will be discussed on future slides)
 - If cell pellet is distinctly red or brown indicating the presence of blood conduct a CytoLyt[®] wash



Sample Preparation Techniques

- Evaluate cell pellet
 - To test for liquid form, draw a small amount of sample into a pipette and deliver drops back into the tube.
 - If the drops appear stringy or gelatinous, the mucus must be further liquefied.



Sample Preparation Techniques

- Calculate how many drops of specimen to add to PreservCyt[®] vial:
 - If pellet is clearly visible and the pellet volume is ≤ 1 ml (if not consider the next 2 slides)
- Vortex pellet and transfer 2 drops to a fresh PreservCyt Solution vial



Sample Preparation Techniques

- Calculate how many drops of specimen to add to PreservCyt[®] vial:
 - If pellet volume is ≥ 1 ml
 - Add 1 ml of CytoLyt[®] Solution into the tube and vortex briefly to resuspend the cell pellet
 - Transfer 1 drop of the specimen to a fresh PreservCyt Solution vial



Sample Preparation Techniques

- Calculate how many drops of specimen to add to PreservCyt[®] vial:
 - If pellet is not visible or scant
 - Add contents of a fresh PreservCyt Solution vial into the tube and vortex briefly to mix the solution
 - Pour entire sample back into the vial



Sample Preparation Troubleshooting

- Due to the biological variability among samples and variability in collection methods, standard processing may yield a slide that indicates further troubleshooting may be needed.



Sample Preparation Troubleshooting

- After staining, you may observe the following irregularities:
 - Non-uniform distribution of cells in the cell spot *without* a “sample is dilute” message
 - Uneven distribution in the form of a ring or halo of cellular material and/or white blood cells
 - A sparse cell spot lacking in cellular component and containing blood, protein and debris – may be accompanied by a “sample is dilute” message



Techniques Used in Troubleshooting

- Diluting the Sample 20 to 1
- Glacial Acetic Acid Wash for Blood and Non-Cellular Debris
- Saline Wash for Protein



Techniques Used in Troubleshooting

- Diluting the Sample 20 to 1
 - Add 1ml of the sample that is suspended in PreservCyt[®] Solution to a new PreservCyt Solution vial (20ml). This is most accurately done with a calibrated pipette.



Techniques Used in Troubleshooting

- Glacial Acetic Acid Wash for Blood and Non-Cellular Debris
 - If sample is bloody, it can be further washed using a solution of 9 parts CytoLyt[®] Solution and 1 part Glacial Acetic acid.



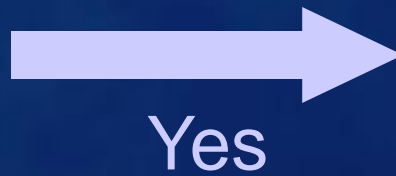
Techniques Used in Troubleshooting

- Saline Wash for Protein
 - If sample contains protein, it can be further washed with saline solution in place of CytoLyt[®] Solution.



Troubleshooting Muroid Specimens

“Sample is Dilute”
message

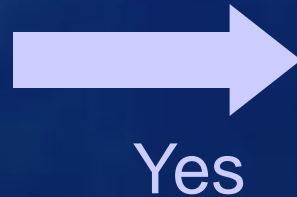


Check to see if cellularity is adequate. If not, use more of the pellet, if available and prepare new slide.



Troubleshooting Mucoïd Specimens

Does the slide have a
“halo” of cellular
material and/or white
blood cells?



Dilute the sample
20:1 by adding 1ml of
sample to a new
PreservCyt® Solution
vial. Prepare new
slide.



No, continue to next
slide

*If halo is present on
the new slide, contact
Hologic® Technical
Service.*

Troubleshooting Muroid Specimens

Is the slide sparse and
does it contain
mucus?



No

*Contact Hologic®
Technical Service*

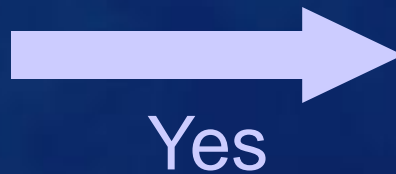
Yes

Centrifuge remaining specimen from PreservCyt® vial, pour off and vortex. Perform CytoLyt® wash and evaluate cell pellet appearance. If pellet contains mucus repeat CytoLyt wash. Add to PreservCyt vial and prepare new slide.

If resulting slide is sparse, contact Hologic Technical Service.

Troubleshooting Bloody or Proteinaceous Specimens

“Sample is Dilute”
message




Check to see if cellularity is adequate. If not, use more of the pellet, if available and prepare new slide.



NO, continue to
next slide

Troubleshooting Bloody or Proteinaceous Specimens

Does the slide have a
“halo” of cellular
material and/or white
blood cells?



Yes

Dilute the sample 20:1
by adding 1ml of
residual sample to a
new PreservCyt[®]
Solution vial and
prepare new slide.

*If halo is present on the
new slide, contact Hologic[®]
Technical Service.*



No, continue to next
slide



Troubleshooting Bloody or Proteinaceous Specimens

Is the slide sparse and does it contain blood, protein or non-cellular debris?



No

Contact Hologic[®]
Technical Service



Yes-blood
or non-
cellular
debris

Centrifuge remaining specimen from PreservCyt[®] vial, pour off. Add 30ml of a 9:1 CytoLyt[®] to glacial acetic acid solution to the sample, centrifuge, pour off and vortex. Add to PreservCyt vial and prepare new slide. *If the resulting slide is sparse, contact Hologic Technical Service.*



Yes-protein

Centrifuge remaining specimen from PreservCyt vial, pour off. Add 30 ml of saline to sample, centrifuge, pour off and vortex. Add to PreservCyt vial and prepare new slide. *If resulting slide is sparse, contact Hologic Technical Service.*

Troubleshooting Common Artifacts

- Smudged Nuclear Detail
- Compression Artifact
- Staining Artifact
- Edge of the Cylinder Artifact



Troubleshooting Common Artifacts

- Smudged Nuclear Detail
 - May occur if specimen is collected in saline, PBS or RPMI
 - To avoid this, collect the sample either fresh, in CytoLyt[®] or in PreservCyt[®] solution



Troubleshooting Common Artifacts

- Compression Artifact
 - Appears as “air dry” artifact on the perimeter of the cell spot
 - Due to the compression of cells between the edge of the filter and the glass of the slide



Troubleshooting Common Artifacts

- Staining Artifact
 - Mimics air-drying
 - Appears as a red or orange central staining primarily in cell clusters or groups
 - Due to the incomplete rinsing of counterstains.
 - To eliminate this artifact, fresh alcohol baths or an additional rinse step after the cytoplasmic stains is required



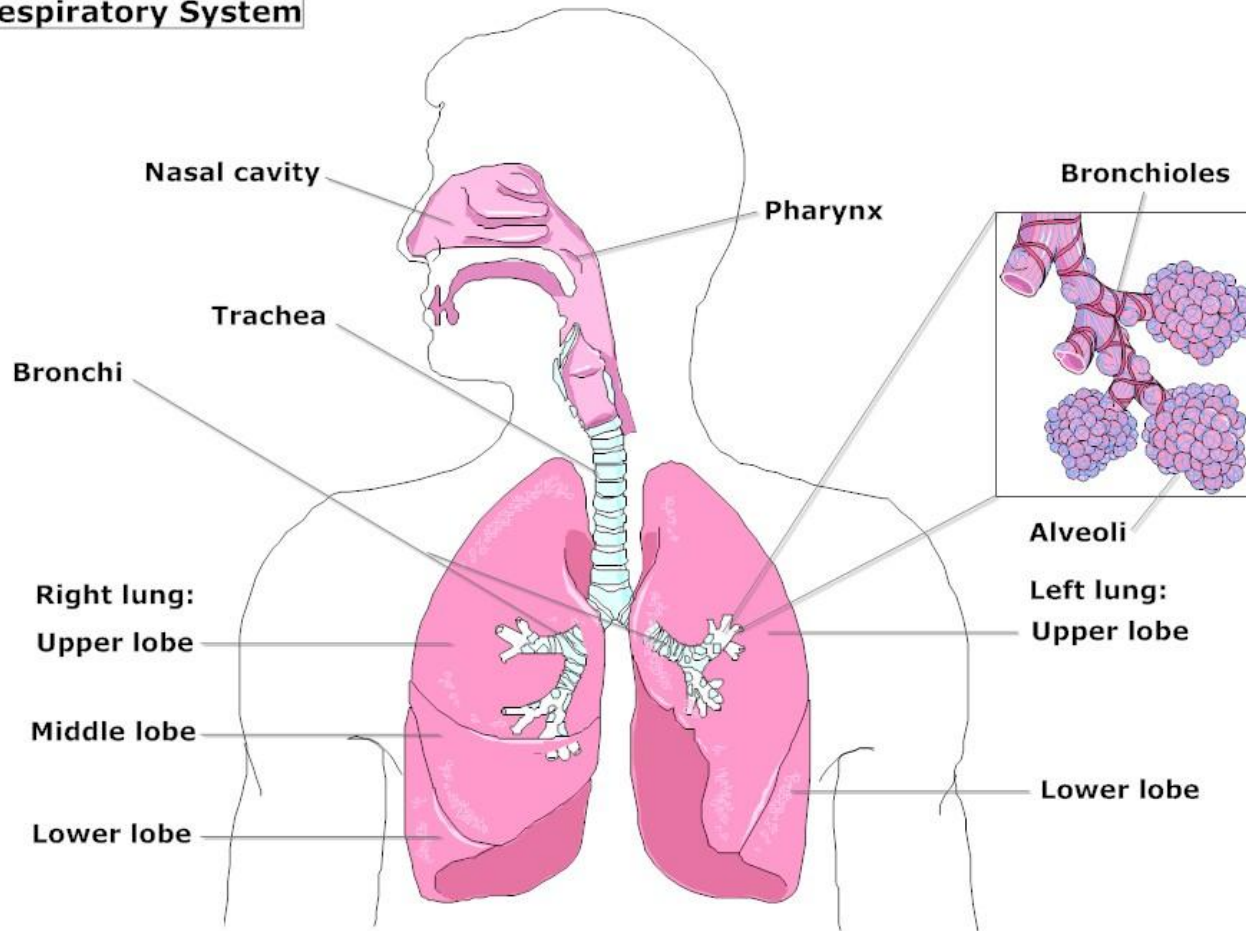
Troubleshooting Common Artifacts

- Edge of the Cylinder Artifact
 - Narrow rim of cellular material just beyond the circumference of the cell spot
 - Result of cells from the outer edge of the wet filter cylinder being transferred to the glass slide



Anatomy

Respiratory System

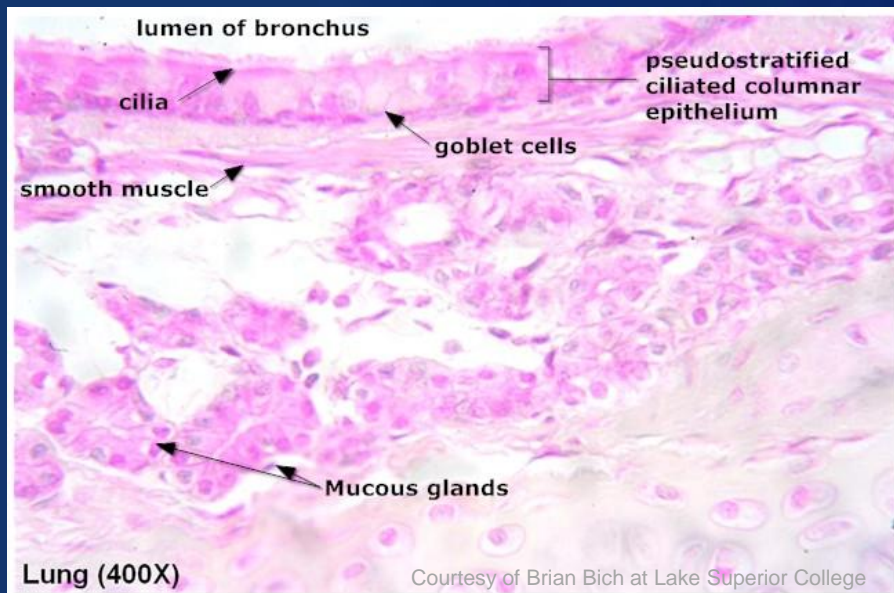


LifeART Collection Images Copyright © 1989-2001 by Lippincott Williams & Wilkins, Baltimore, MD

Histology of the Epithelium

Respiratory system is lined by two types of epithelium:

- Non-Cornified Stratified Squamous Epithelium
- Pseudostratified Ciliated Columnar Epithelium



Other Cell Types Include:

- Goblet cells
- Clara cells
- Kulchitsky cells
- Pneumocytes

Specimen Adequacy

- Sputum- presence of numerous alveolar macrophages
- Bronchial Brushing- presence of numerous bronchial cells
- BAL/Bronchial Washing- presence of bronchial cells and alveolar macrophages
- FNA- presence of diagnostic material



Normal Components and Findings

- Ciliated columnar epithelial cells

Nuclei:

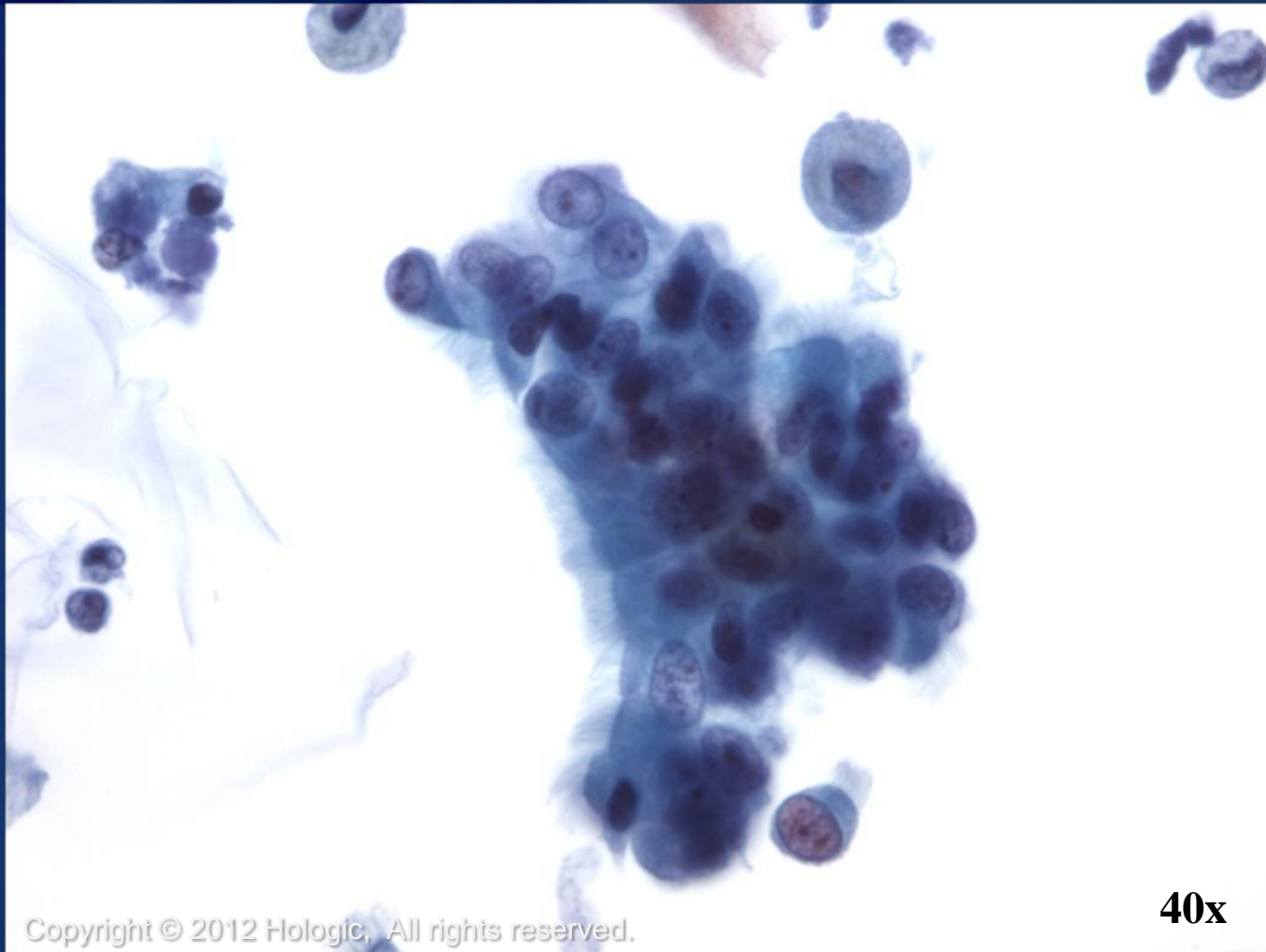
- Basally oriented
- Round to oval with smooth nuclear membranes
- May contain a nucleolus
- Fine to mildly coarse chromatin
- Variable in size

Cytoplasm:

- Homogenous and basophilic



Ciliated Columnar Epithelial Cells



ThinPrep[®]
Non-Gyn

Copyright © 2012 Hologic, All rights reserved.

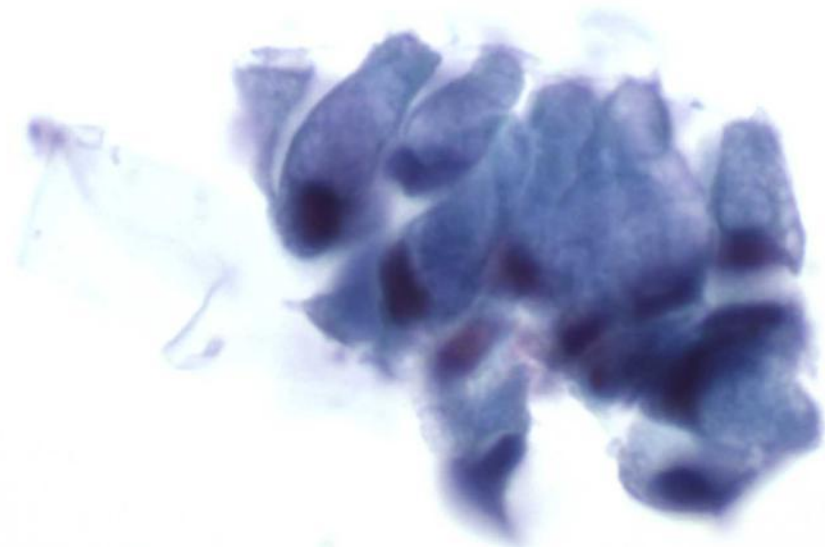
40x

Normal Components and Findings

- Goblet Cells
 - Commonly seen in bronchial washing and brushing specimens
 - Often in clusters or sheets
 - Usually one for every 5-10 ciliated epithelial cell
 - Abundant finely vacuolated cytoplasm filled with mucus



Goblet Cells



ThinPrep
Non-Gyn

Copyright © 2012 Hologic, All rights reserved.

60x

Hologic Proprietary © 2012

Normal Components and Findings

- Squamous cells
 - More common in sputum than in washings/brushings
 - Similar to those seen in Gyn samples
 - Predominantly superficial
 - Anucleated squames, intermediate cells and benign squamous pearls may also be present

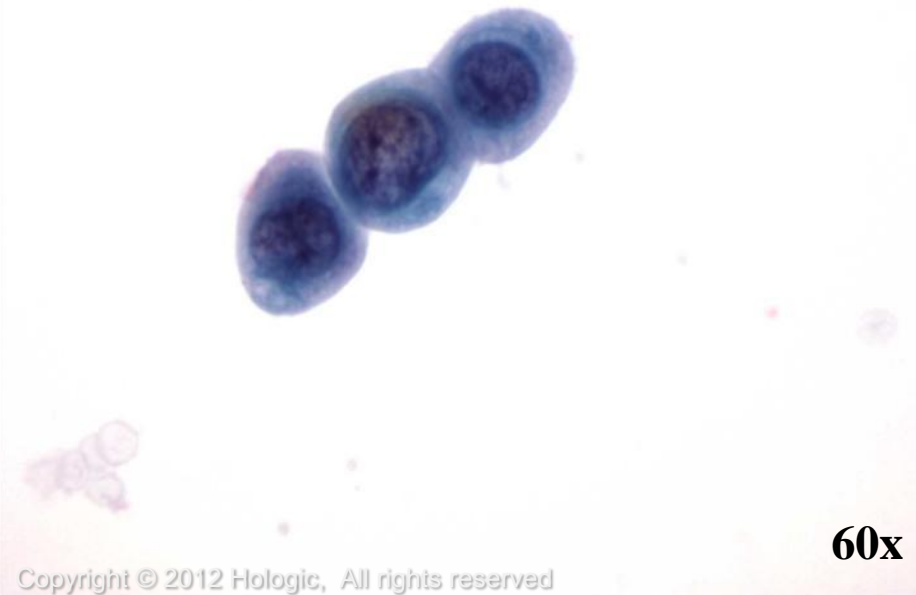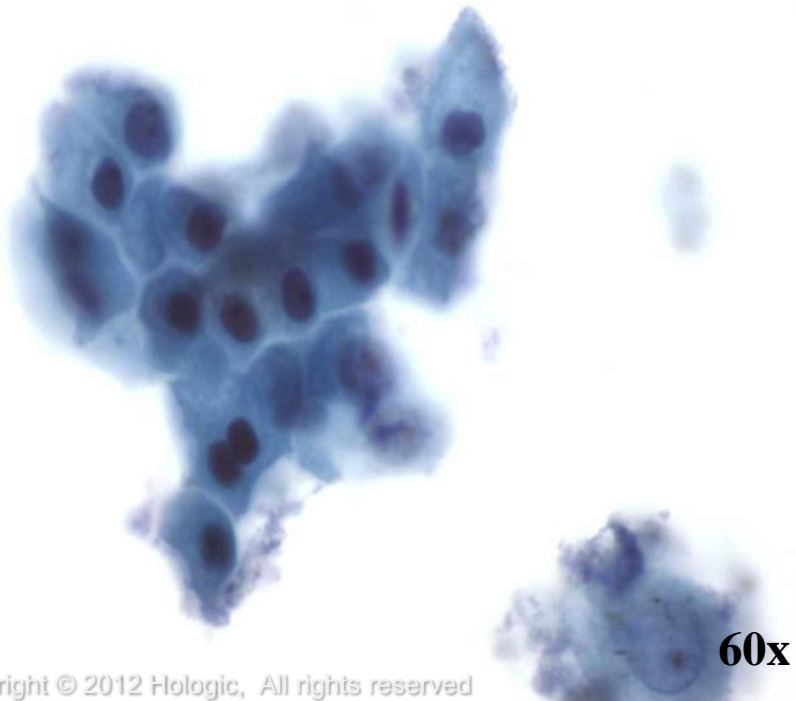


Normal Components and Findings

- Squamous Metaplasia
 - Similar to metaplasia seen in Gyn samples
 - Uniform in size and shape
 - Appear in loose sheets, in a cobblestone arrangement
 - Nuclei are round
 - Chromatin ranges from granular to coarse or pyknotic
 - No nucleoli, unless cells are reactive



Squamous Metaplasia



Normal Components and Findings

- Clara cells
 - Non-ciliated bronchiolar cells
 - Secrete a protein that acts as a clarificant, a function similar to mucus
- Kulchitsky cells
 - Scattered basal epithelial cells
 - Contain neurosecretory granules
 - Parent cells of carcinoid tumors

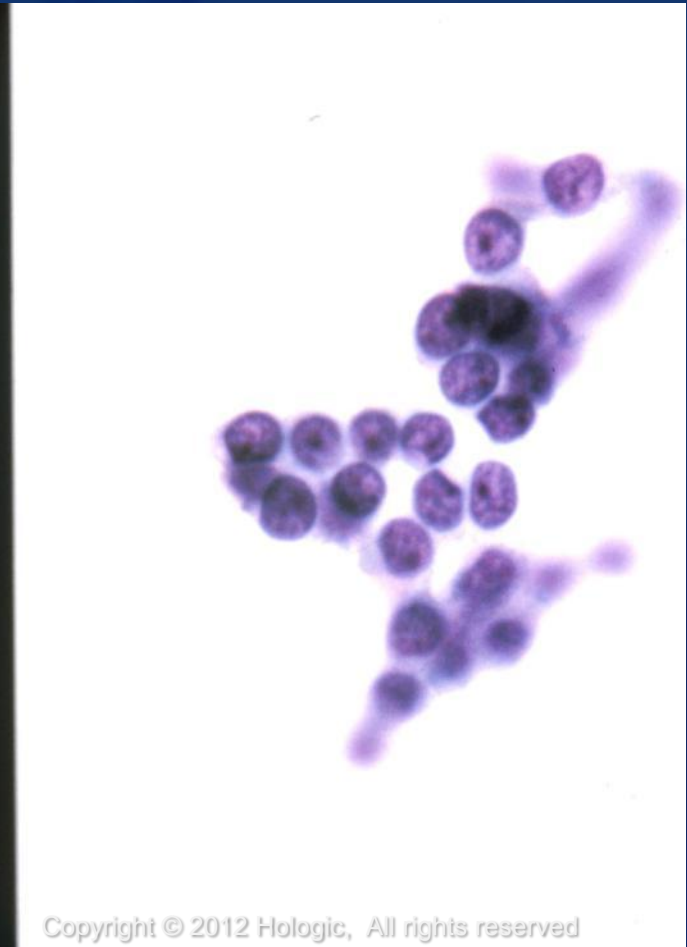
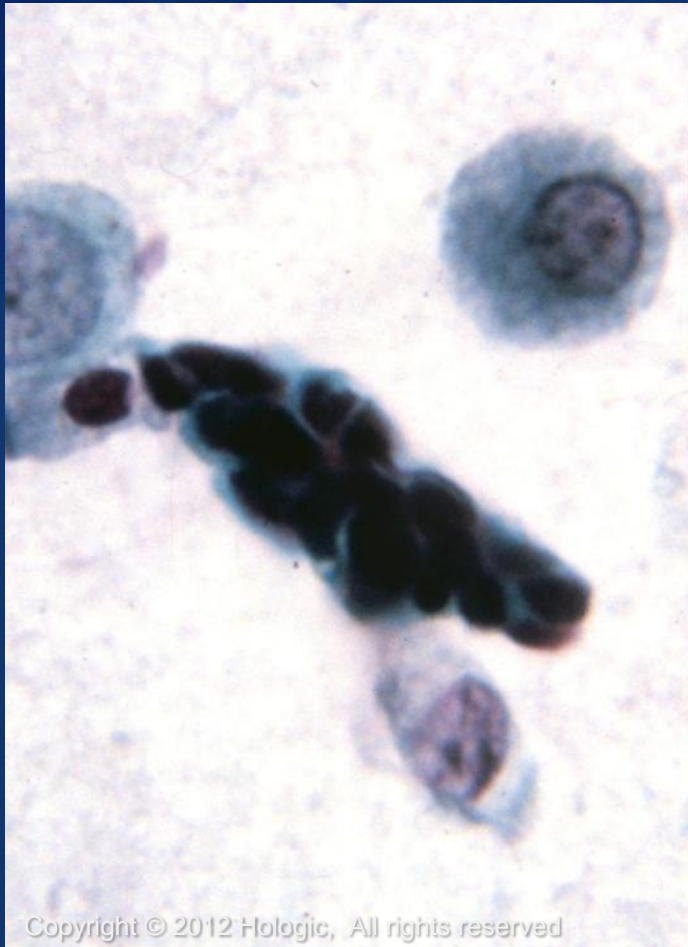

Normal Components and Findings

- Reserve cells
 - Small, round, lymphocyte-like cells
 - Nuclei are centrally located, uniform and hyperchromatic
 - Can only be specifically identified in clusters
- Pneumocytes
 - Type I Pneumocytes
 - Type II Pneumocytes: (Bronchoalveolar cells)



Reserve cells



ThinPrep[®]
Non-Gyn

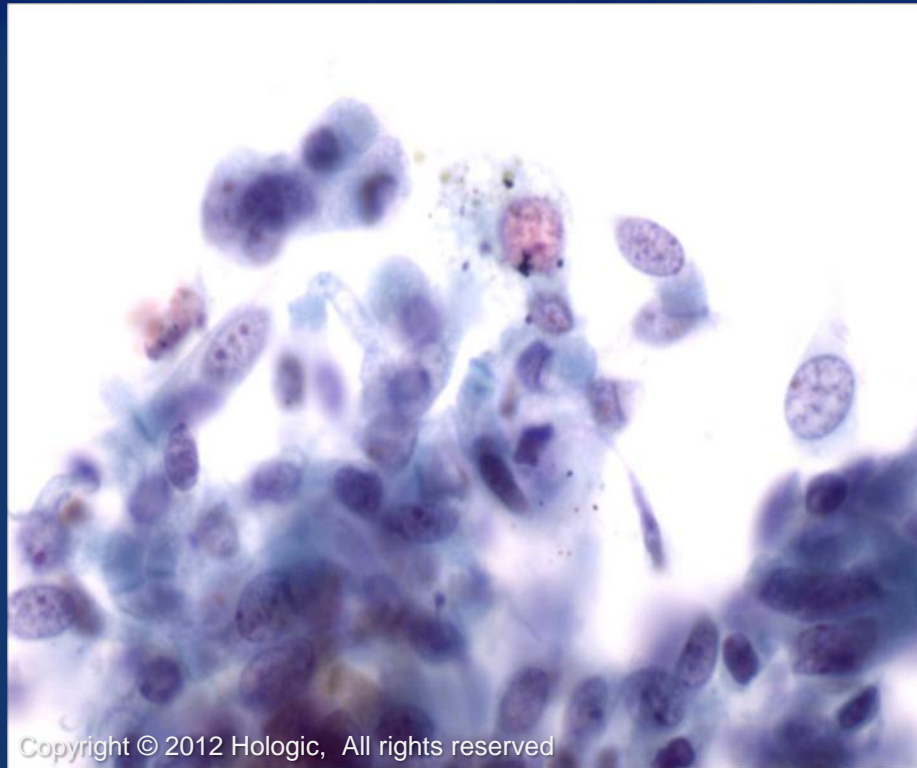
Normal Components and Findings

- Pulmonary macrophages
 - Cells may appear singly or in clusters
 - Nuclei may be round, oval, reniform or other shape
 - Multinucleation may be present
 - Cytoplasm is foamy and may be abundant
 - May contain ingested debris

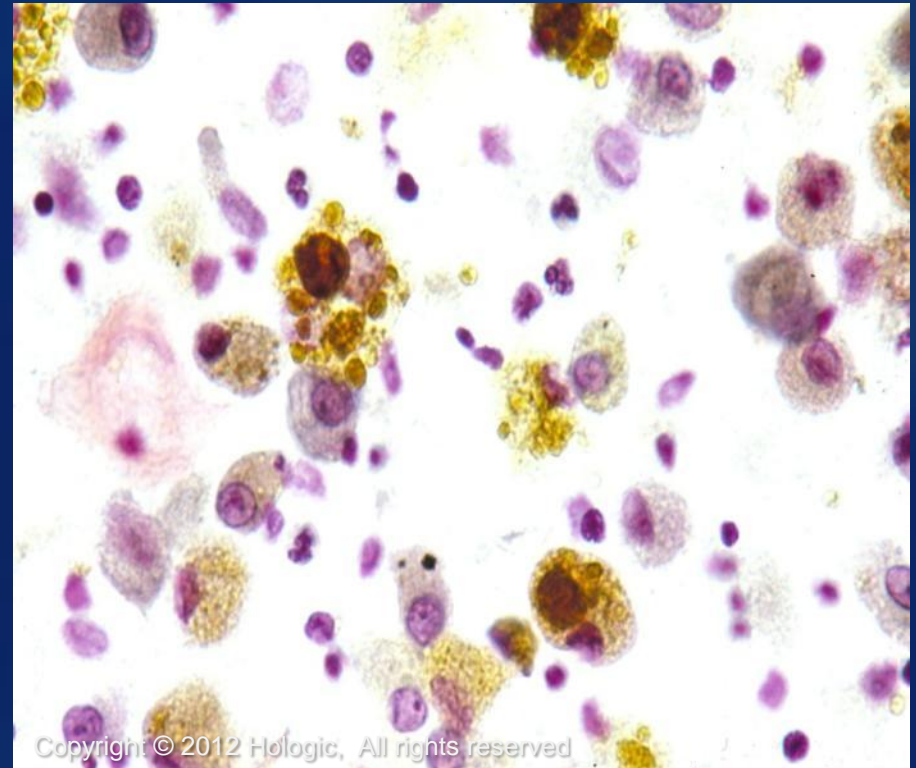


Macrophages

Carbon-laden

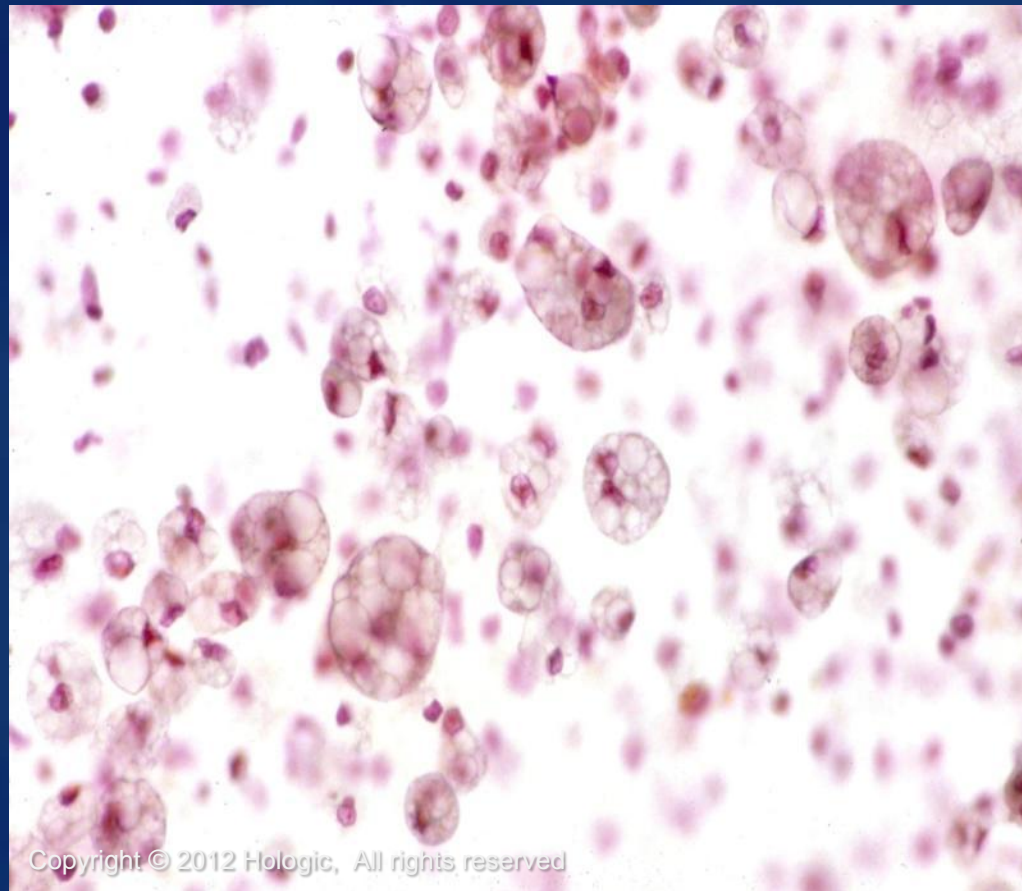


Hemosiderin-laden



Macrophages

Lipophages

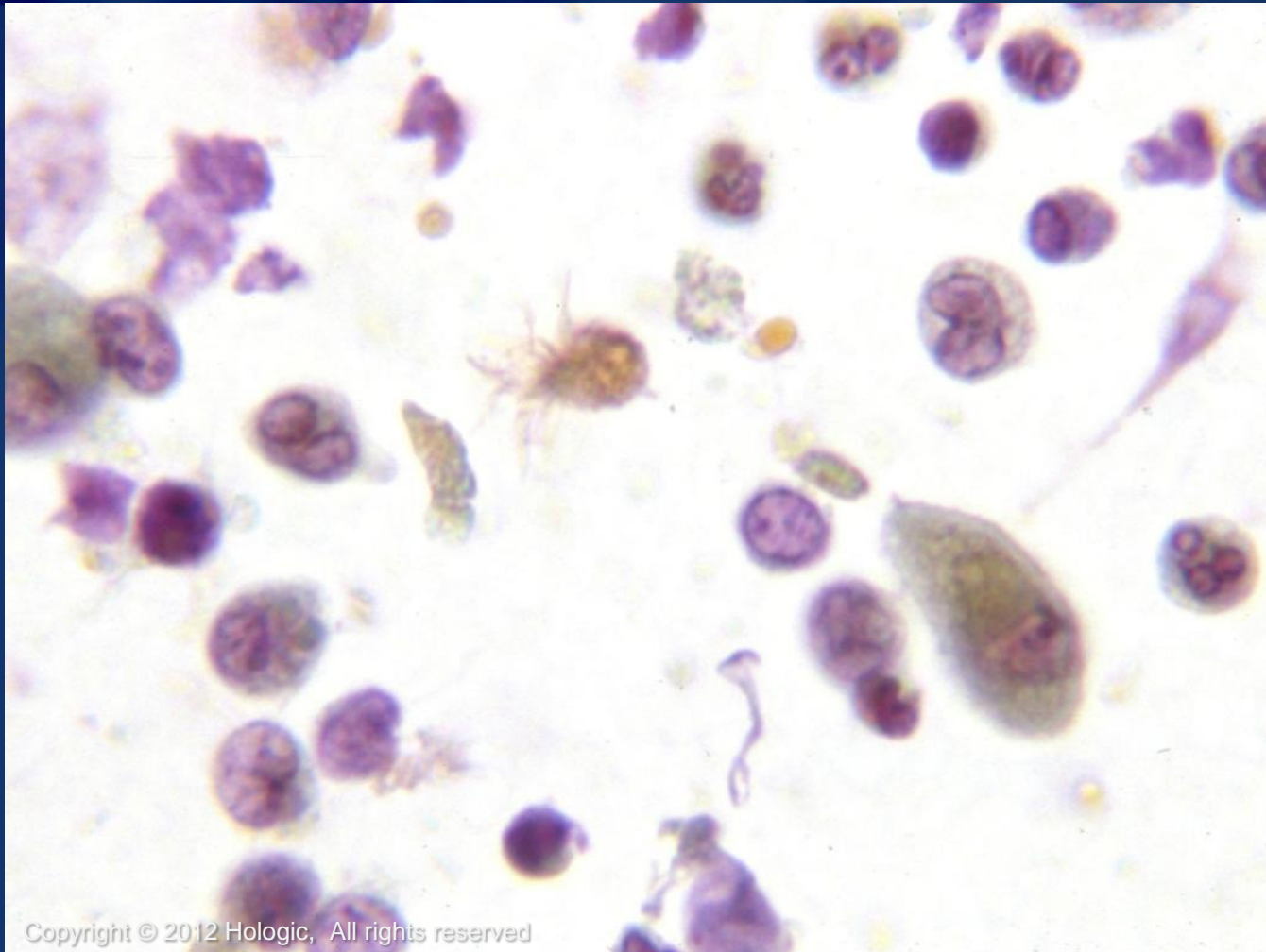


Normal Components and Findings

- Ciliocytophthoria
 - Small ciliated tufts
- Inflammatory cells
 - PMN's
 - Lymphocytes
 - Plasma cells
 - Eosinophils



Ciliocytophthoria



Copyright © 2012 Hologic, All rights reserved

ThinPrep
Non-Gyn

Hologic Proprietary © 2012

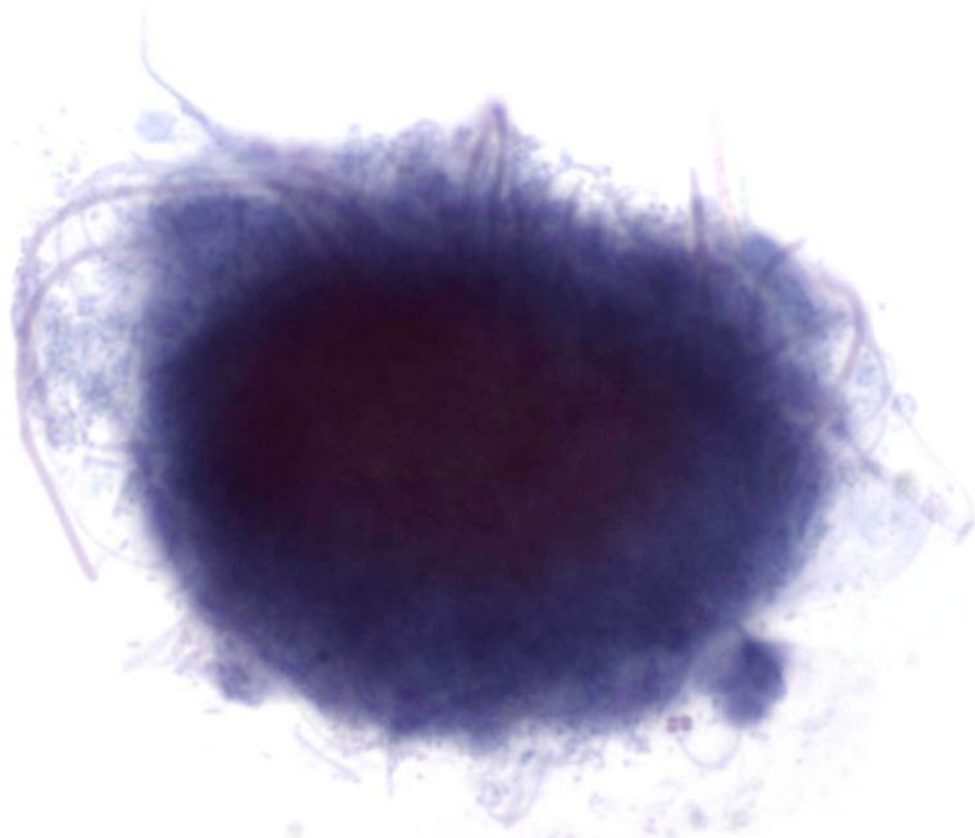
Normal Components and Findings

Infectious agents that may be seen:

- Bacteria/Fungus
 - Actinomyces
 - M. tuberculosis
 - Aspergillus spp.
 - Candida spp.
 - Pneumocystis carinii
 - Cryptococcus
 - Histoplasma
 - Blastomyces
 - Coccidioides
 - Zygomycetes



Actinomyces



Copyright © 2012 Hologic, All rights reserved

60x

ThinPrep[®]
Non-Gyn

Tuberculosis

- Caused by infection with *Mycobacterium tuberculosis* and commonly results in granulomatous inflammation

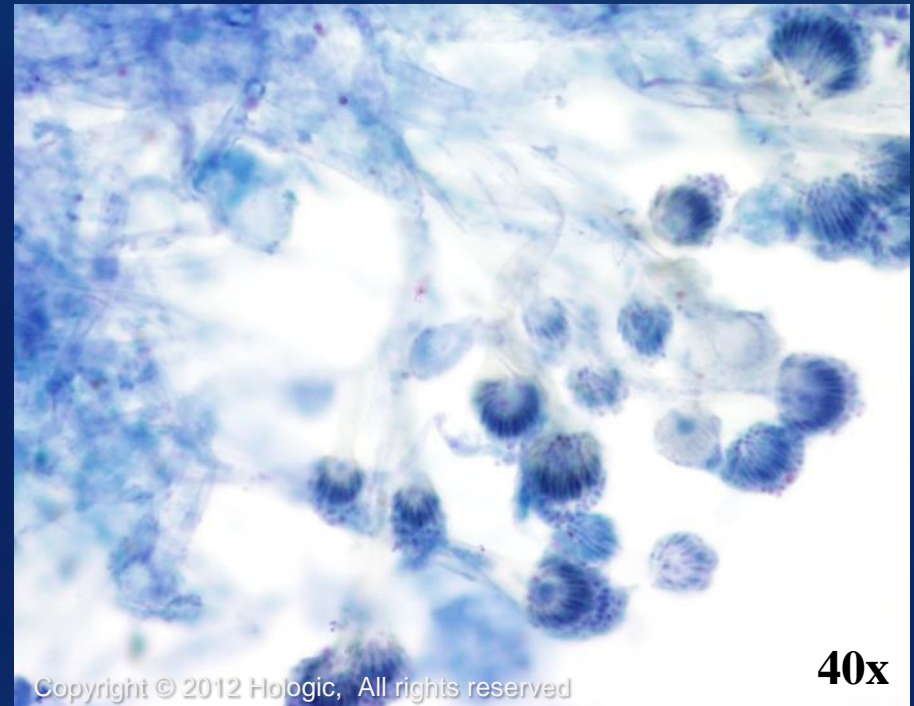
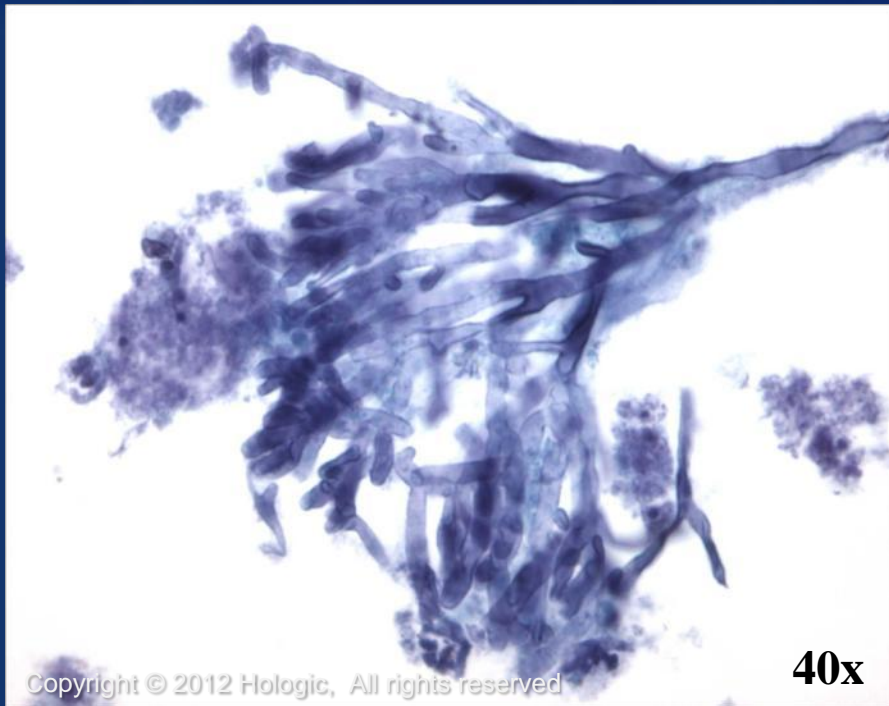Cytologic features:

- Aggregates of epithelioid histiocytes, lymphocytes, and Langhans giant cells

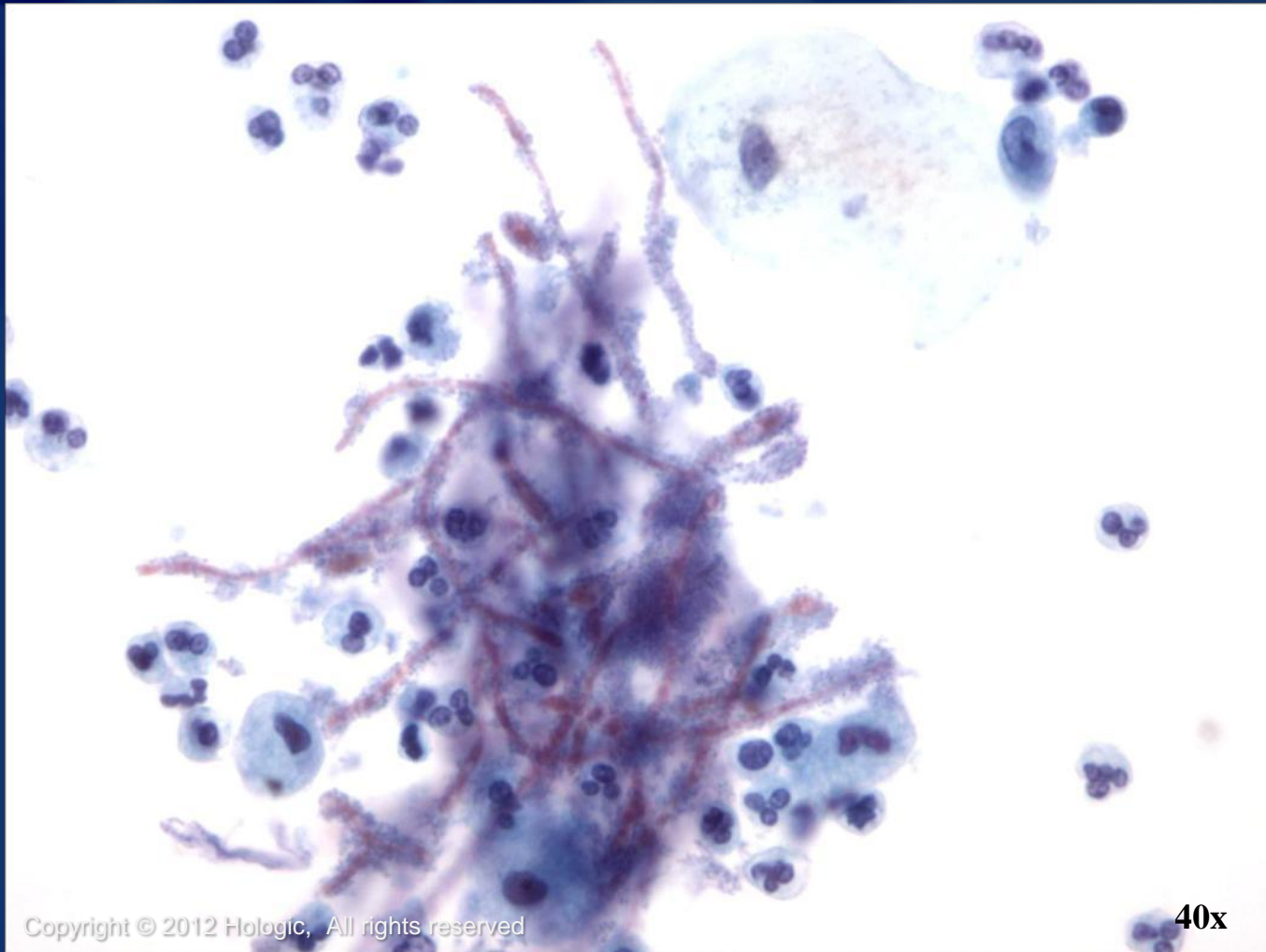
- Necrosis may or may not be present
- Definitive diagnosis can be made with help from special stains or microbiologic culture



Aspergillus spp.



Candida spp.

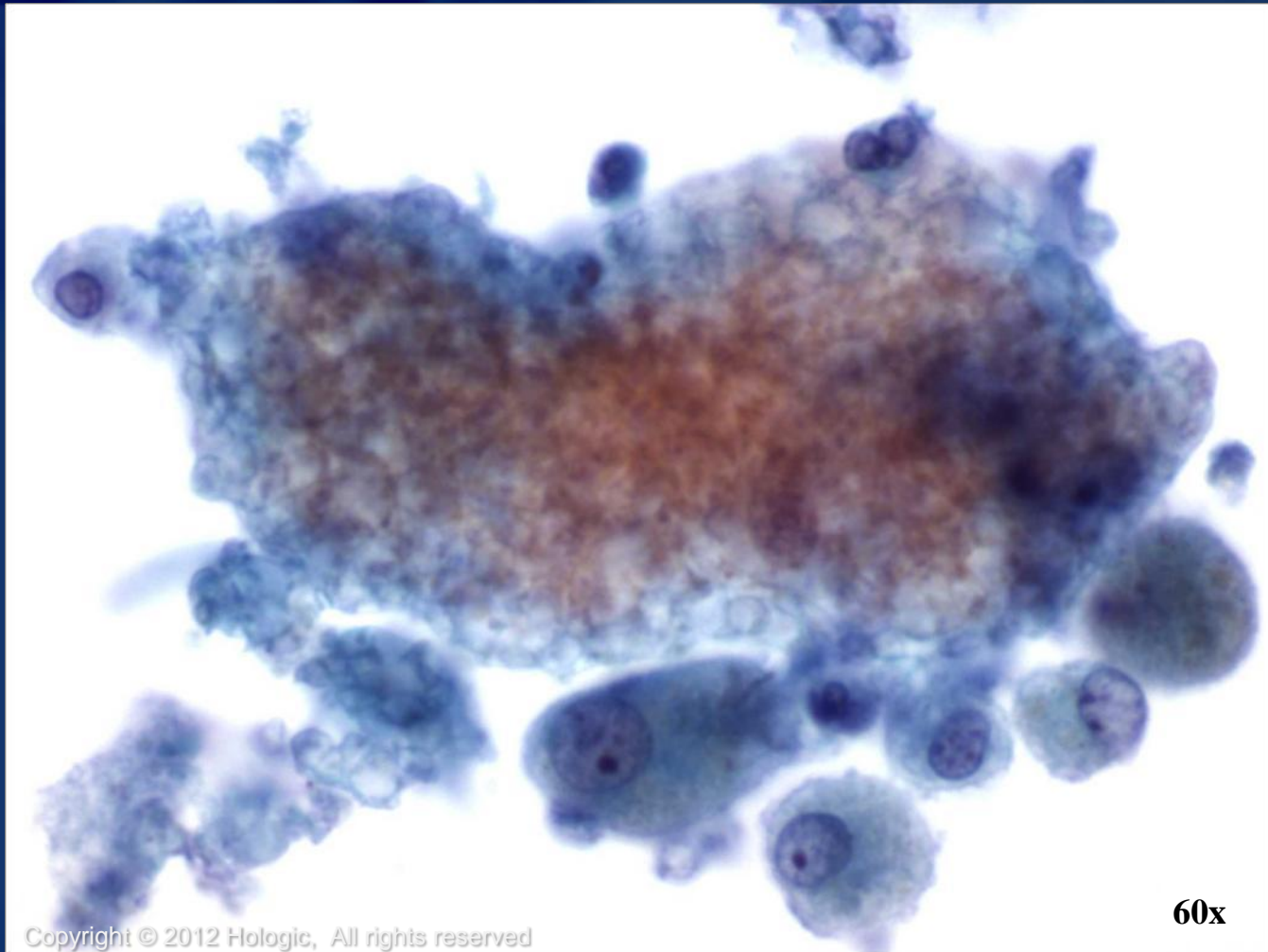


ThinPrep[®]
Non-Gyn

Copyright © 2012 Hologic, All rights reserved

40x

Pneumocystis carinii

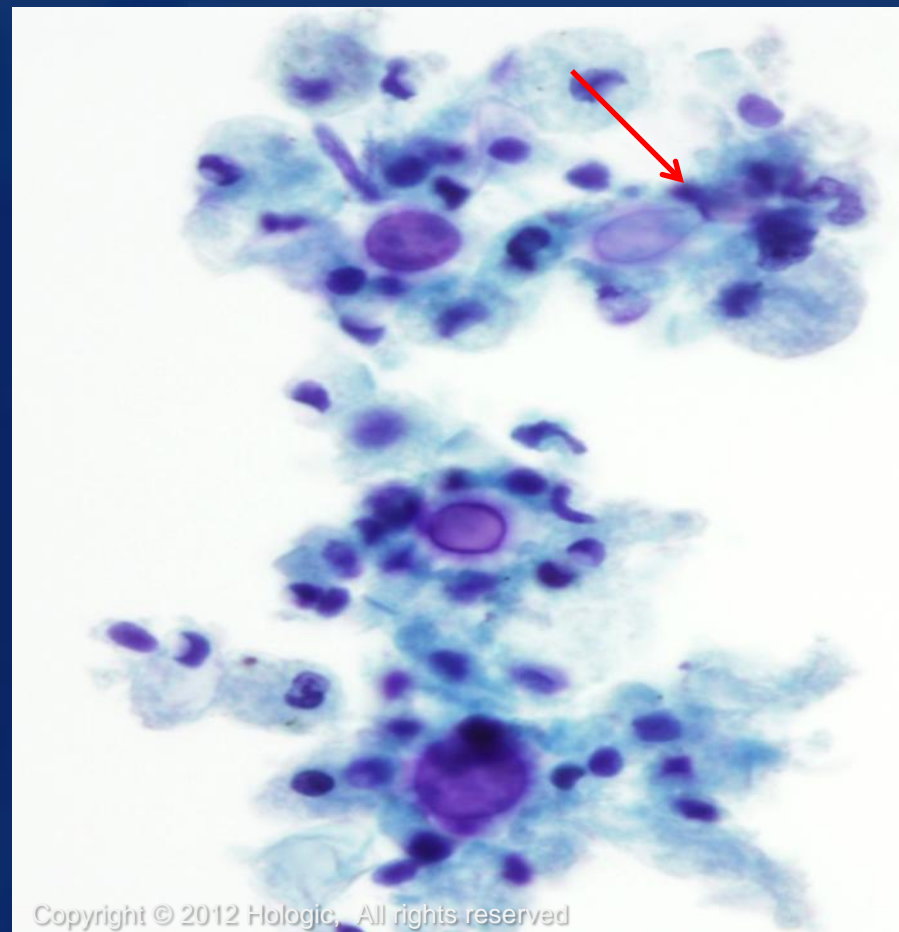
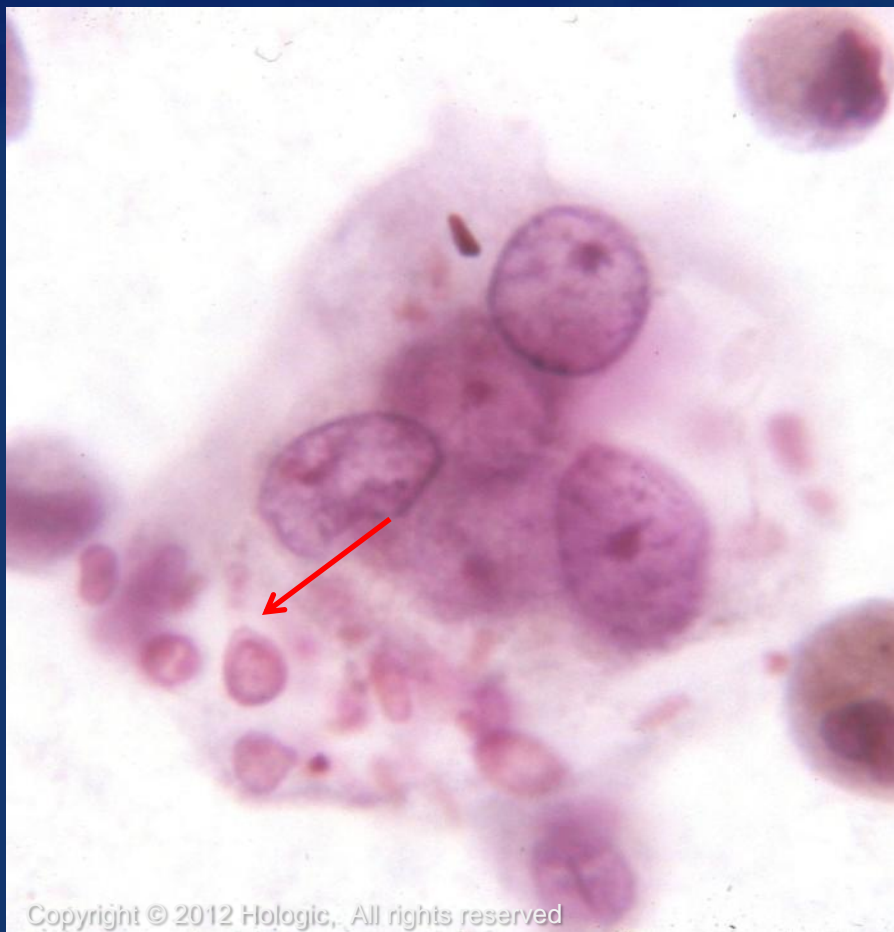

ThinPrep[®]
Non-Gyn

Copyright © 2012 Hologic, All rights reserved

60x

Cryptococcus

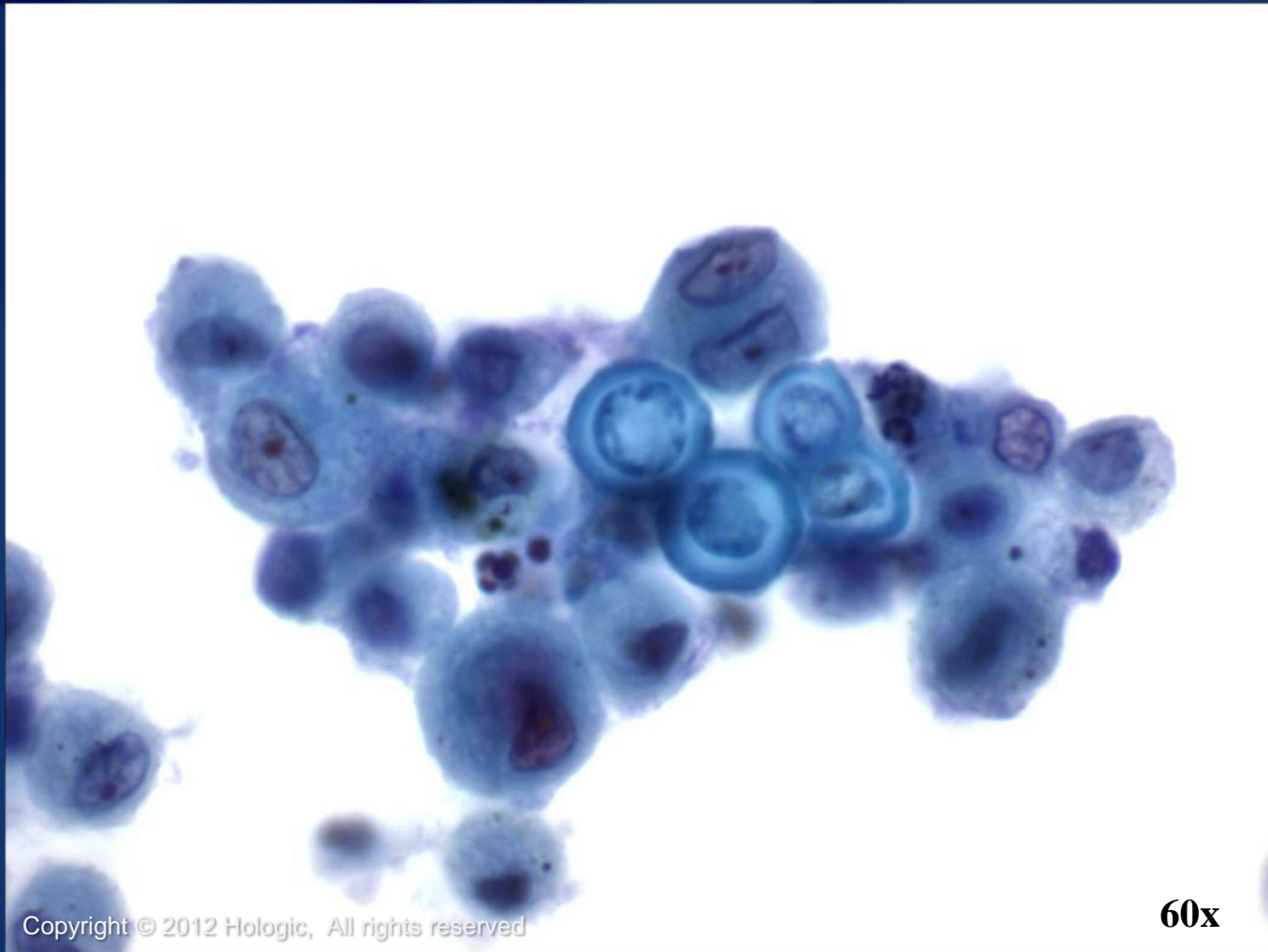


Histoplasma

- Contracted by inhalation of spores of *Histoplasma capsulatum*
- More commonly affects patients who are immunocompromised
- Organism often presents within cytoplasm of macrophages
- Is very small and may be overlooked if silver stains are not used



Blastomyces

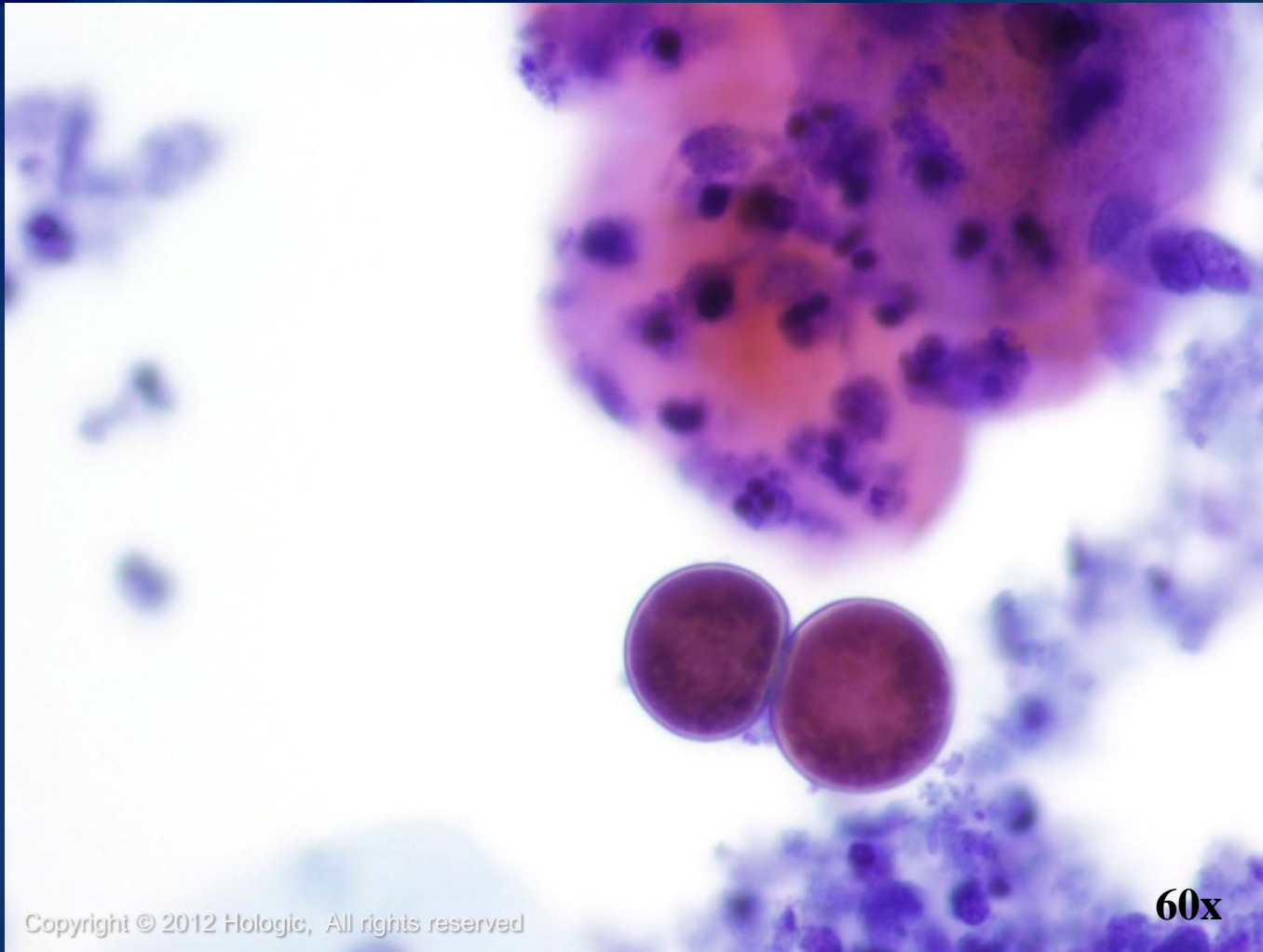


ThinPrep[®]
Non-Gyn

Copyright © 2012 Hologic, All rights reserved

60x

Coccidioides



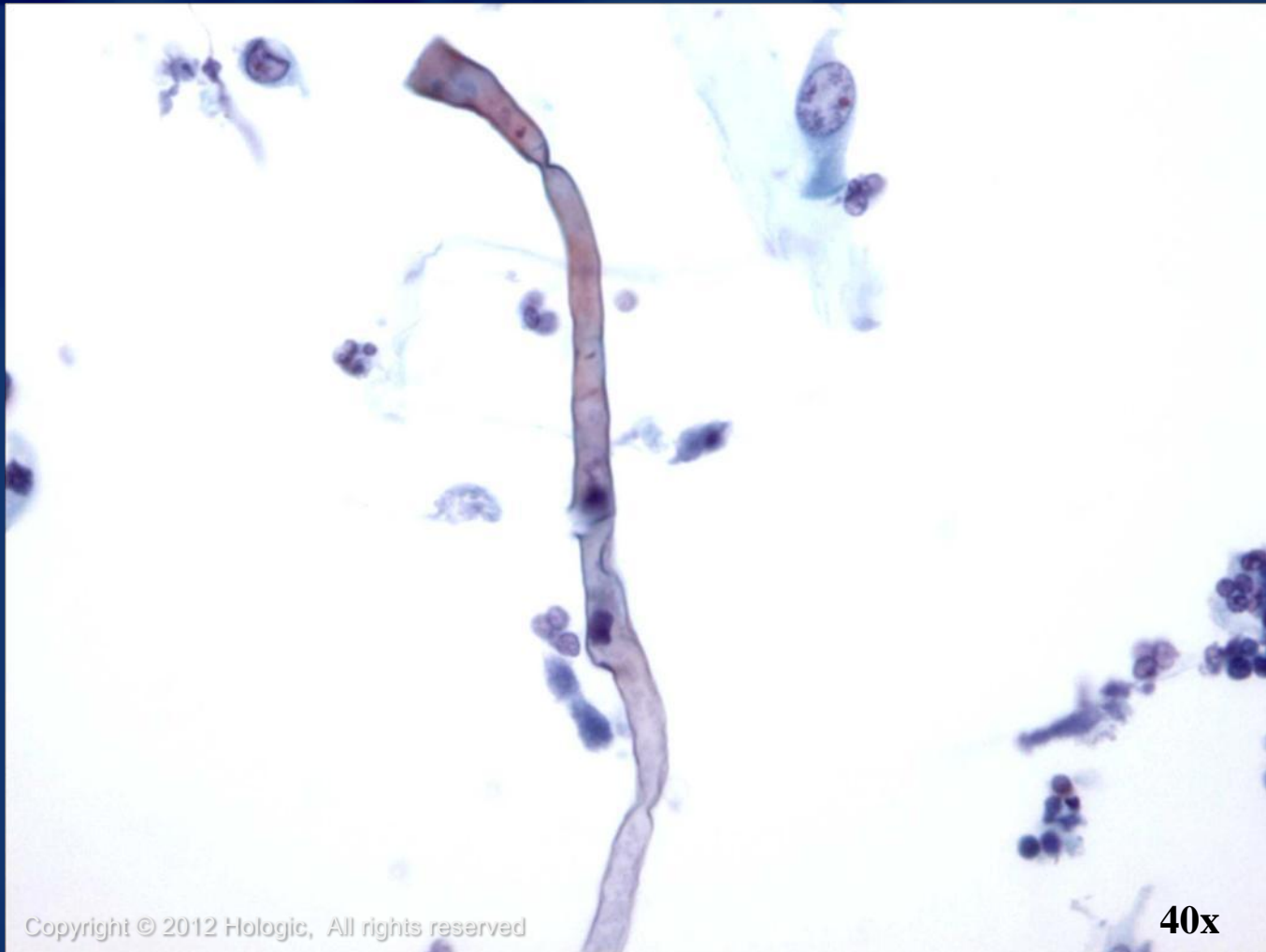ThinPrep[®]
Non-Gyn

Copyright © 2012 Hologic, All rights reserved

60x

Hologic Proprietary © 2012

Zygomyces



Copyright © 2012 Hologic, All rights reserved

40x

ThinPrep[®]
Non-Gyn

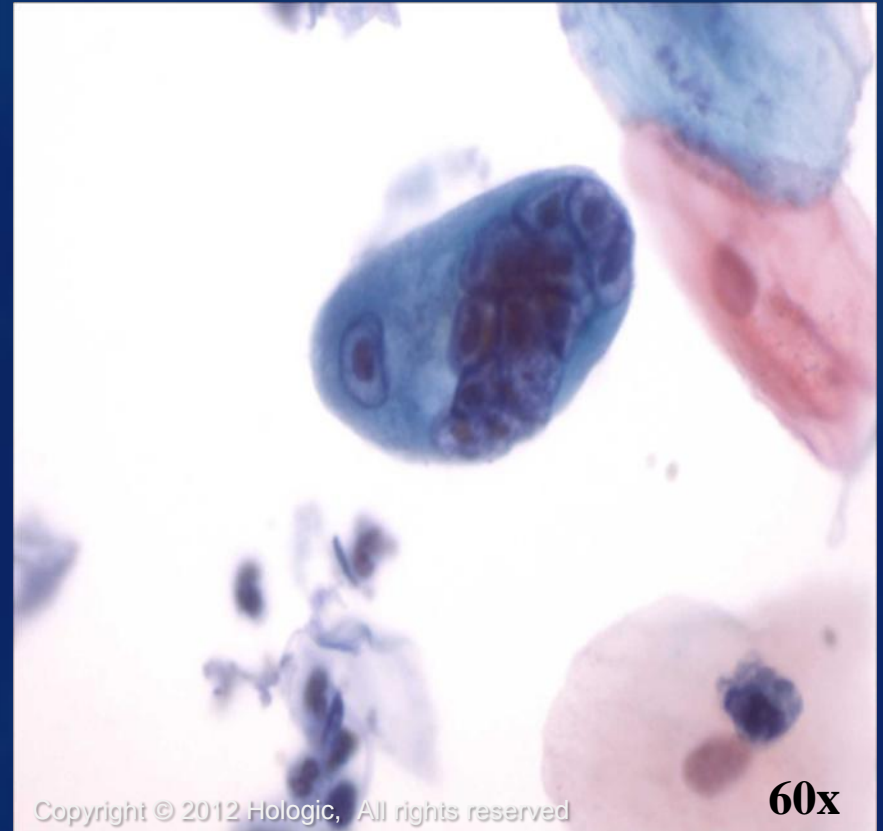
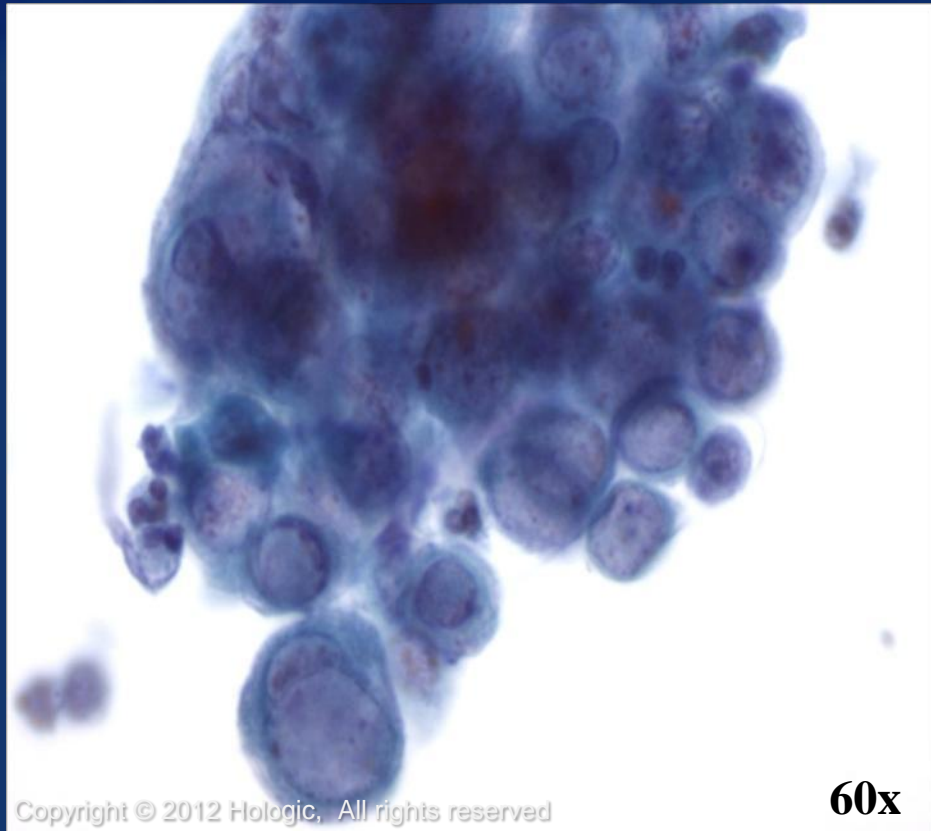
Normal Components and Findings

Infectious agents that may be seen:

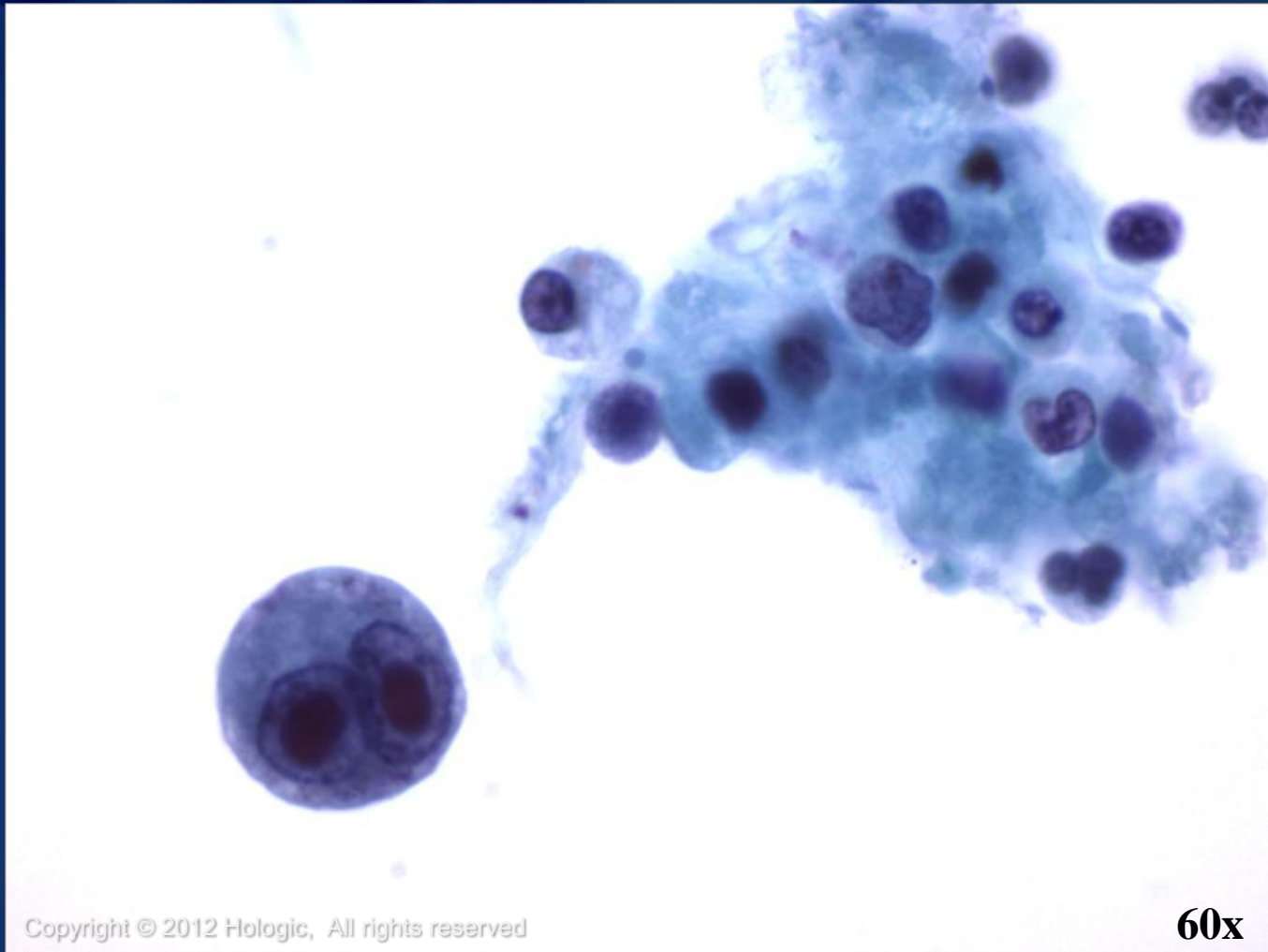
- Viral
 - Herpes
 - CMV
 - Adenovirus
 - Measles
 - Respiratory Syncytial Virus (RSV)
- Nematode
 - Strongyloides



Herpes (HSV)



Cytomegalovirus (CMV)



Adenovirus

- Usually causes minor illness but adenovirus pneumonia can be severe and fatal, especially for those who are immunocompromised
- Causes two types of nuclear inclusions
 - “The smudge cell”- large basophilic inclusions fill the entire nucleus and obscure chromatin detail
 - Eosinophilic inclusion that resembles the Cowdry A inclusion of herpes simplex virus
- Ciliocytophthoria can be prominent



Measles and Respiratory Syncytial Virus (RSV)

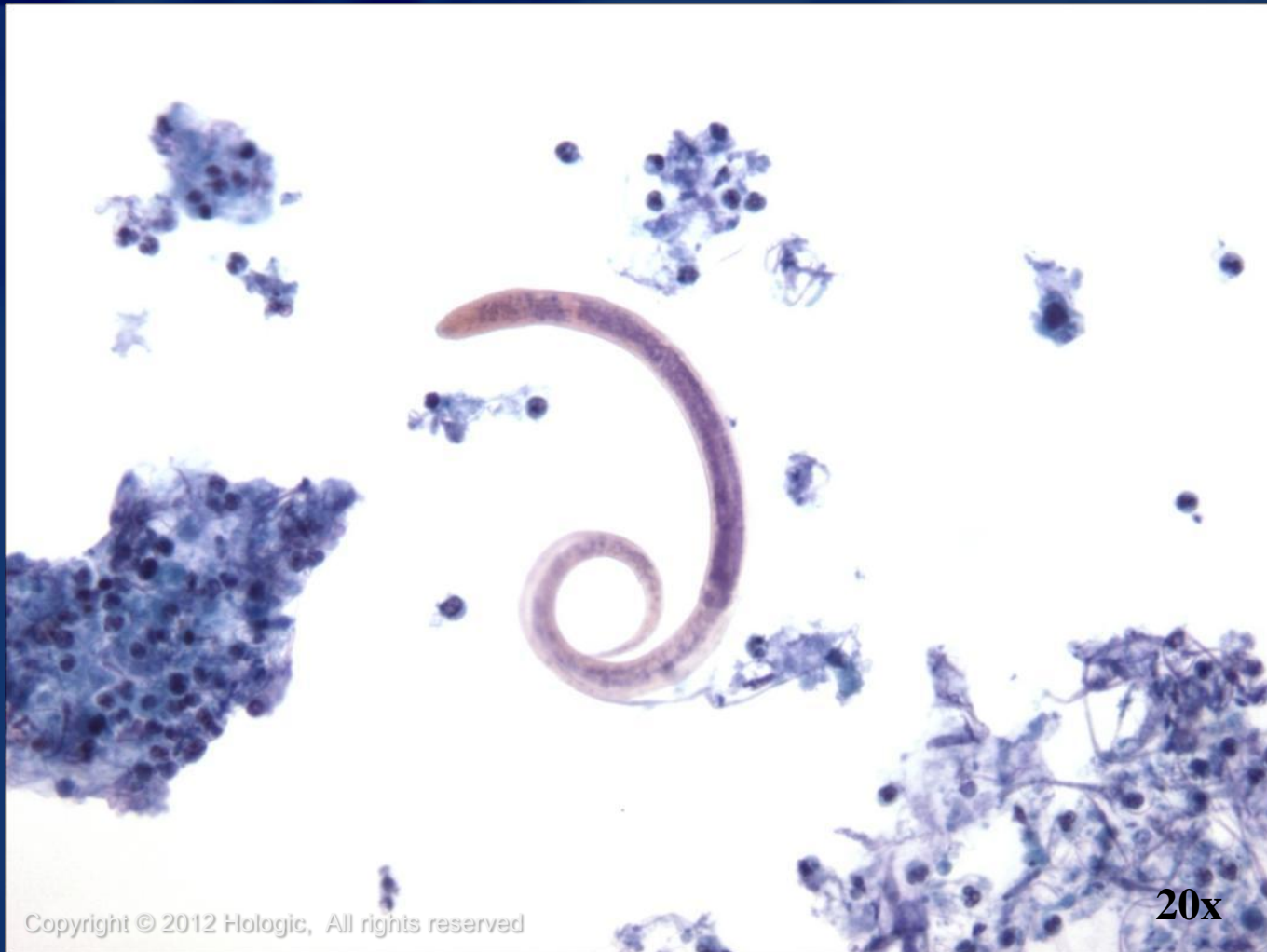- Measles is highly contagious
- Caused by the rubeola virus
- Incidence limited because of vaccination
- Measles pneumonia occurs as an opportunistic complication in children who are immunocompromised

Cytologic features:



- Enormous multinucleated cells with cytoplasmic and nuclear inclusions
- RSV has similar findings and is usually confirmed by detecting RSV antigen in BAL specimens

Strongyloides



ThinPrep[®]
Non-Gyn

Copyright © 2012 Hologic, All rights reserved

20x

Normal Components and Findings

Acellular Material:

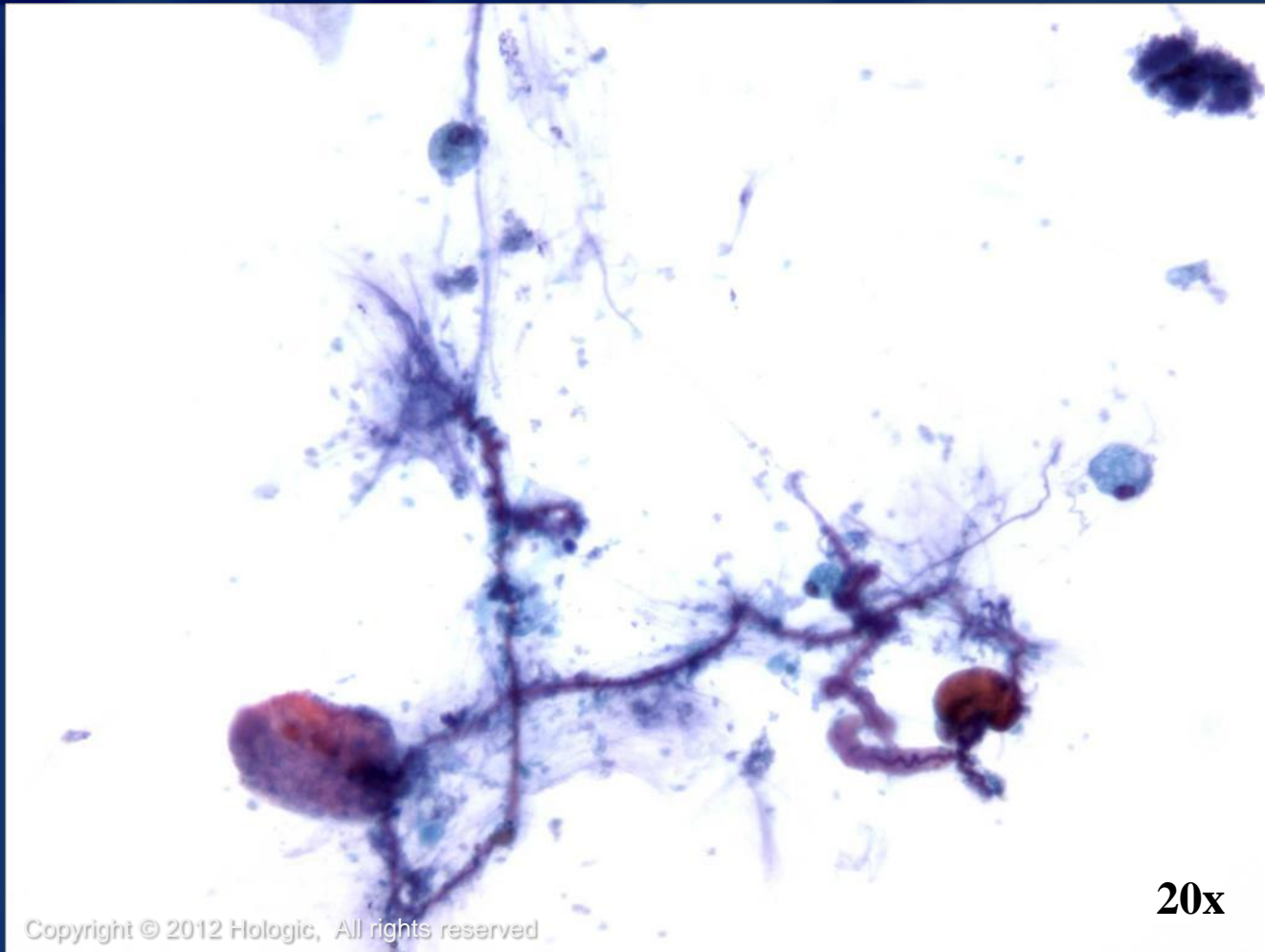
- Curshmann's spirals
- Amorphous mucus
- Corpora Amylacea
- Amyloid
- Psammoma bodies
- Charcot-Leyden Crystals

Other Findings/Contaminants:

- Ferruginous bodies
- Undigested food particles
- Plant material
- Vegetable cells
- Pollen



Curshmann's spirals



ThinPrep[®]
Non-Gyn

Copyright © 2012 Hologic, All rights reserved

20x

Amorphous Mucus

- Also known as mucus bodies or blue blobs
- Can mimic naked malignant nuclei, lacking distinct chromatin pattern or cytoplasm
- Can be round or ring shaped



Corpora Amylacea

- Spherical structures with circumferential and radiating lines
- Measure between 30 and 200 μm
- Indistinguishable from those seen in the prostate
- No known clinical significance
- More commonly seen in older patients



Amyloid

- Occurs as multiple, irregular, dense, acellular fragments of eosinophilic material
- Waxy, homogenous appearance, with sharp often scalloped margins
- Characteristic apple green birefringence is seen under polarized light with Congo red staining



Psammoma Bodies

- Concentrically laminated, calcified, basophilic bodies surrounded by cells
- May be associated with cancers such as bronchioloalveolar carcinoma or metastatic papillary carcinoma
- May also be seen in benign conditions such as alveolar microlithiasis

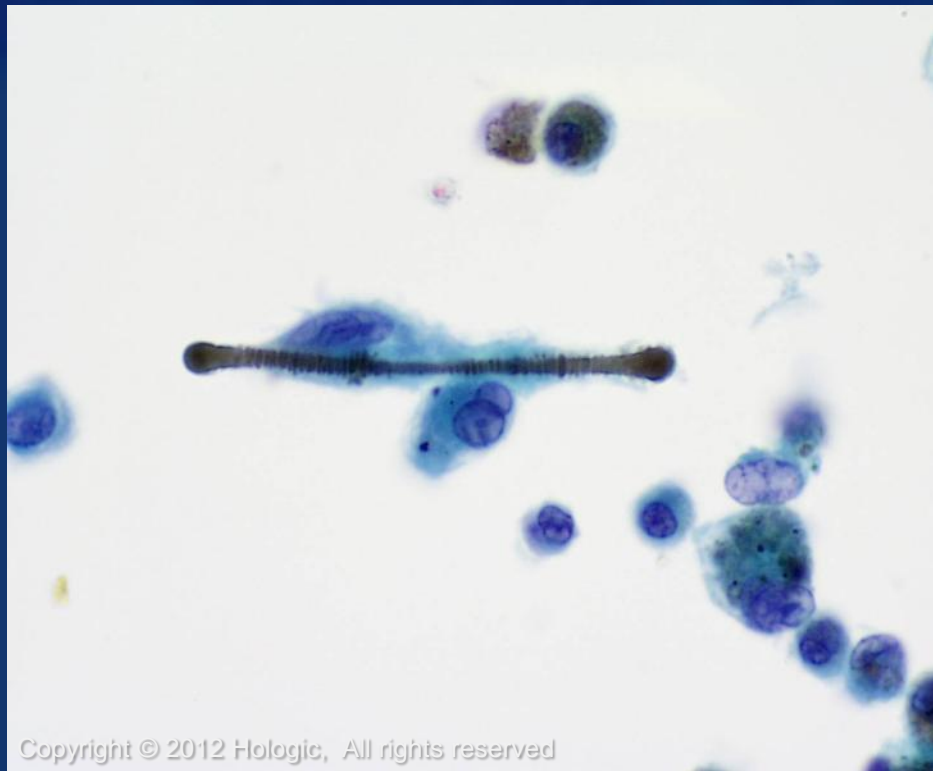

Charcot-Leyden Crystals

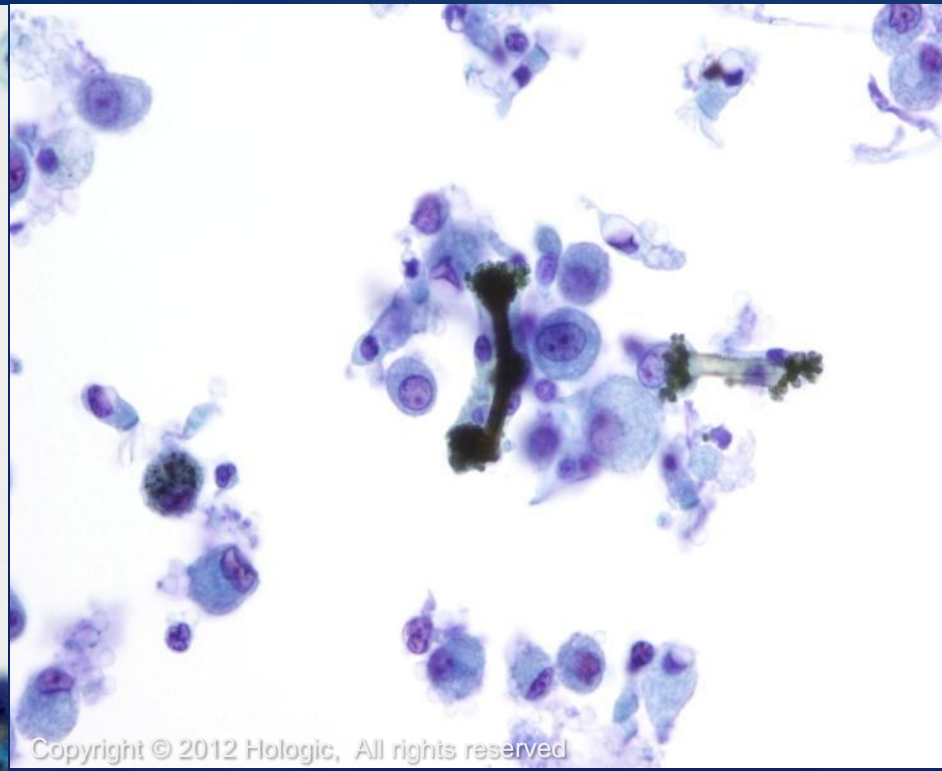
- Rhomboid-shaped, orangeophilic structures derived from degenerating eosinophils
- Can be seen in patients with severe allergic disorders like asthma



Ferruginous bodies



Copyright © 2012 Hologic, All rights reserved



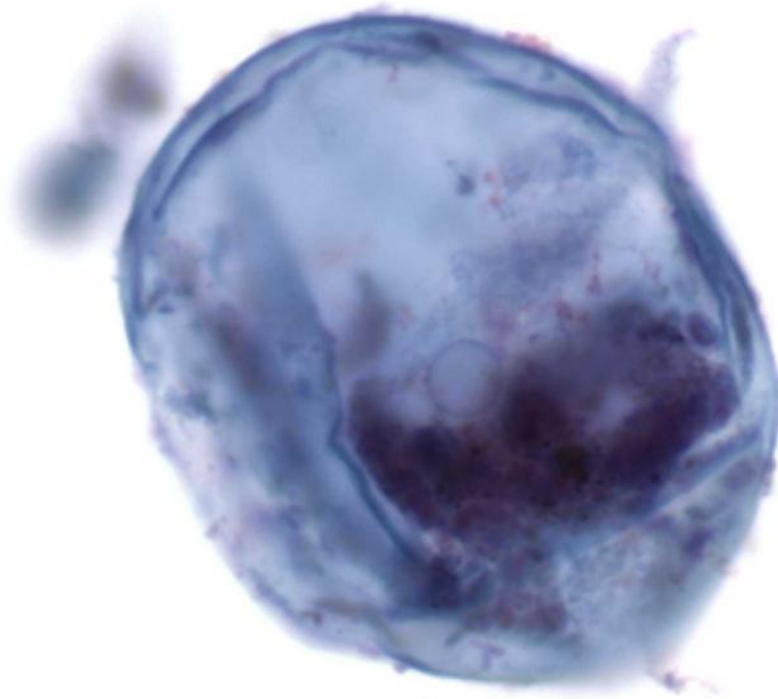
Copyright © 2012 Hologic, All rights reserved

Undigested Food/Plant Material

- Food particles are common in sputum
- Meat is characterized by cross striations
- Plant cells may have very dark, smudgy nuclei with translucent refractile cell walls
- May mimic adenocarcinoma or squamous cell carcinoma



Vegetable cell

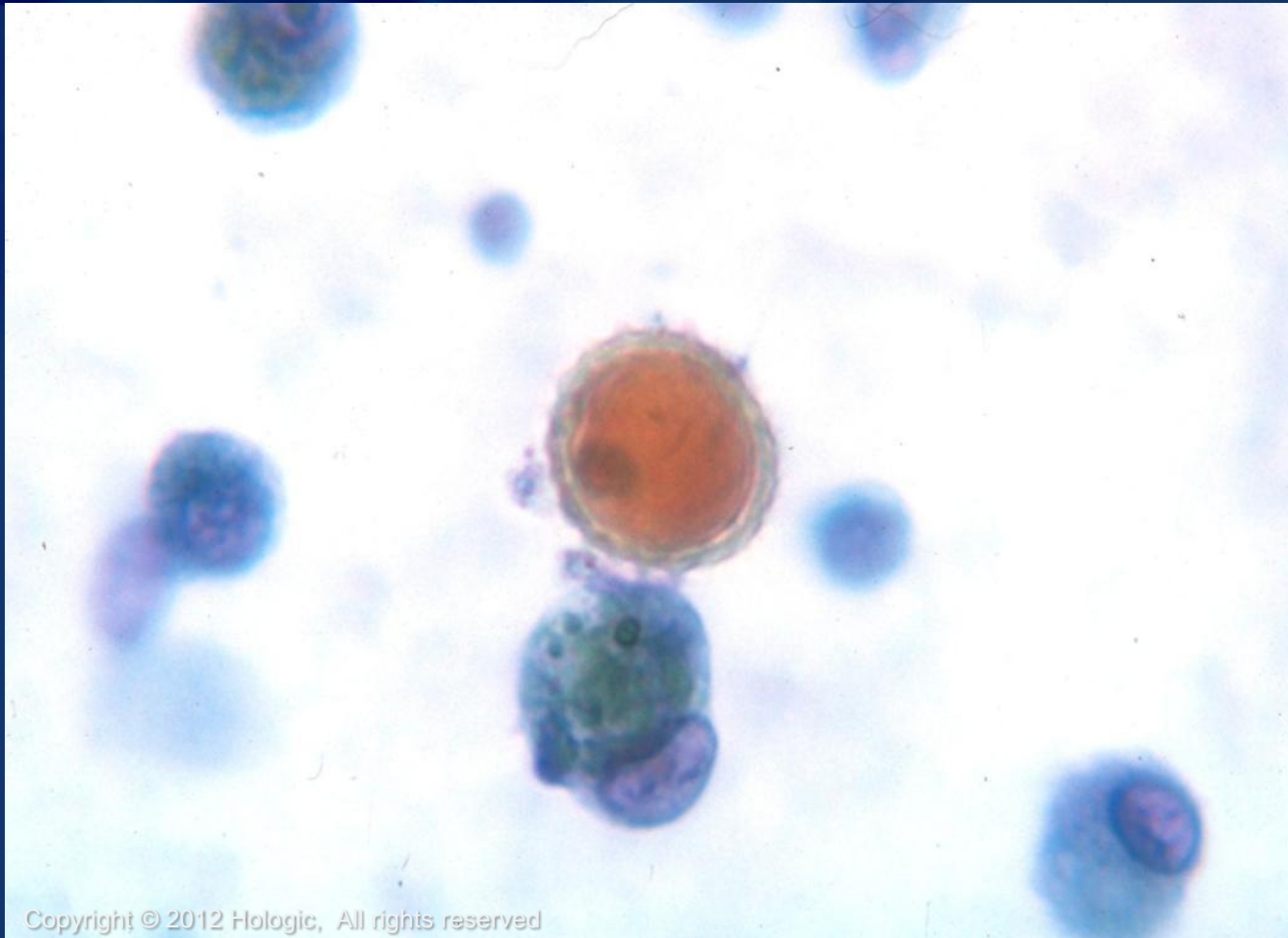


ThinPrep[®]
Non-Gyn

Copyright © 2012 Hologic, All rights reserved

60x

Pollen



Copyright © 2012 Hologic, All rights reserved

ThinPrep
Non-Gyn

Benign Entities and Changes

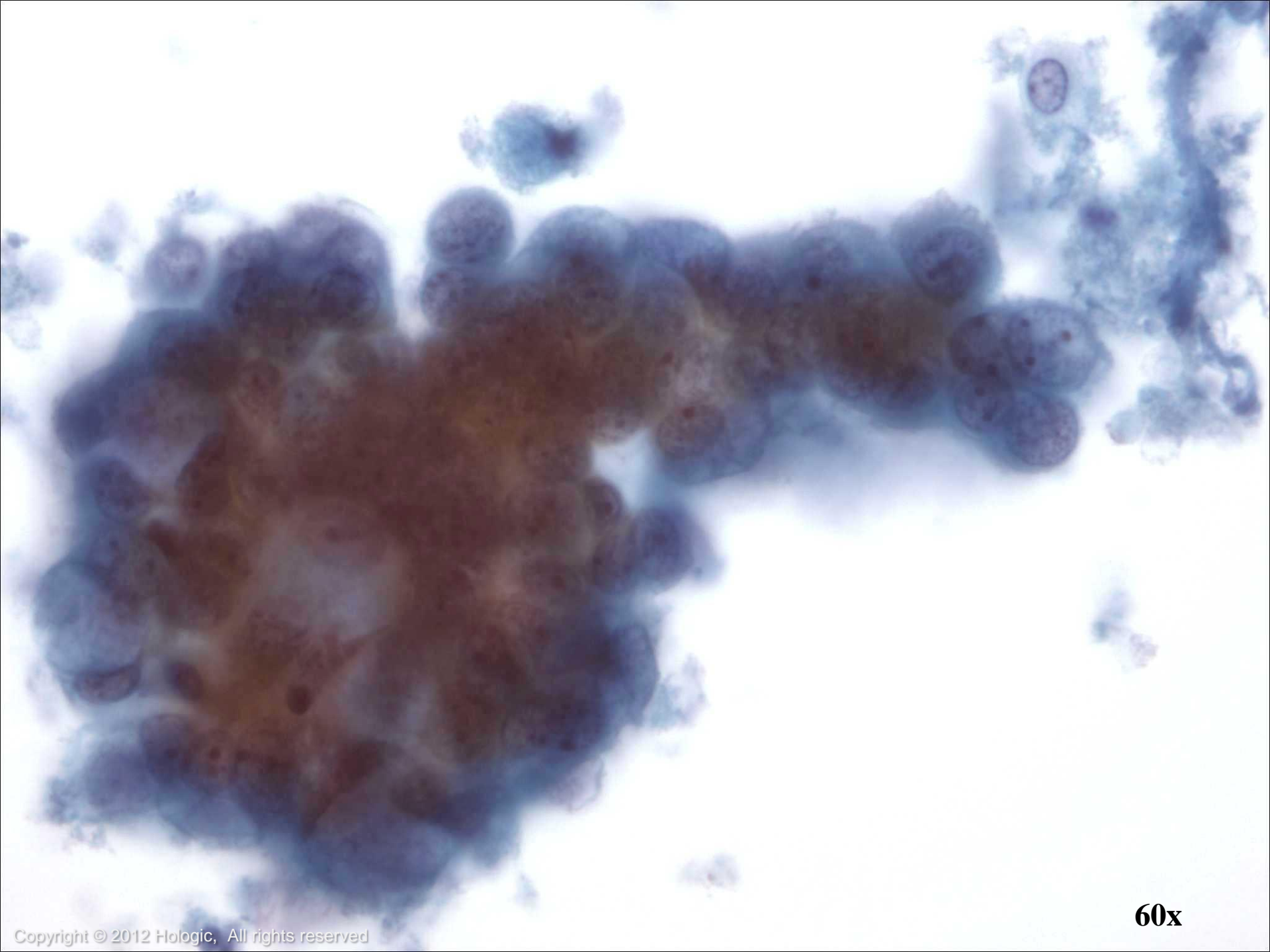
- Reactive changes are common and may be due to:
 - Instrumentation
 - Infection or toxins (including smoking or tracheobronchial disease)



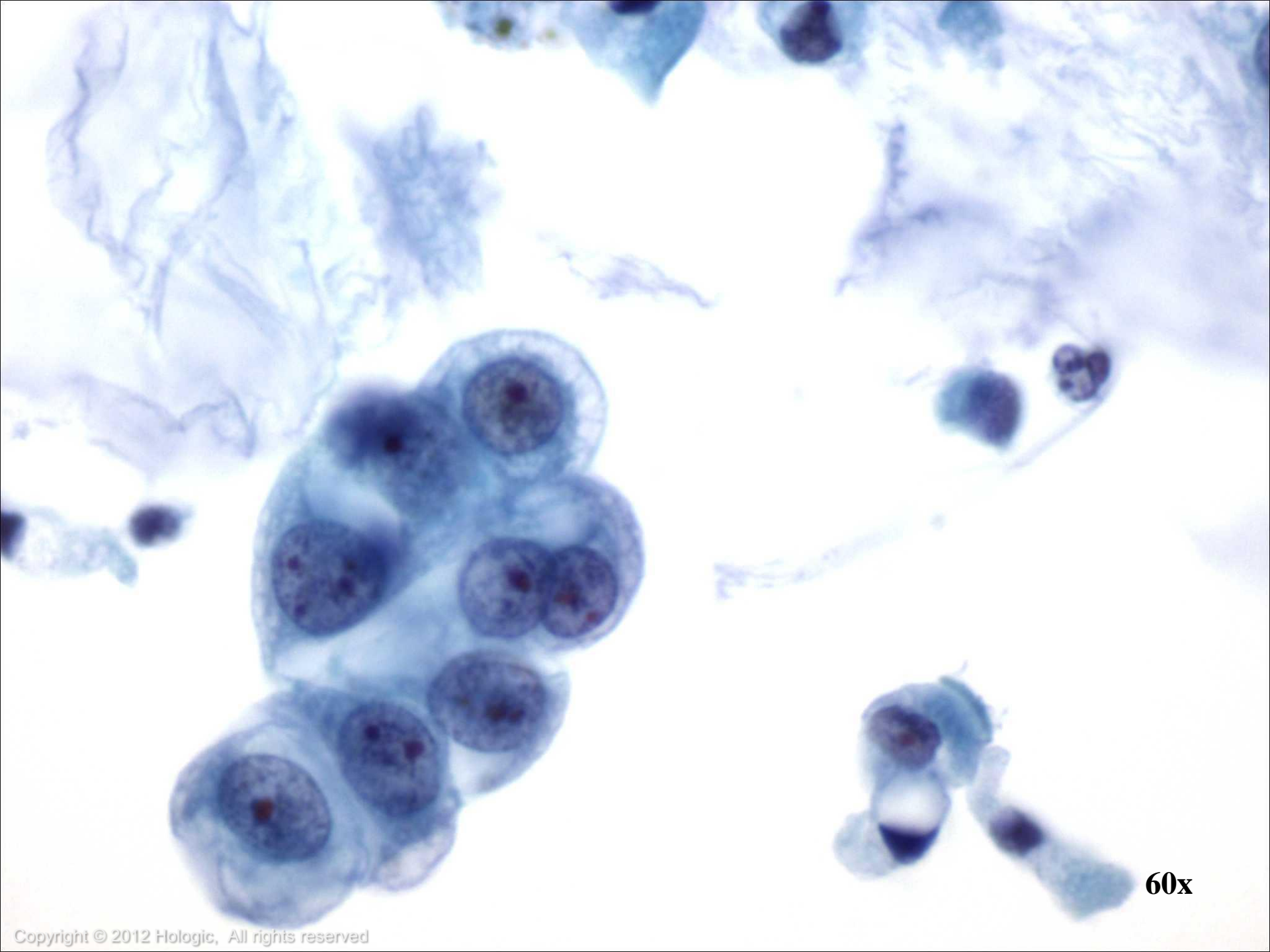
Reactive Changes

- Features of reactive bronchial cells may include:
 - Enlarged pleomorphic nuclei
 - Prominent nucleoli
 - Coarse, hyperchromatic chromatin
 - Multinucleation
 - Abundant cytoplasm

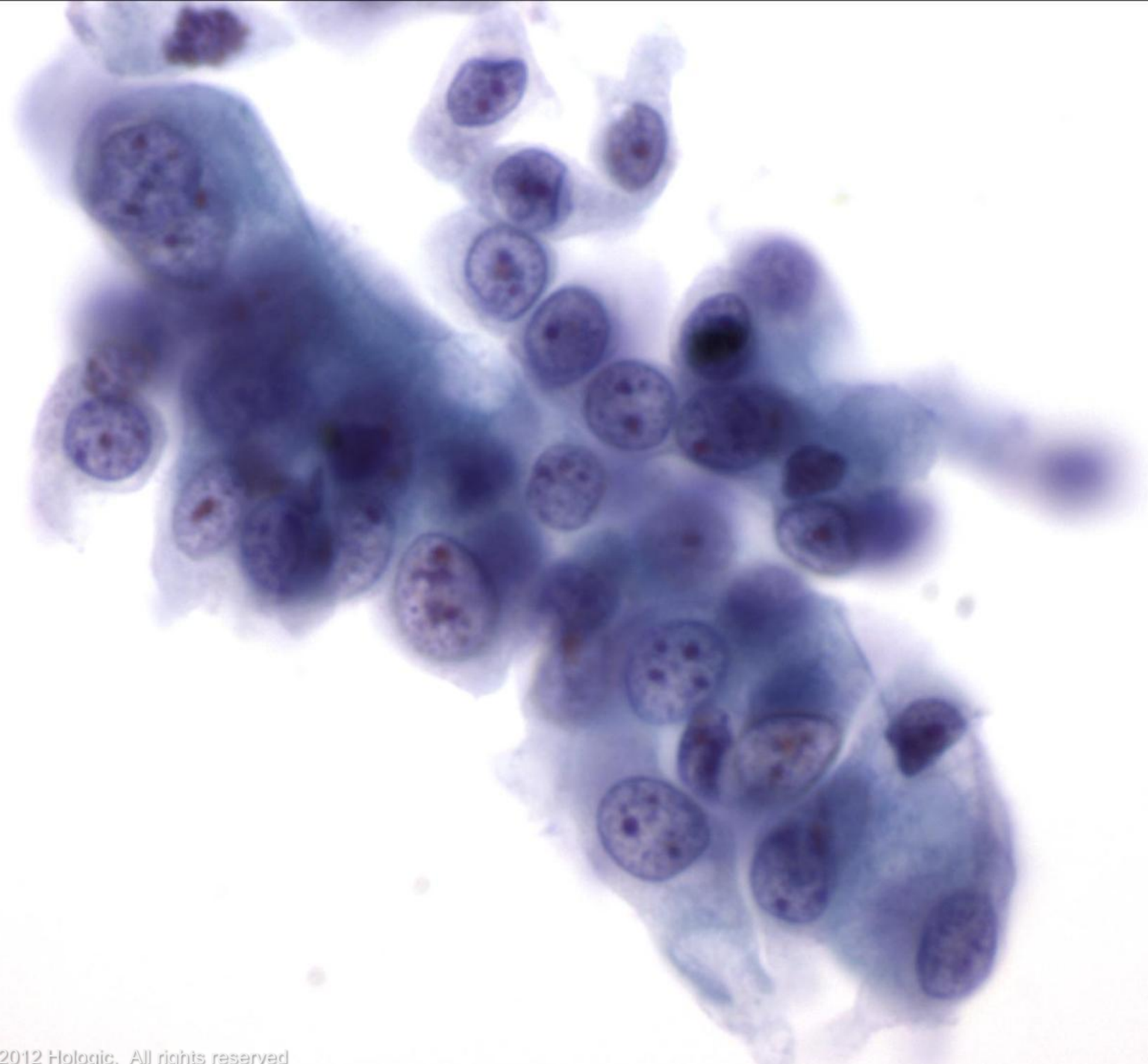



60x



60x

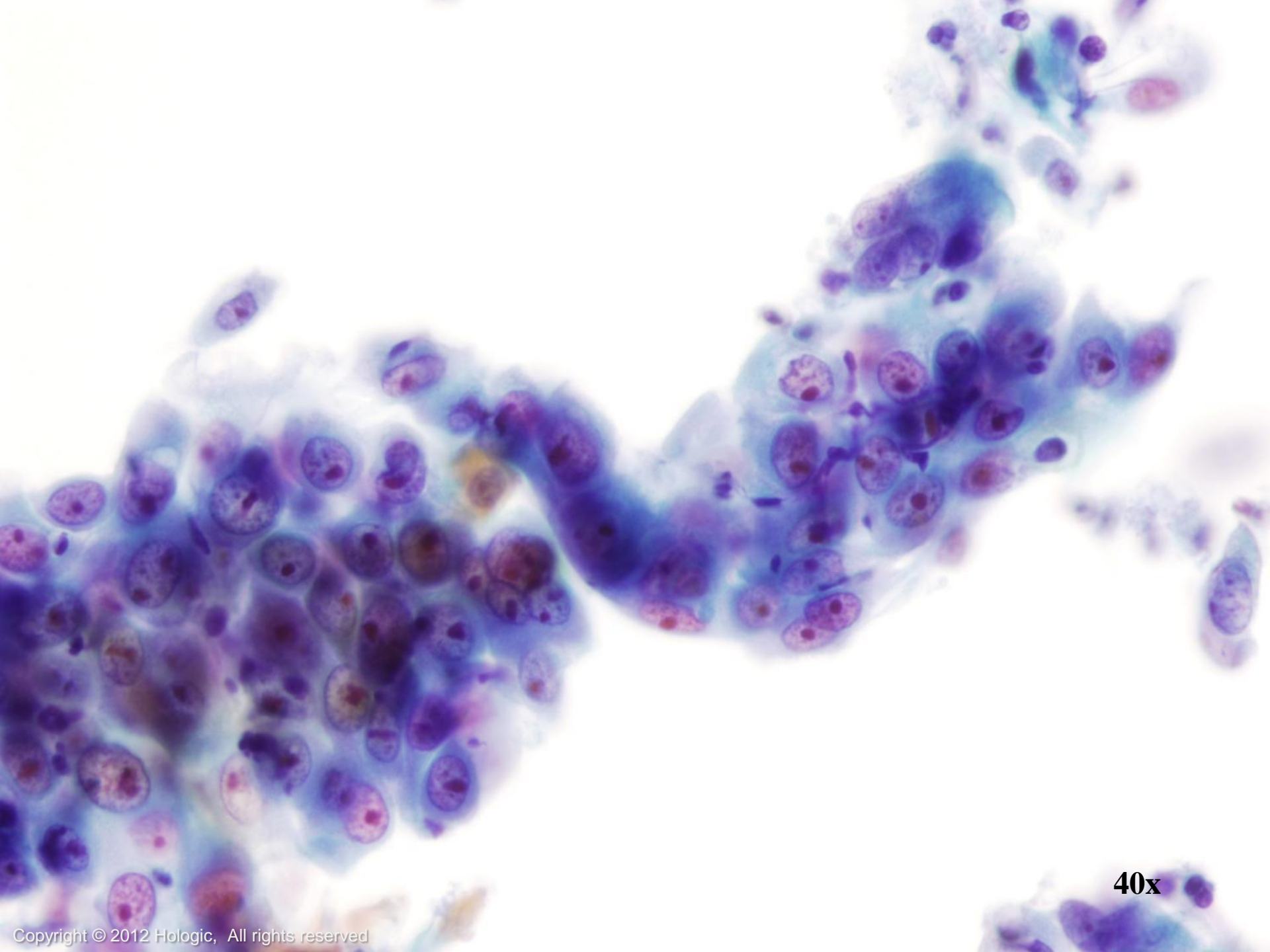


60x

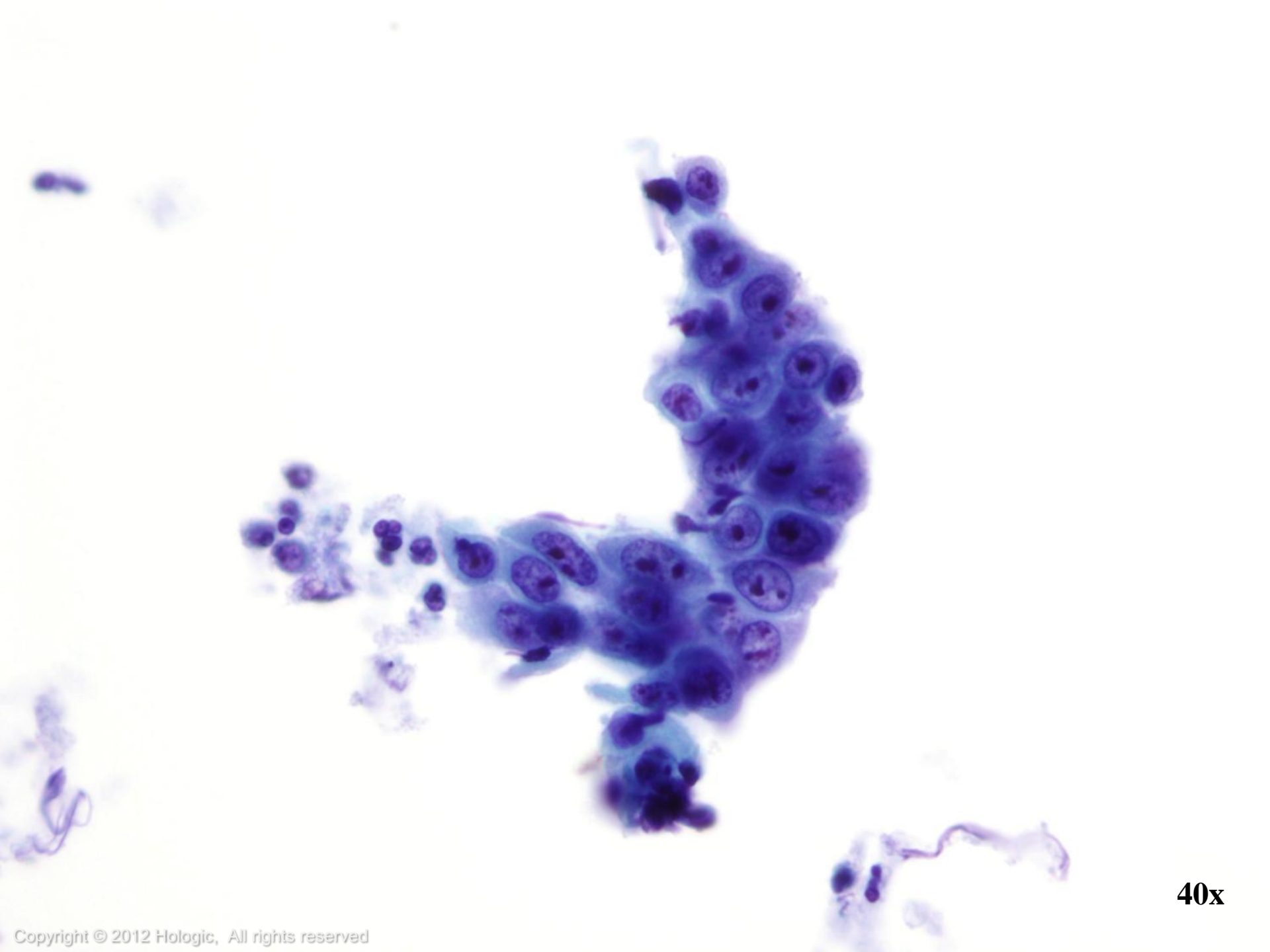
Reparative Changes

- Similar to that seen in Gyn samples
- Atypia can range from mild to severe, and may mimic cancer
- Unlike with cancer, both the nucleus and cytoplasm of reparative cells increase in size, maintaining a benign N/C ratio

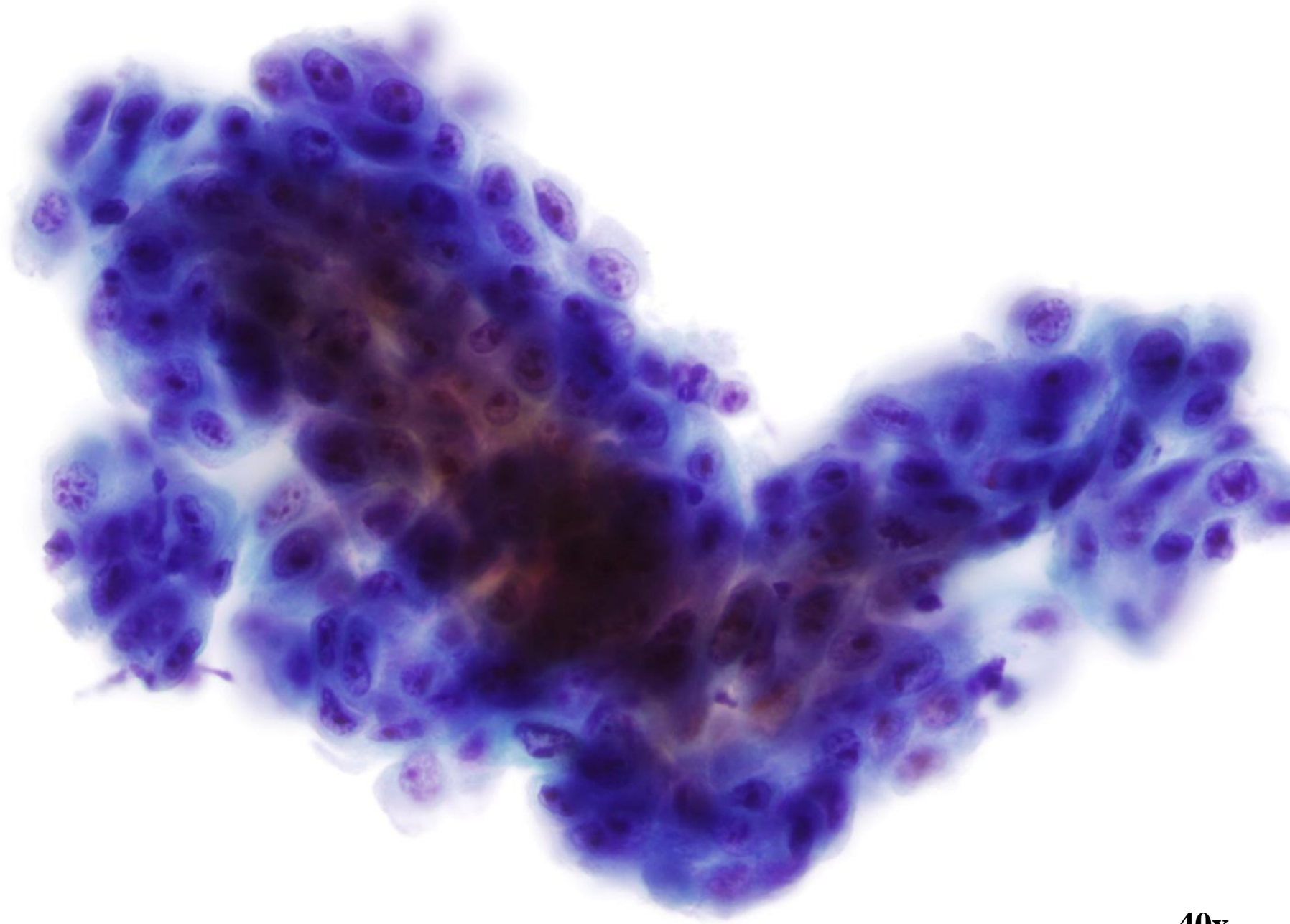




40x



40x



40x

Benign Proliferation

The bronchial epithelium can undergo a series of changes due to chronic irritation:

- Reserve Cell Hyperplasia
- Squamous Metaplasia
- Parakeratosis, Atypical Parakeratosis
- Bronchial Hyperplasia



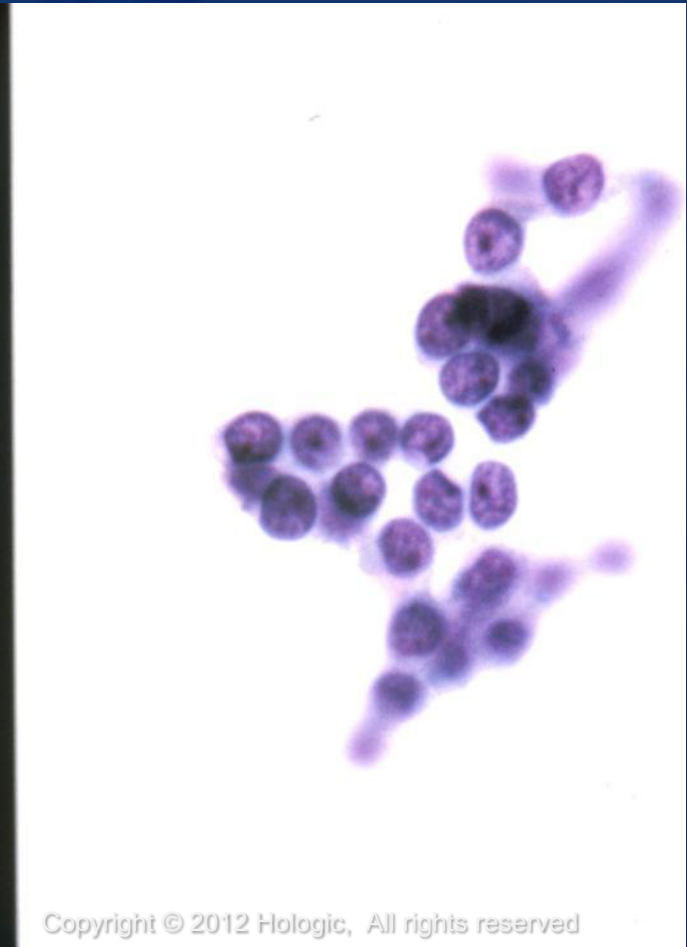
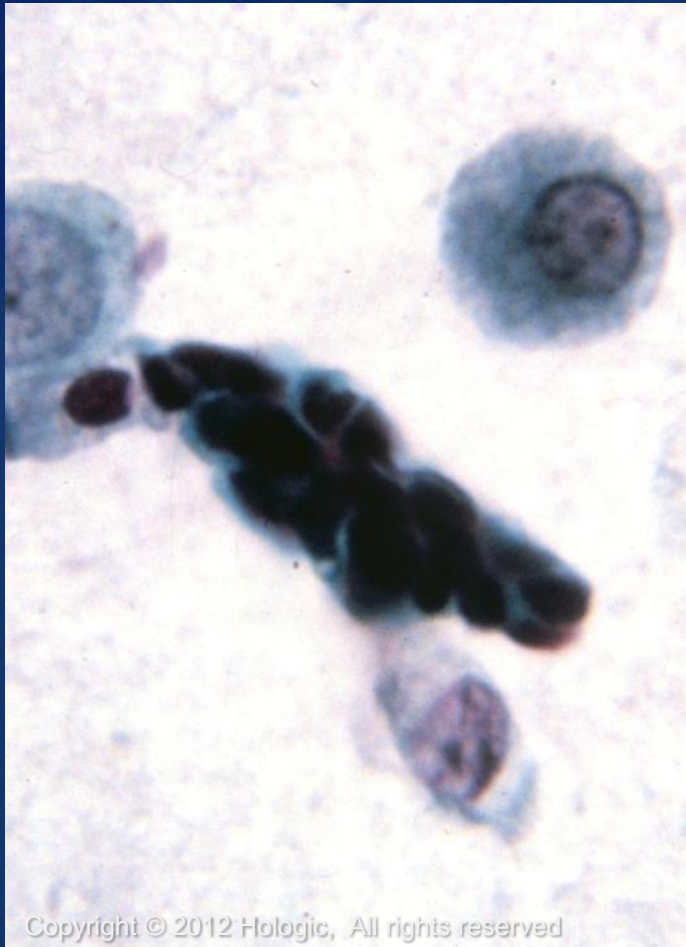Benign Proliferation

Reserve Cell Hyperplasia (RCH)

- Tightly cohesive groups of reserve cells
- Nuclear molding may identified
- Differential diagnoses include lymphocytes and small cell carcinoma



Reserve Cell Hyperplasia



ThinPrep[®]
Non-Gyn

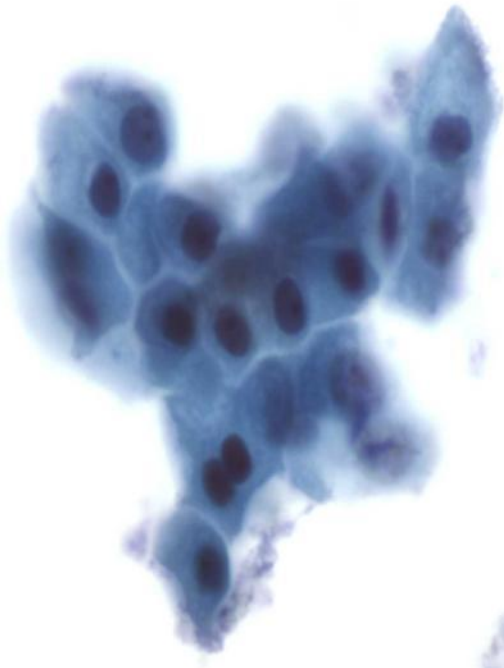
Benign Proliferation

Squamous Metaplasia

- Very common, occurring in 20% to 80% of all patients
- May be present due to irritation but may also be associated with cancer
- Frequently occurs with RCH
- Immature respiratory metaplasia is smaller with more polygonal cytoplasm

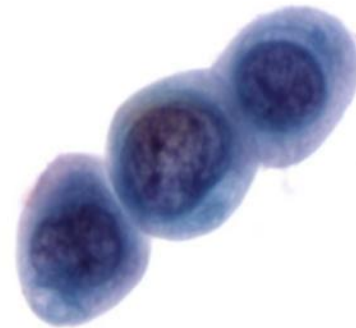


Squamous Metaplasia



Copyright © 2012 Hologic, All rights reserved

60x



Copyright © 2012 Hologic, All rights reserved

60x

Benign Proliferation

Parakeratosis/Atypical Parakeratosis

- Similar to parakeratosis seen in Gyn samples
- Associated with irritation/inflammation or dysplasia/cancer
- Usually arises in the mouth or in the tracheobronchial tree
- May be difficult to distinguish from keratinizing squamous cell carcinoma



Benign Proliferation

Bronchial Hyperplasia

- Pseudopapillary, 3-dimensional groups of reactive/atypical bronchial cells
- Reactive nuclei are uniform in size and shape
- Fine to coarse, evenly distributed chromatin
- Nucleoli are uniform but prominent
- Cytoplasm is variable and may have vacuoles of varying sizes



Pneumoconioses

Pneumoconiosis

- name given to the occupational and restrictive lung disease caused by inhalation of dust
- the type of dust gives each disease its name
 - Silicosis (silica)
 - Asbestosis (asbestos)
 - Berylliosis (beryllium)
 - Anthracosis (coal, carbon)
 - Byssinosis (cotton)
 - Hemosiderosis (iron)



Miscellaneous Conditions

- Eosinophilic Pneumonia- presence of marked increase in eosinophils
 - Also known as Löffler's Pneumonia
- Giant Cell Interstitial Pneumonia- often caused by exposure to hard metals
 - Benign multinucleated giant cell histiocytes which may contain phagocytosed debris or cells
- Atelectasis- collapse of all or part of lung
 - Cytology presence with atypical squamous cells and foreign body macrophages



Noninfectious Diseases

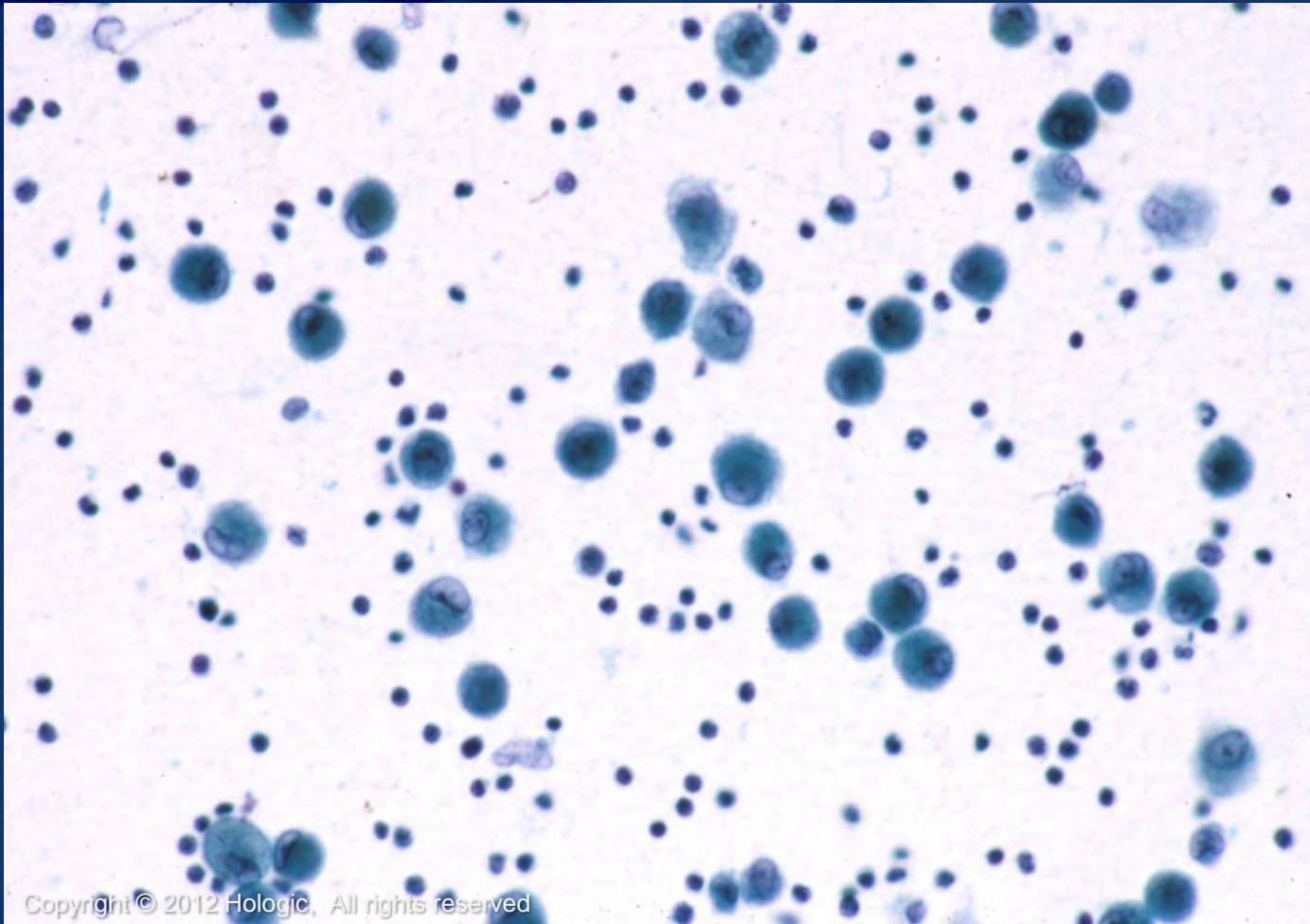
- Sarcoidosis-common disease, characterized by noncaseating granulomas in many organs, commonly the lung

Cytologic features:

- Aggregates of epithelioid histiocytes
- Multinucleated giant cells
- Lymphocytes



Sarcoidosis



ThinPrep[®]
Non-Gyn

Copyright © 2012 Hologic, All rights reserved

Noninfectious Diseases Continued

- Wegener Granulomatosis- presents as a lung mass with or without involvement of other organs

Cytologic features: non specific

- Necrotic collagen, giant cells,

granulomas, and neutrophils



Benign Neoplasms

- Pulmonary Hamartoma
- Inflammatory Myofibroblastic Tumor (IMT)
- Endobronchial Granular Cell Tumor



Pulmonary Hamartoma

Cytologic features:

- Benign glandular cells
- Immature fibromyxoid matrix and bland spindle cells
- Mature cartilage with chondrocytes
- Adipocytes



Inflammatory Myofibroblastic Tumor (IMT)

Cytologic features:

- Spindle cells
- Arranged in fascicles or storiform pattern
- Abundant polymorphous inflammatory cells
- Minimal if any necrosis



Endobronchial Granular Cell Tumor

Cytologic features:

- Small clusters of macrophage-like cells
- Nuclei are small, uniform and round to oval
- Abundant granular cytoplasm

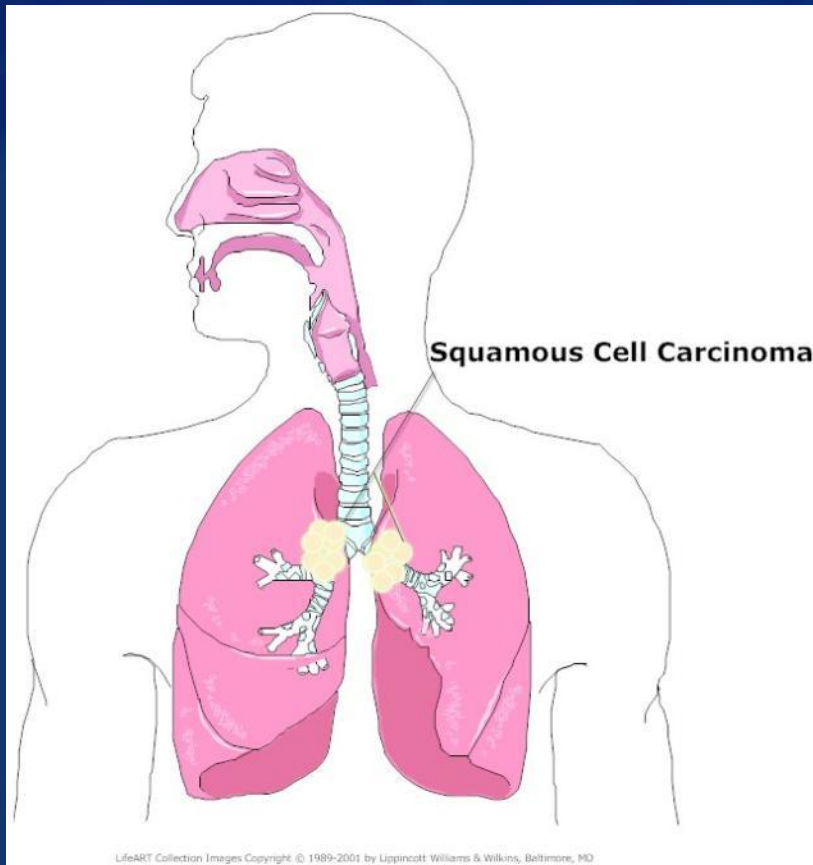


Abnormal Findings

- Squamous Cell Carcinoma
- Adenocarcinoma
- Large Cell Undifferentiated Carcinoma
- Small Cell Undifferentiated Carcinoma
- Metastatic Carcinomas



Squamous Cell Carcinoma



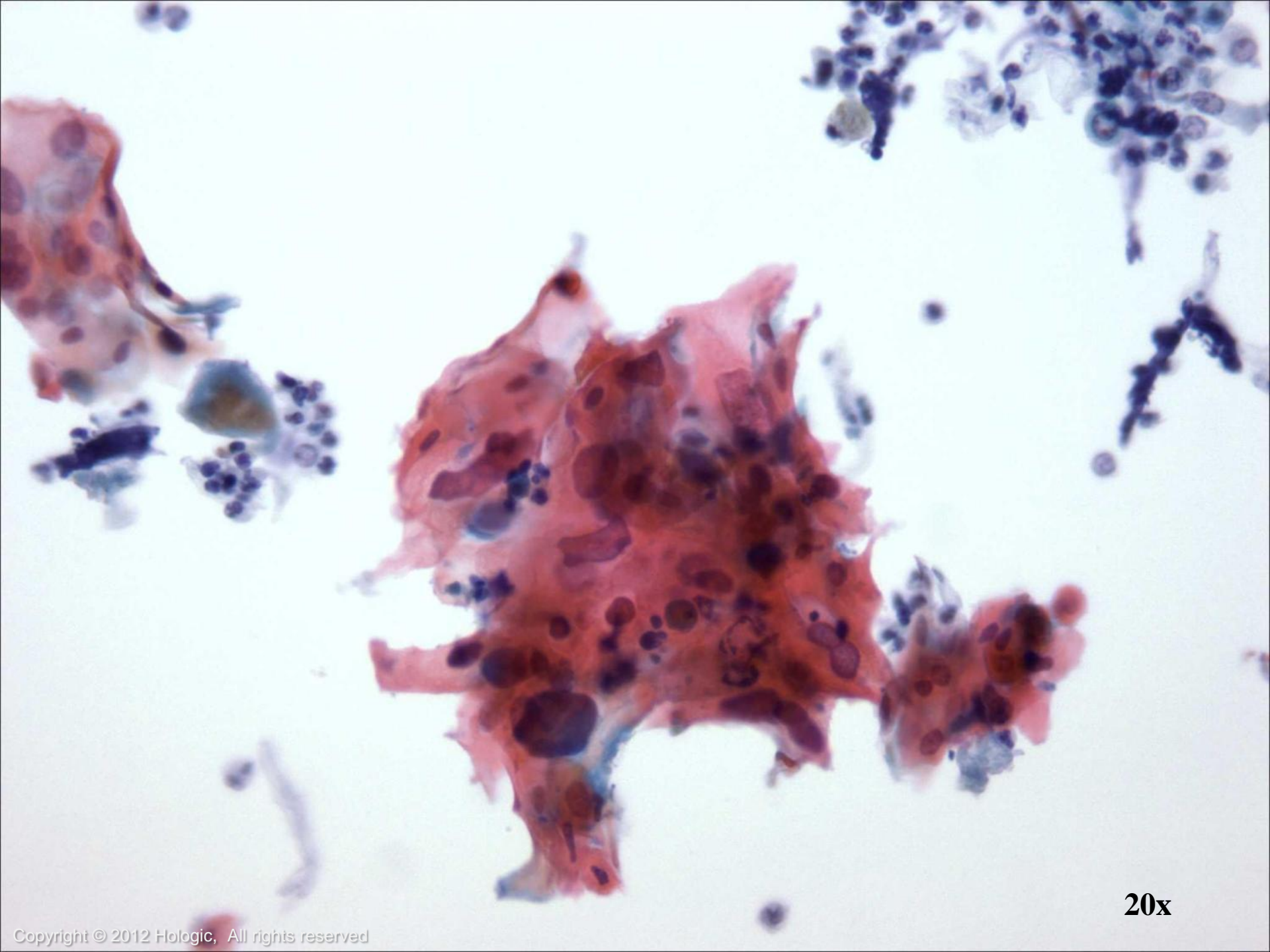
- Most common sub-type
- Range from poorly to well differentiated
- Tumors tend to arise centrally
- Can be diagnosed with sputum cytology and bronchial brushing/washing

Keratinizing Squamous Cell Carcinoma

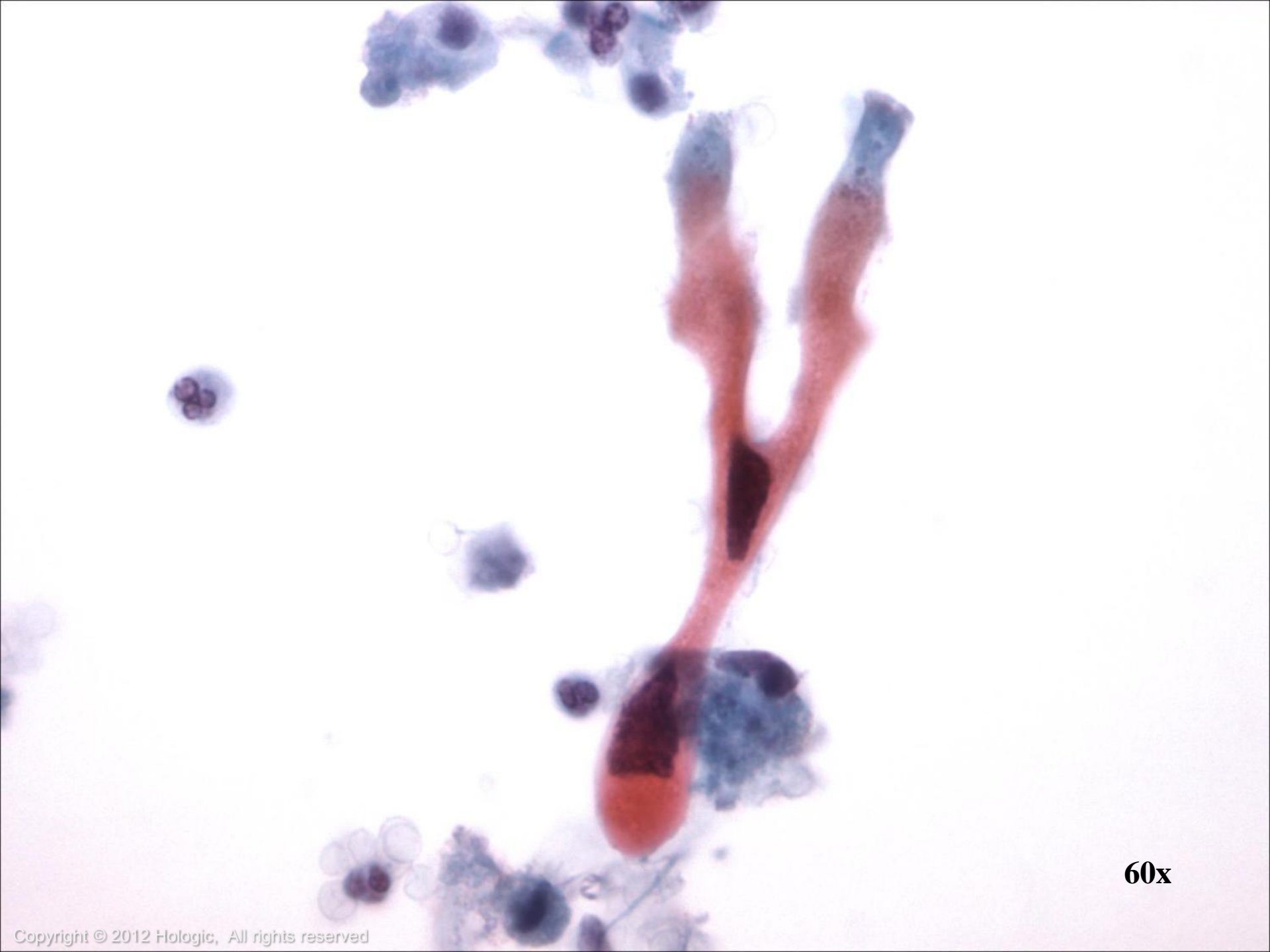
Cytologic features:

- Bizarre cell shapes
- Numerous single cells
- Nuclei are pleomorphic
- Chromatin ranges from coarse and dark to pyknotic or ink dot-like
- Cytoplasm is dense, waxy, or “hard” with well defined cell borders, ranges from scant to abundant
- Extensive necrosis

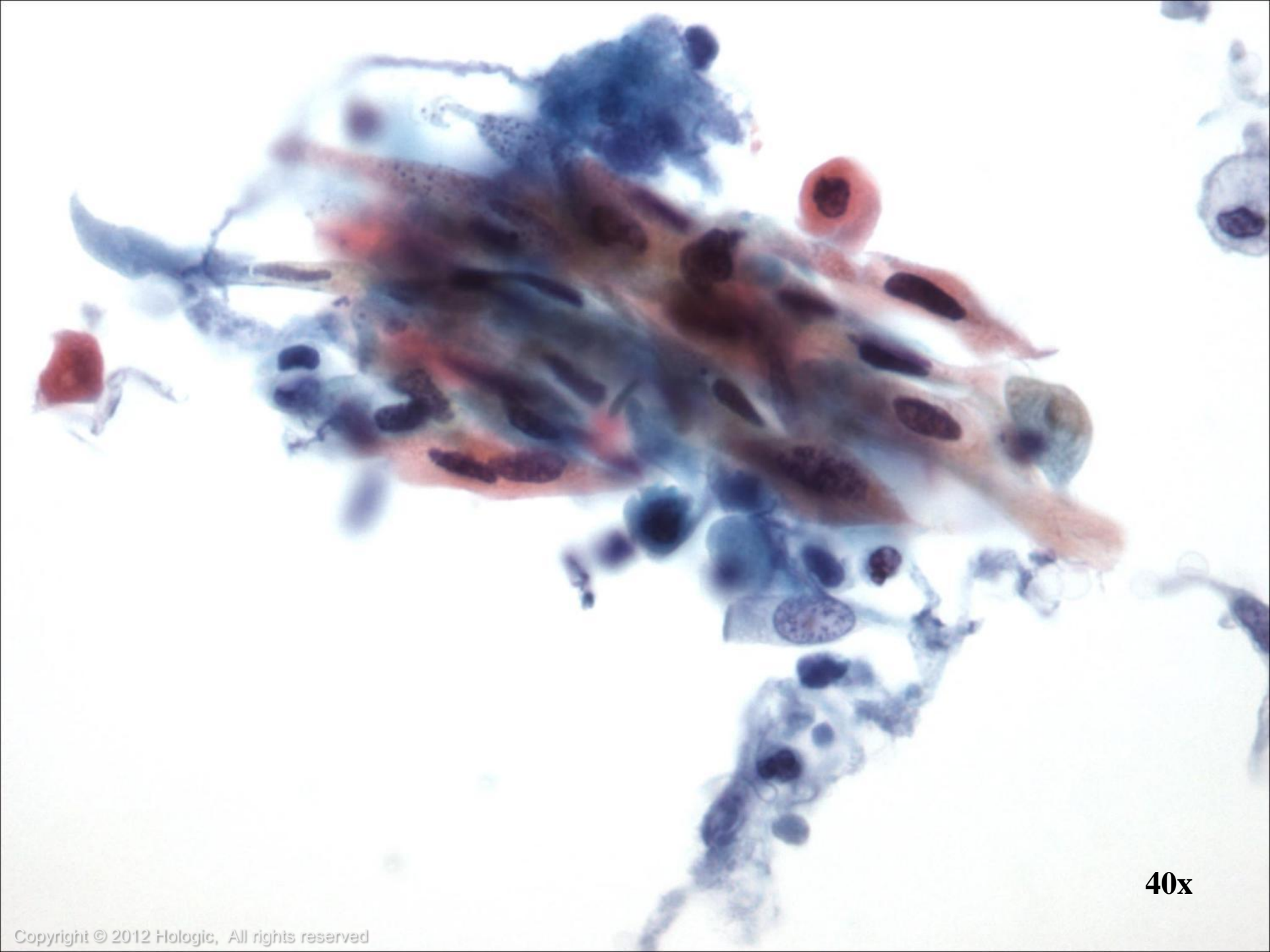




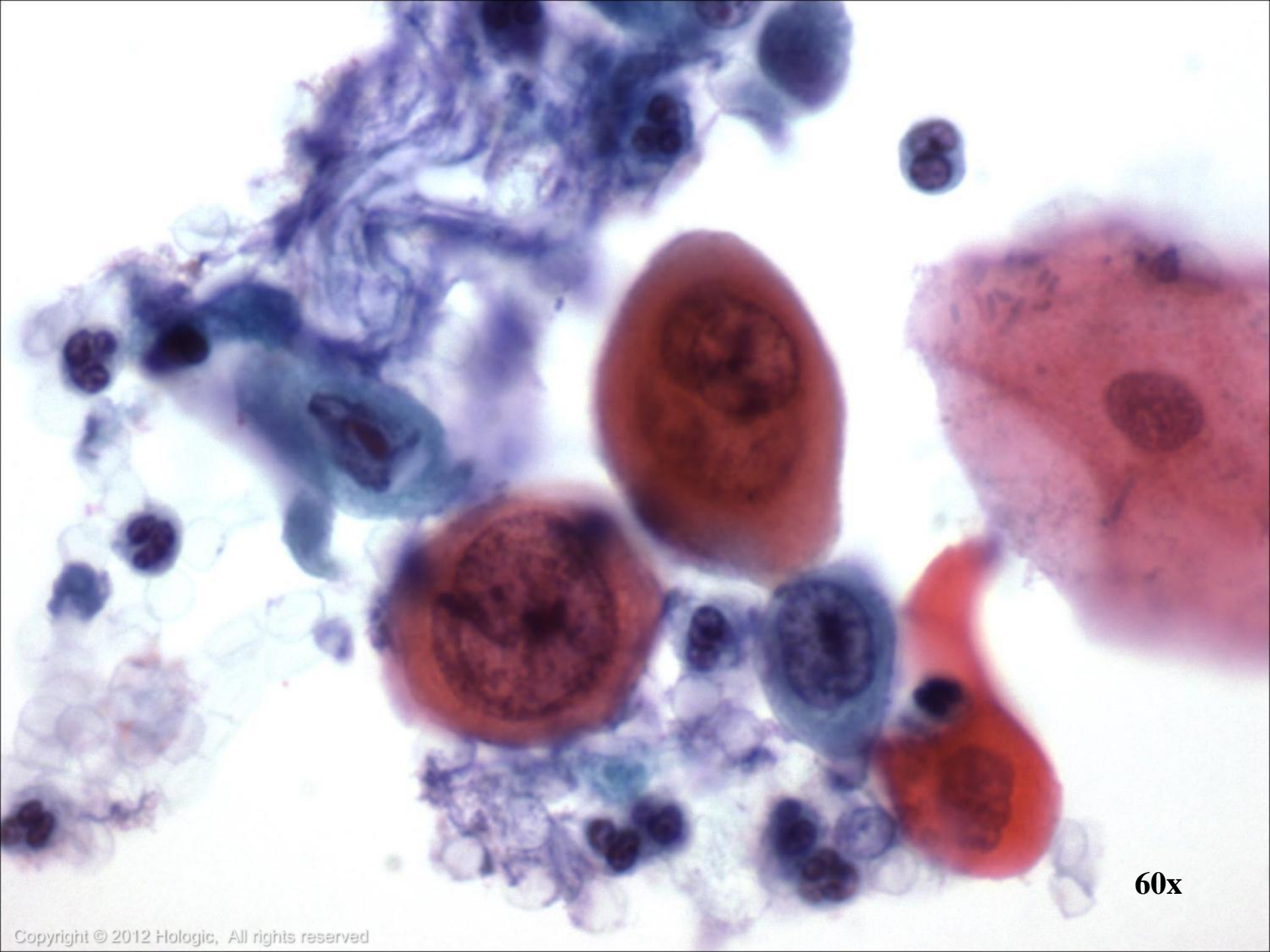
20x



60x



40x



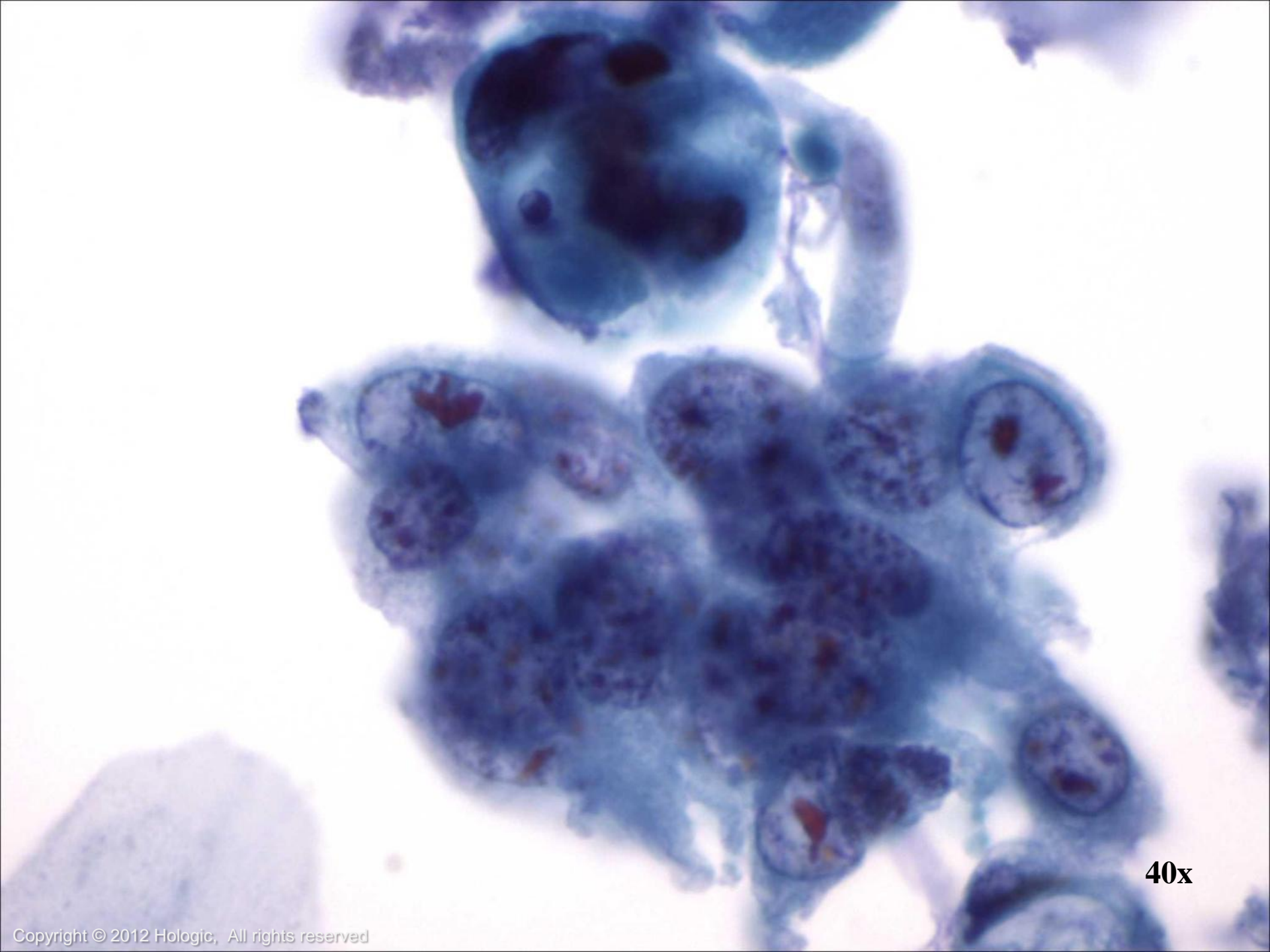
60x

Non-Keratinizing Squamous Cell Carcinoma

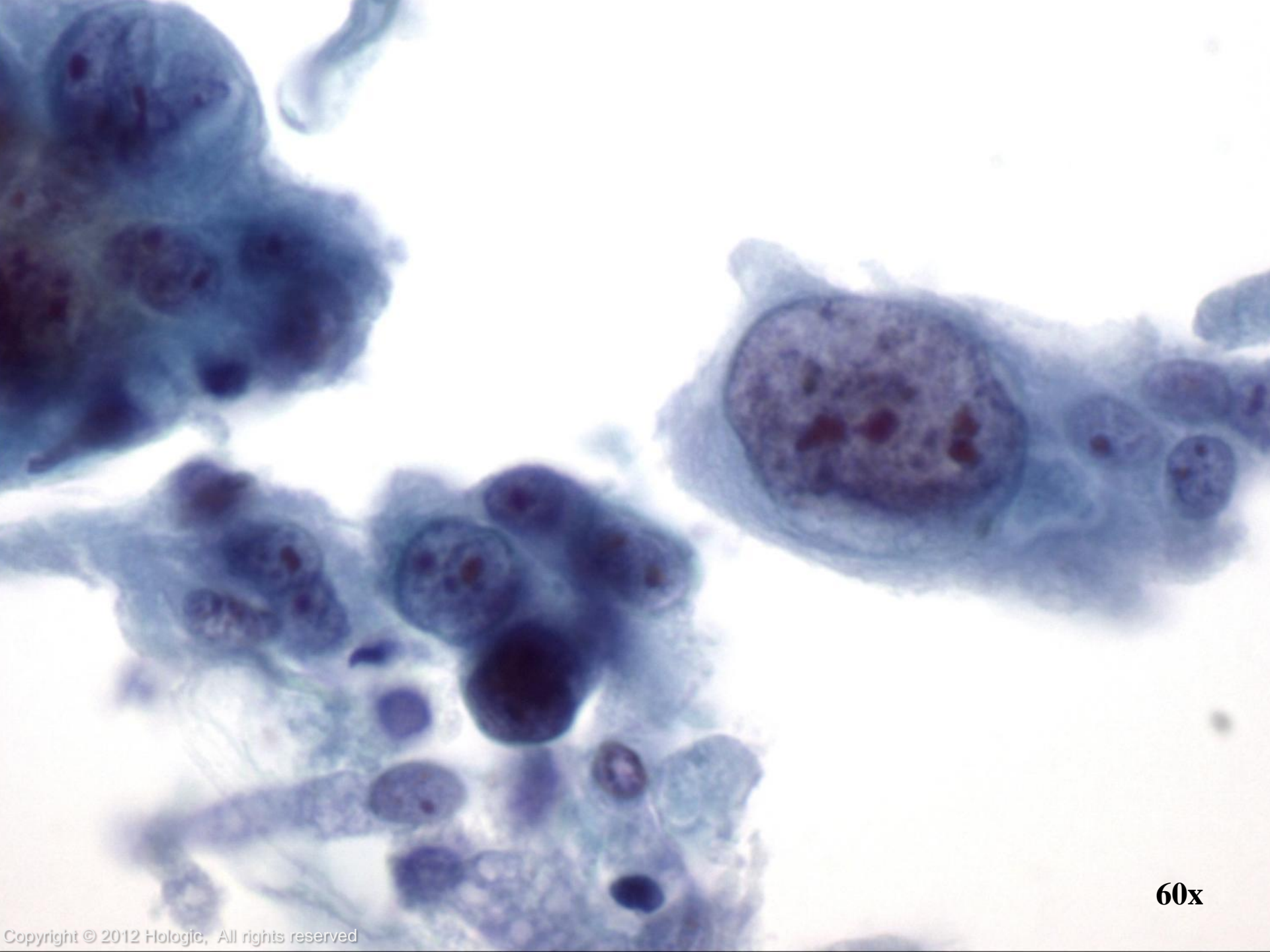
Cytologic features:

- Sheets and single cells, bizarre forms usually absent
- Nuclei are enlarged and hyperchromatic
- Chromatin is coarse and irregular but more open than Keratinizing Squamous Cell Carcinoma
- Nucleoli are usually prominent
- Cytoplasm is dense and often cyanophilic with distinct cell borders

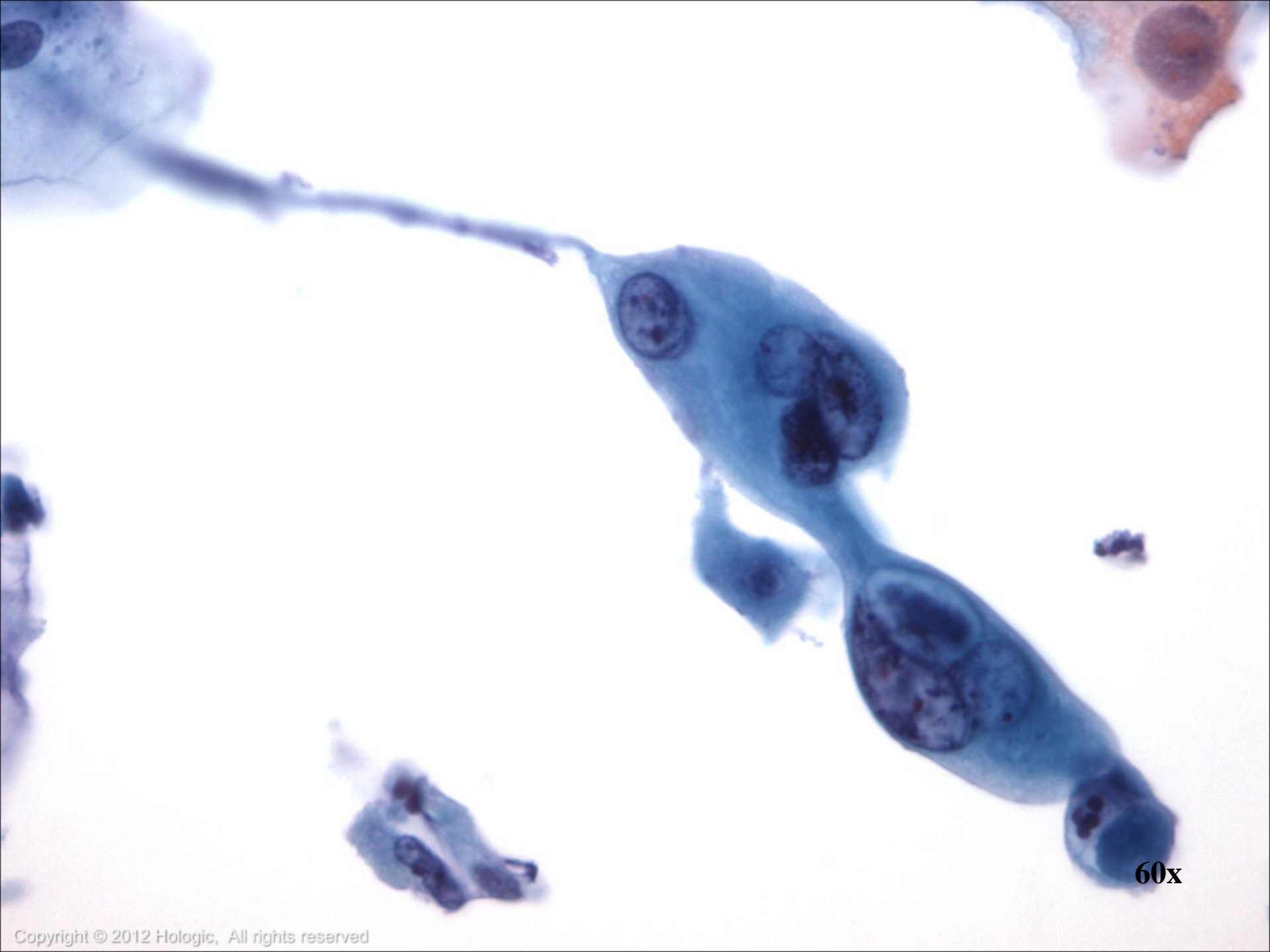




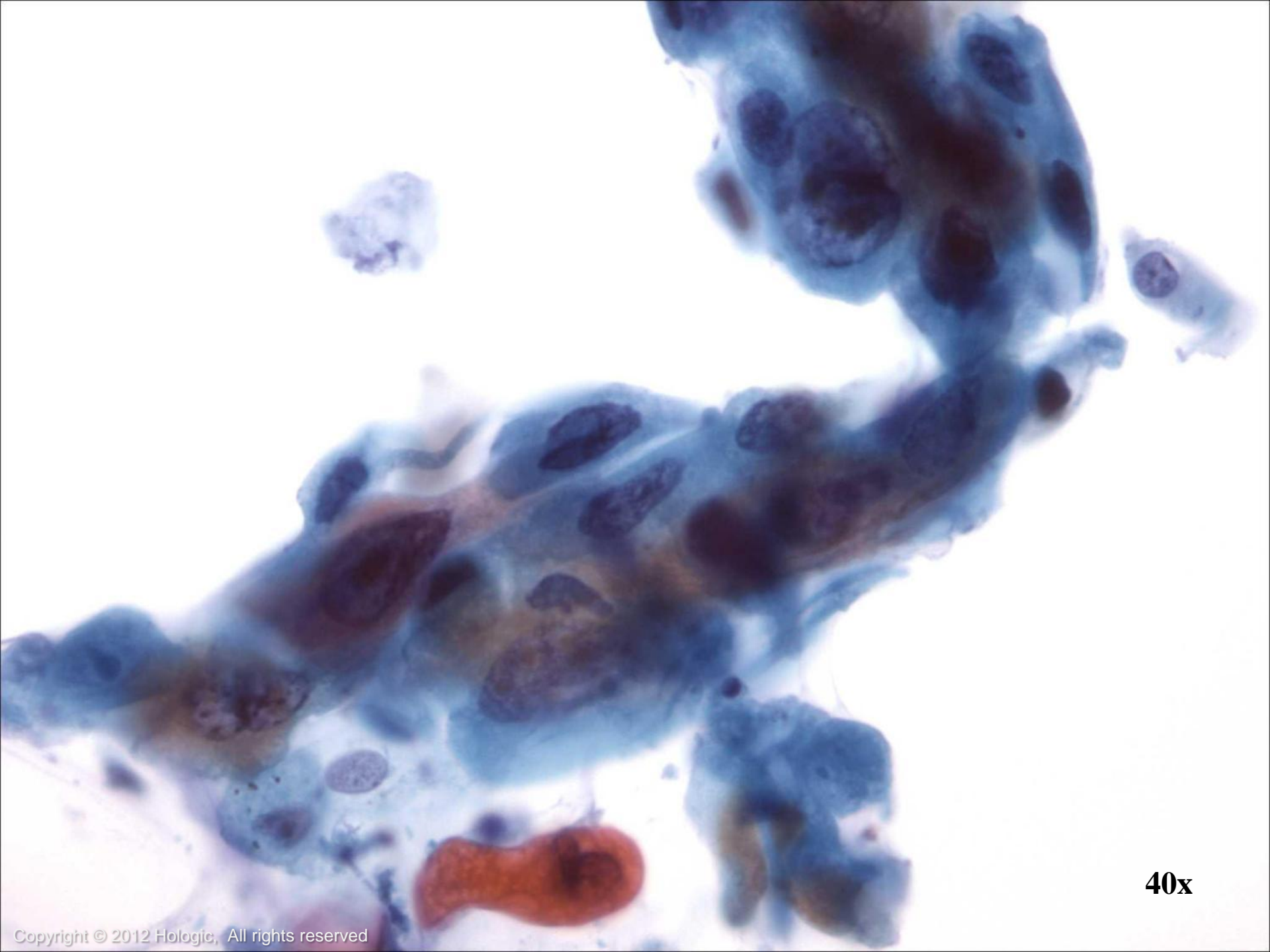
40x



60x

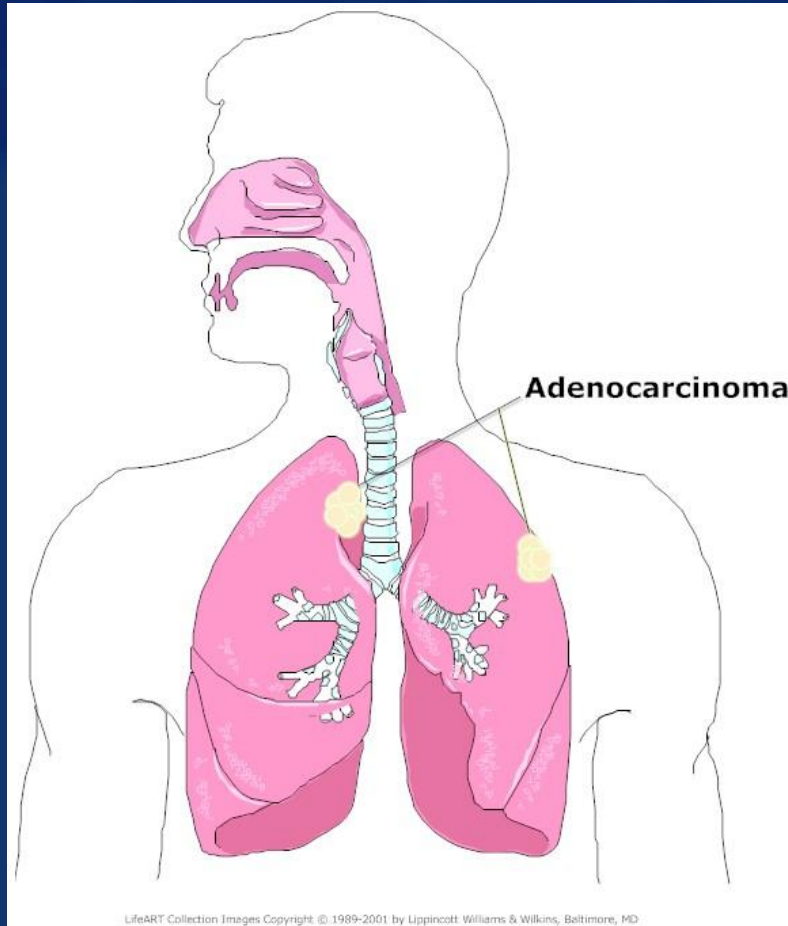


60x



40x

Adenocarcinoma



- Tumors tend to arise in the periphery of the lungs
- Two Types:
 - Bronchogenic Adenocarcinoma
 - Bronchioloalveolar Carcinoma (BAC)
- Detected more readily by bronchial cytology than by sputum cytology

Bronchogenic Adenocarcinoma

- Up to 30% of lung tumors
- 50% of all lung tumors in females
- Not always associated with smoking

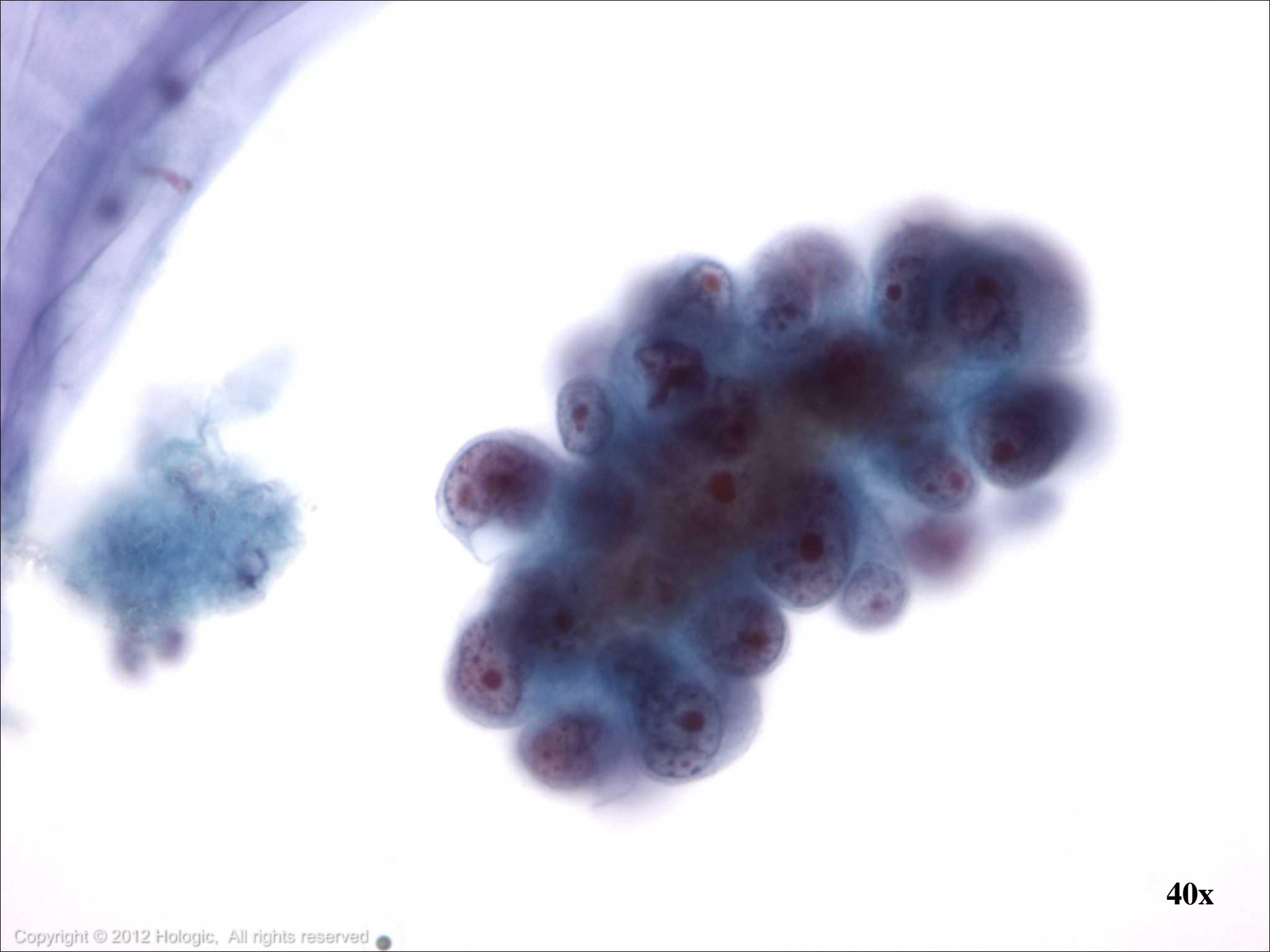


Bronchogenic Adenocarcinoma

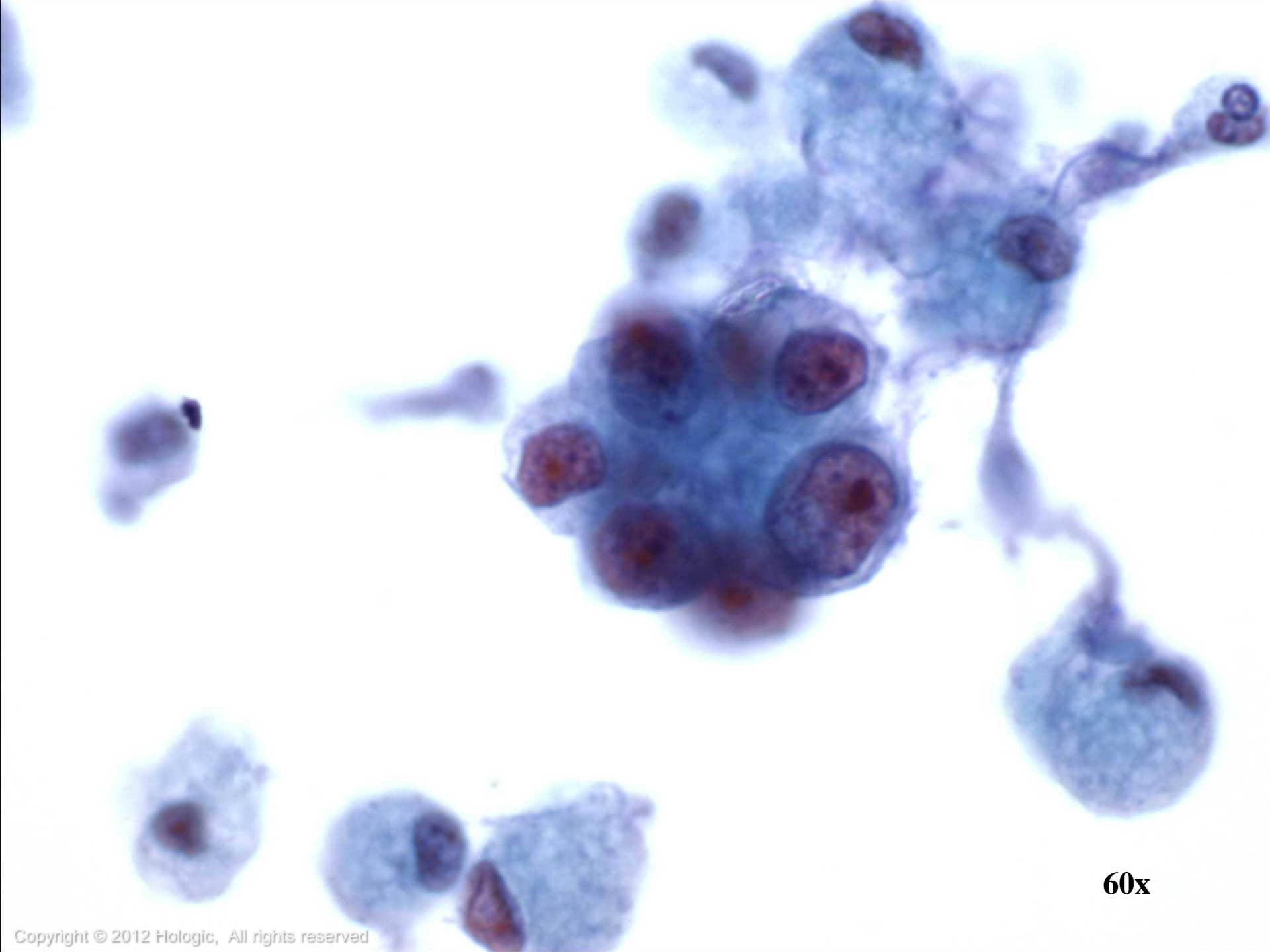
Cytologic features:

- Papillary, cell balls or acinar structures
- Nuclei are enlarged with irregular nuclear borders
- Chromatin ranges from fine to coarse
- Prominent macronucleoli
- Cytoplasm may range from homogenous to foamy

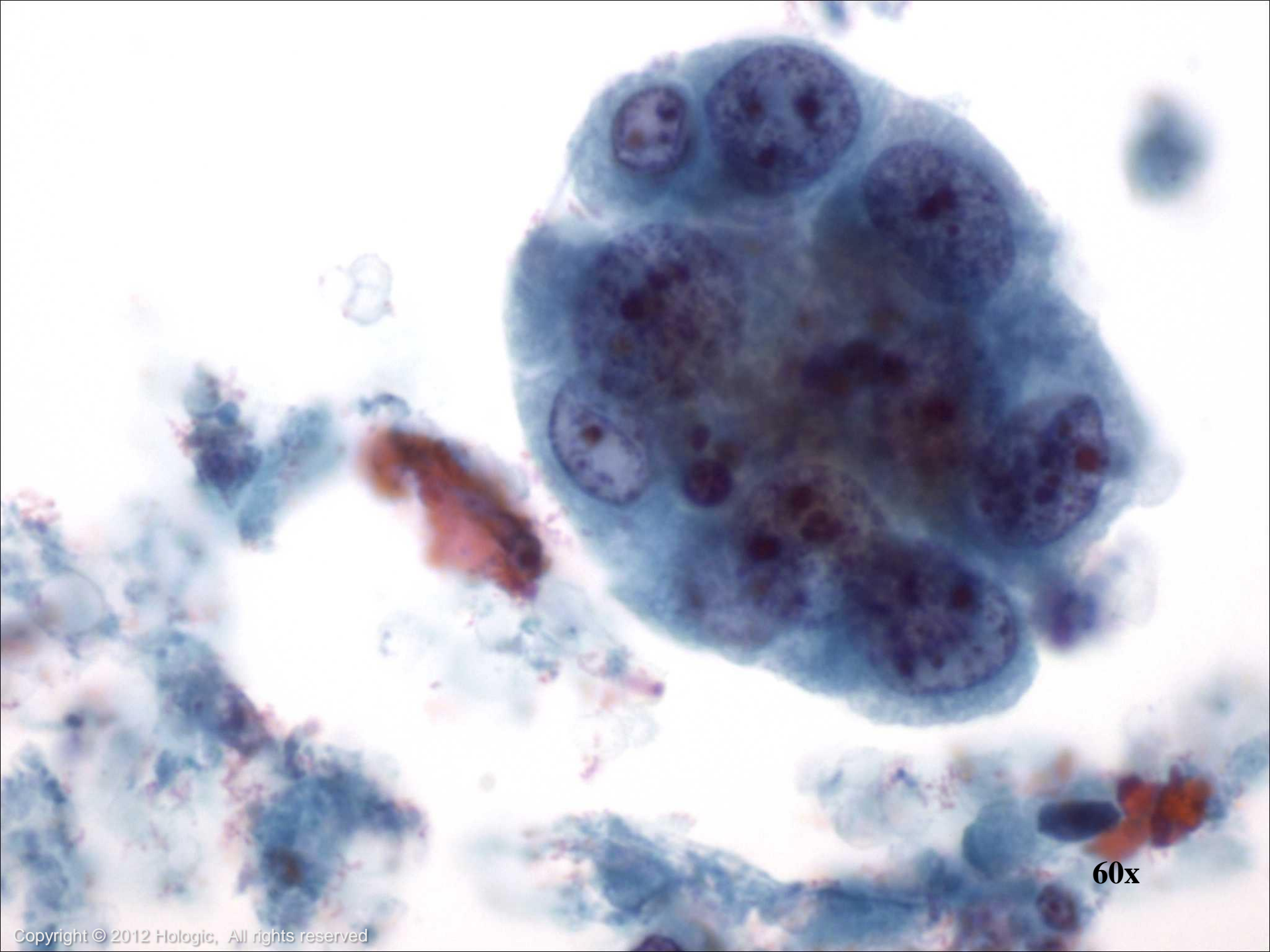




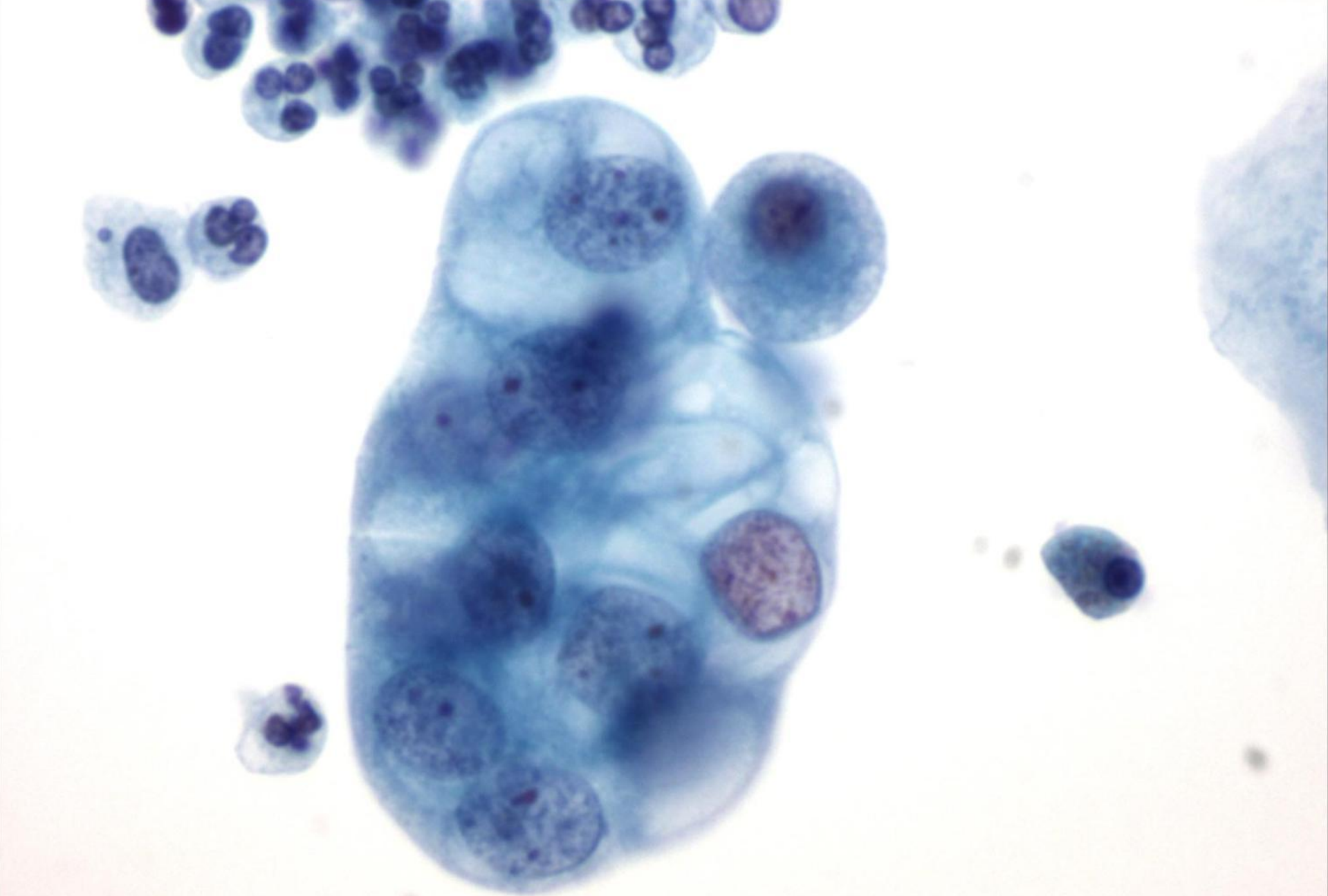
40x



60x



60x



60x

Bronchioloalveolar Carcinoma

- Peripheral lesion, rare in pure form
- 1% of lung tumors
- May arise from different cell types, including ciliated terminal bronchiolar cells, Clara cells, or type II alveolar pneumocytes
- More often well-differentiated
- Two types: mucinous or non-mucinous

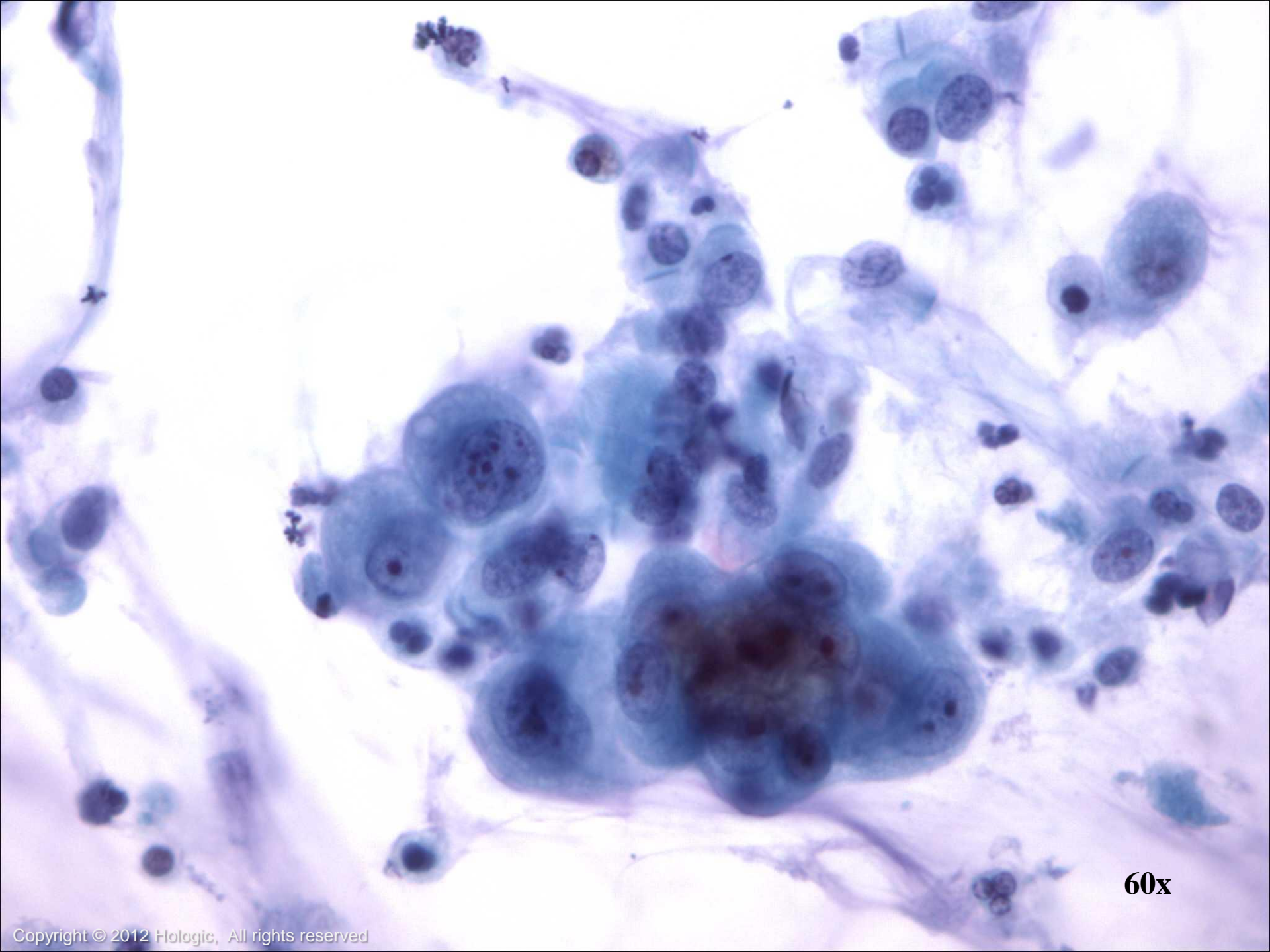


Bronchioloalveolar Carcinoma

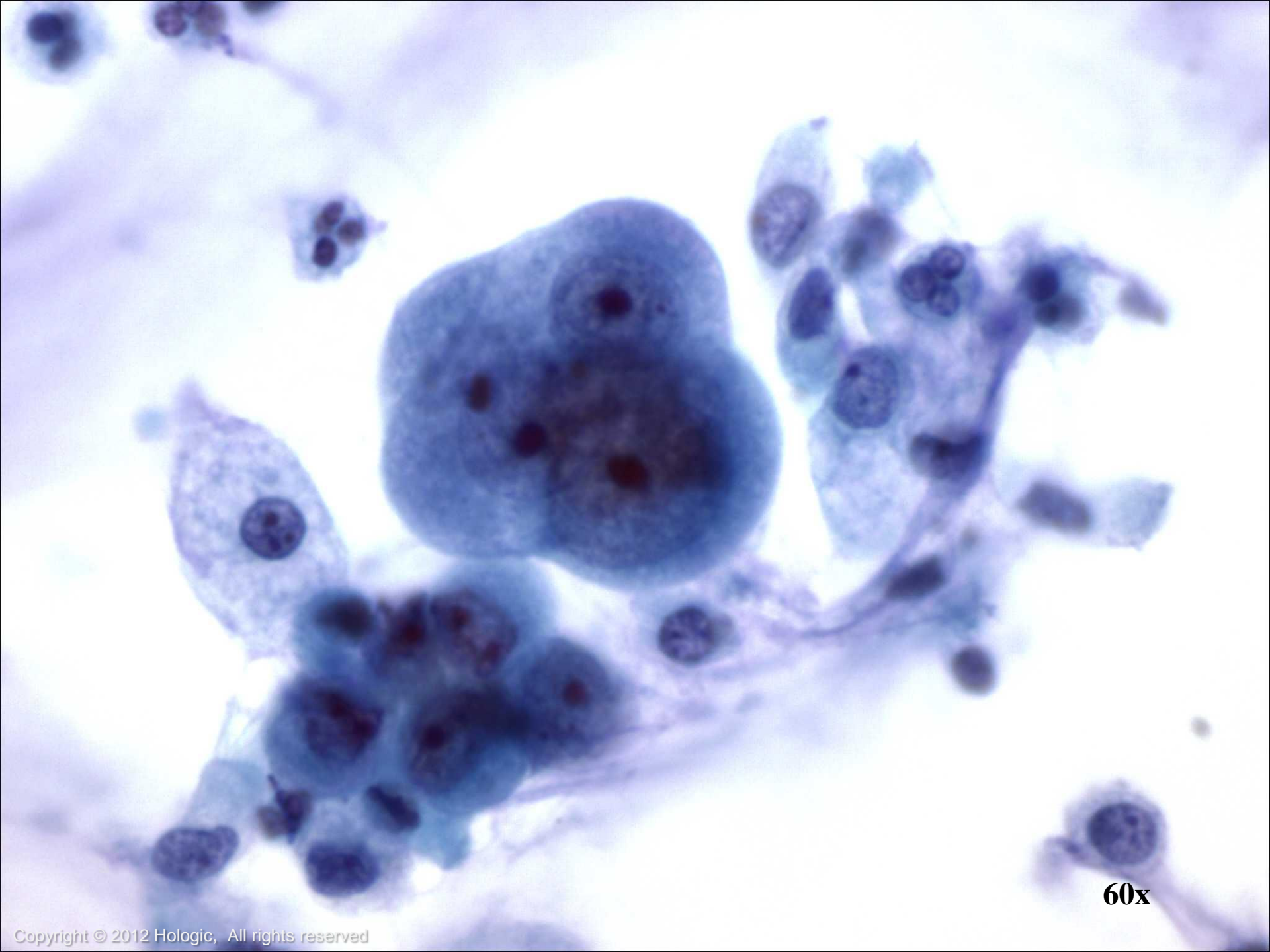Cytologic features:

- Sheets, cell balls with hobnail outlines, papillary groups, acini and single cells
- Nucleoli may be multiple, inconspicuous or prominent
- Chromatin is pale and fine but can be moderately hyperchromatic
- Cytoplasm varies from scant to abundant and finely granular to clear
- Mucus may be present in background

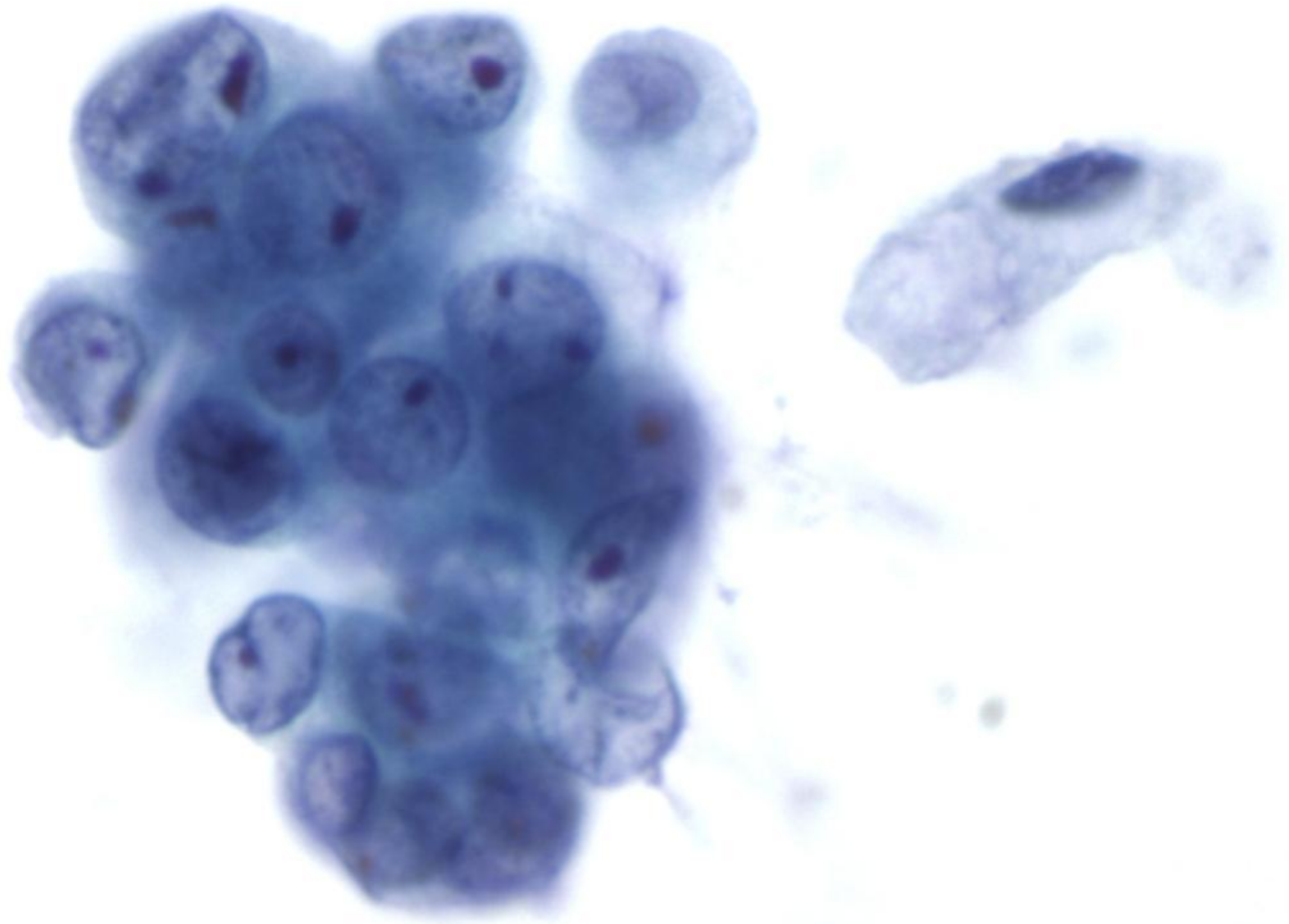




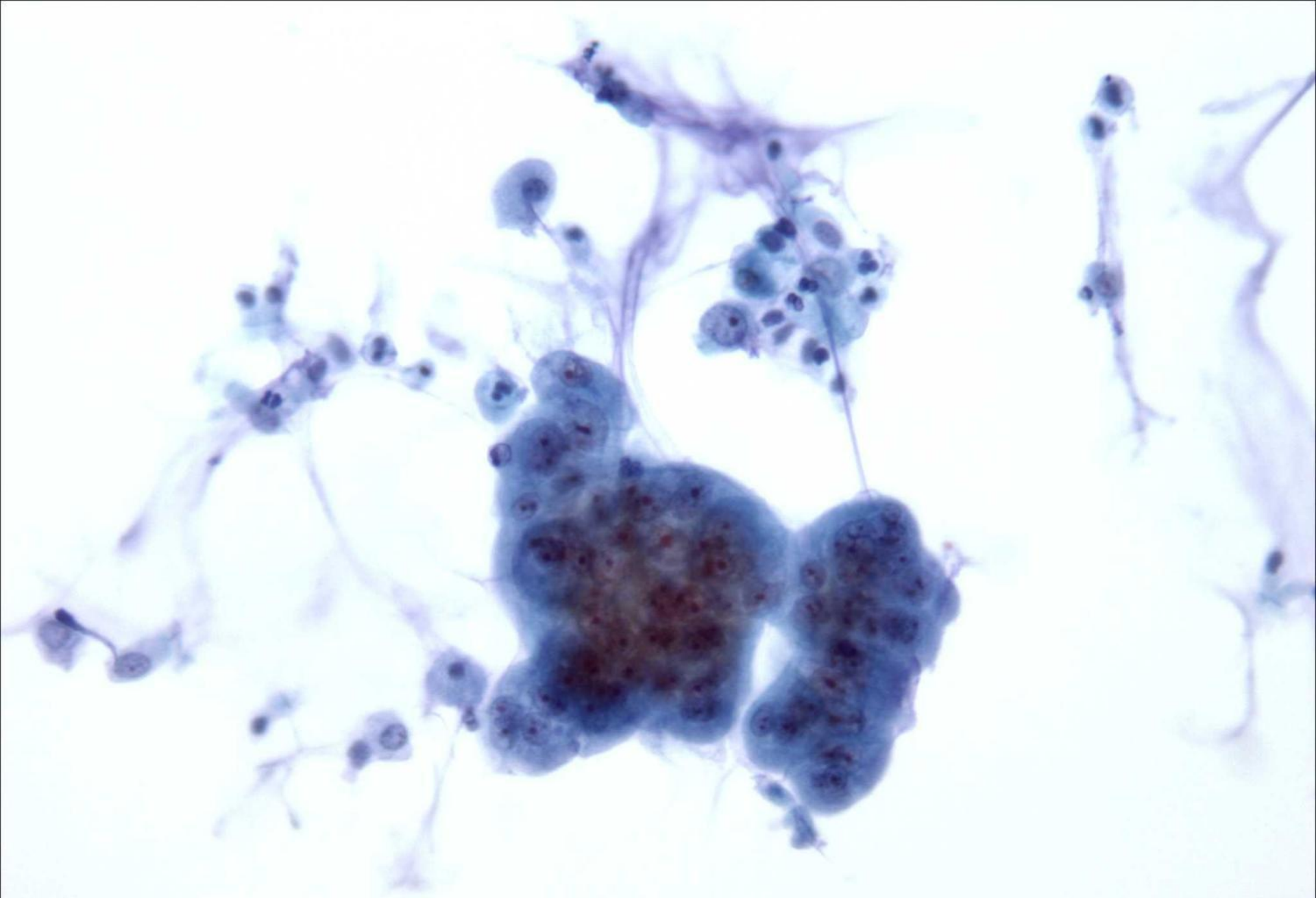
60x



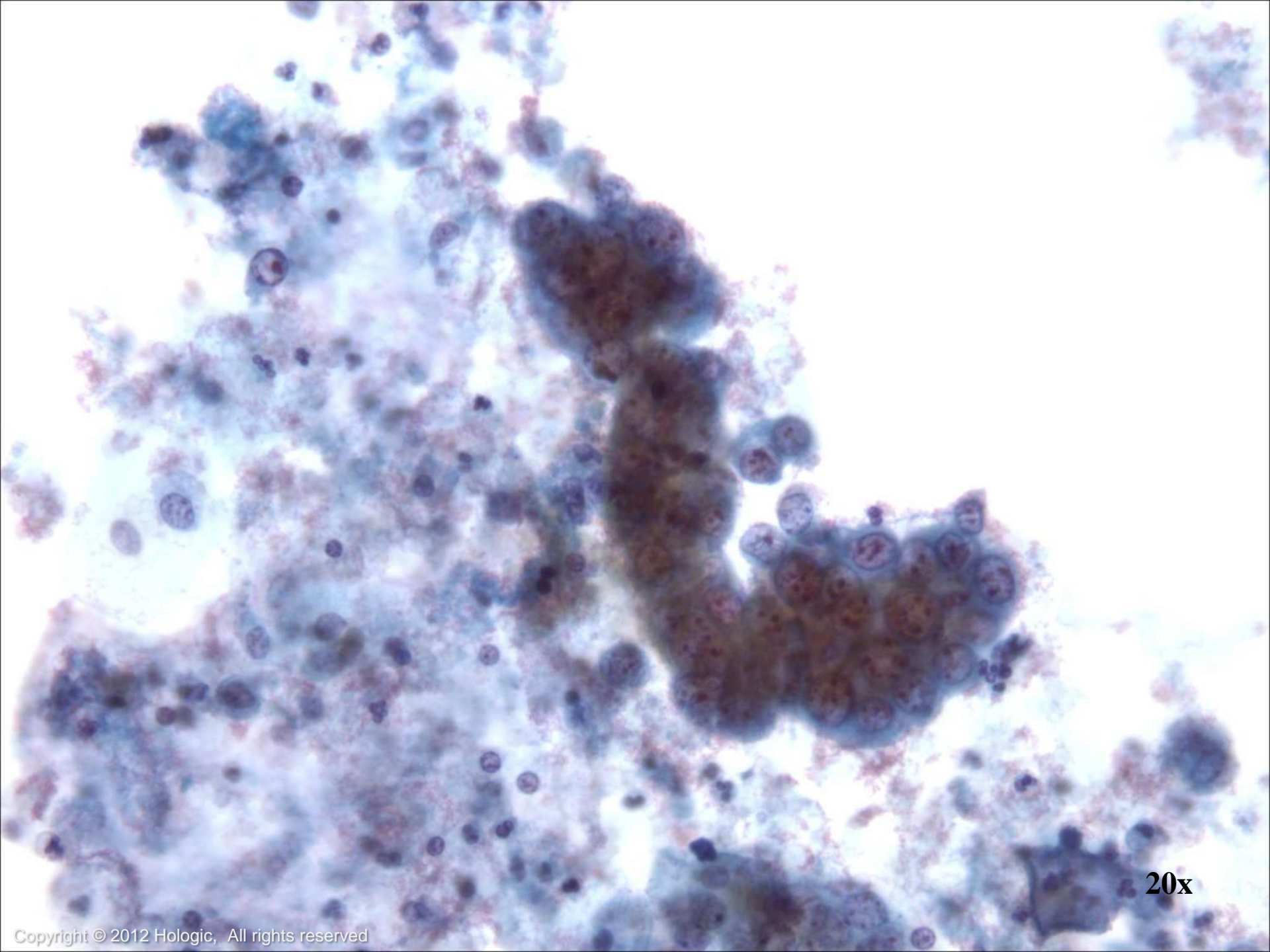
60x



60x



20x



20x

Pulmonary Neuroendocrine Neoplasms

- Divided by the World Health Organization into four distinct categories
 - Typical Carcinoid
 - Atypical Carcinoid
 - Large Cell Undifferentiated Carcinoma
 - Small Cell Undifferentiated Carcinoma



Typical Carcinoid

- Accounts for 2-3% of all pulmonary tumors
- Low metastatic rate, 5-year survival: 90-98%

Cytologic features:

- Loosely cohesive groups and single cells
- Cells are round, oval or elongated
- Nuclei are uniform with “salt and pepper” chromatin
- Inconspicuous nucleoli
- Moderate to abundant granular cytoplasm
- Mitoses is uncommon
- Necrosis is absent



Atypical Carcinoid

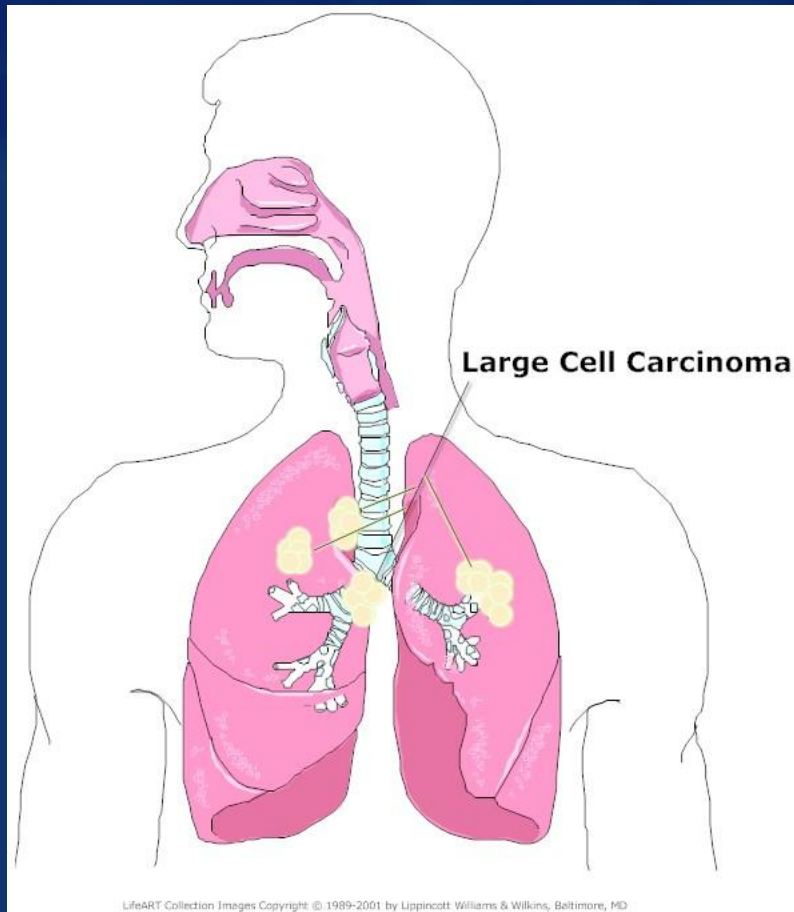
- More aggressive than Typical Carcinoid
- 5-year survival rate: 61-73%
- Cells and architecture similar to Typical Carcinoid

Cytologic differences from Typical Carcinoid:

- Focal necrosis
- Mitoses are moderate in number
- Prominent nucleoli



Large Cell Undifferentiated Carcinoma



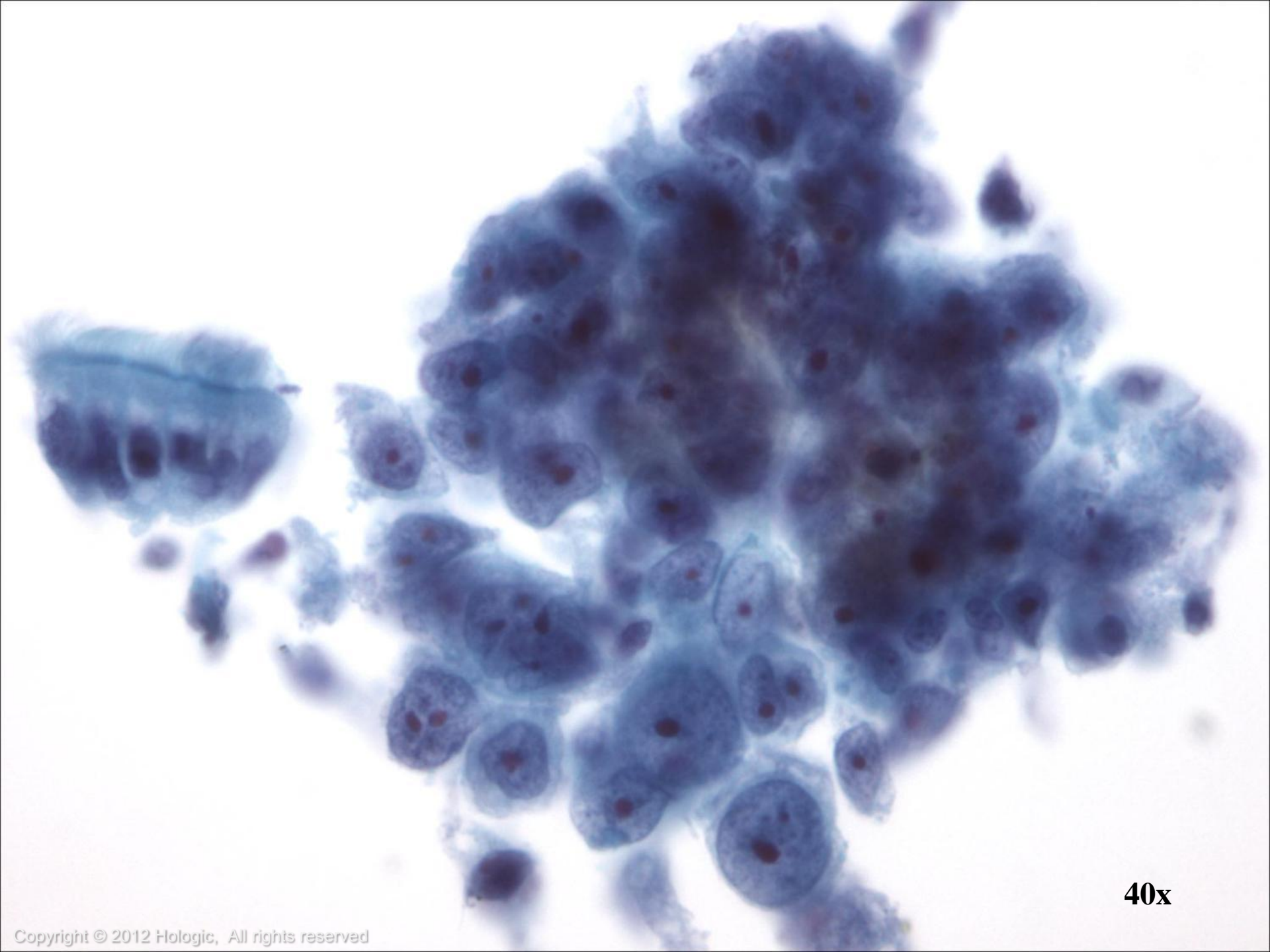
- Non-small cell tumor, no definite differentiation
- Readily exfoliates
- May have squamous or glandular features, or both (*commonly demonstrable by using electron microscope or immunocytochemistry*)

Large Cell Undifferentiated Carcinoma

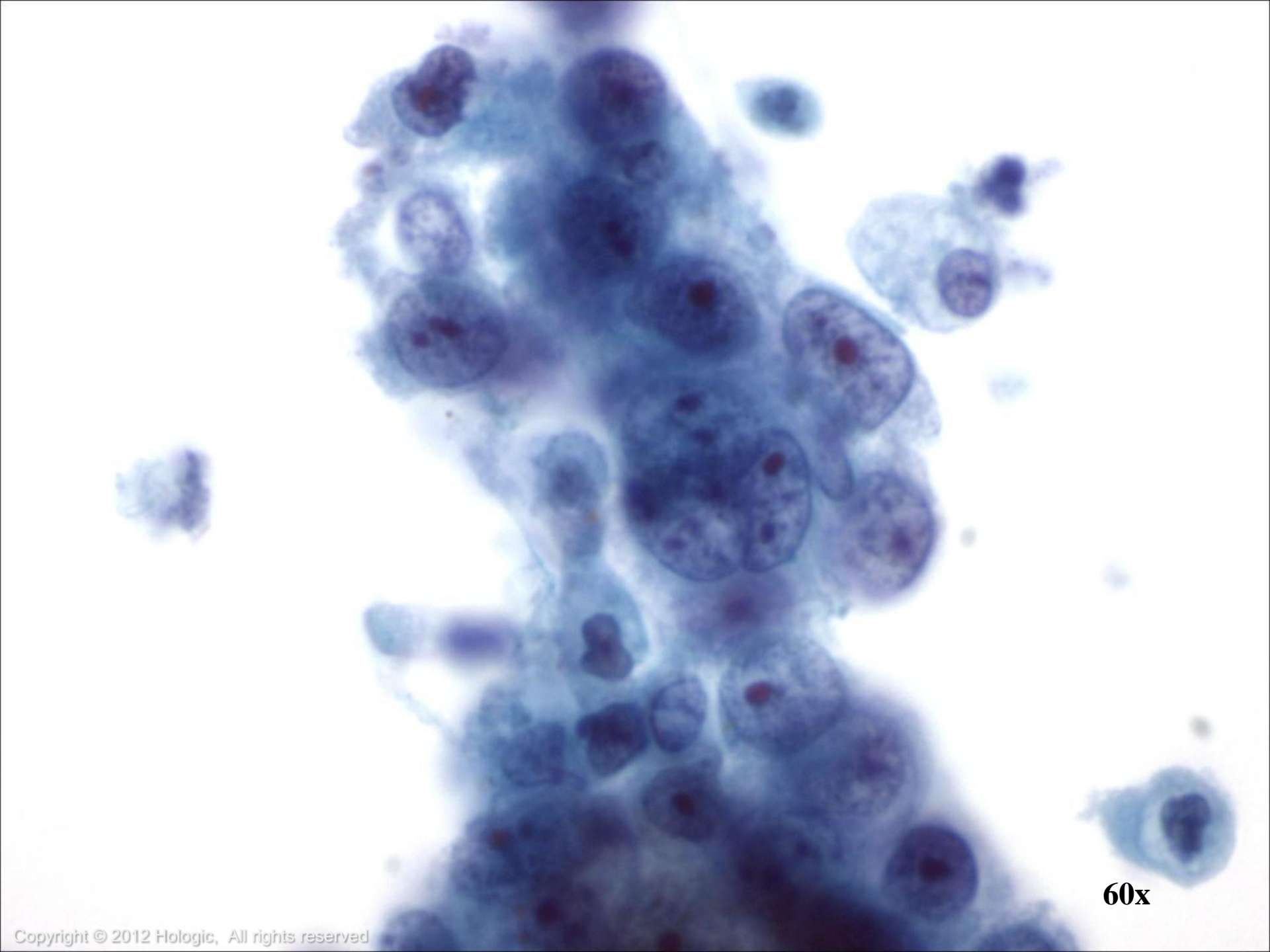
Cytologic features:

- Large malignant cells ranging from fairly uniform to bizarre
- Nuclei are large and round to pleomorphic with irregular to lobulated membranes
- Chromatin is fine to coarse and irregularly distributed
- Nucleoli can be prominent, multiple and irregular
- Cytoplasm is abundant and varies from delicate to dense to granular
- Diathesis is usually present

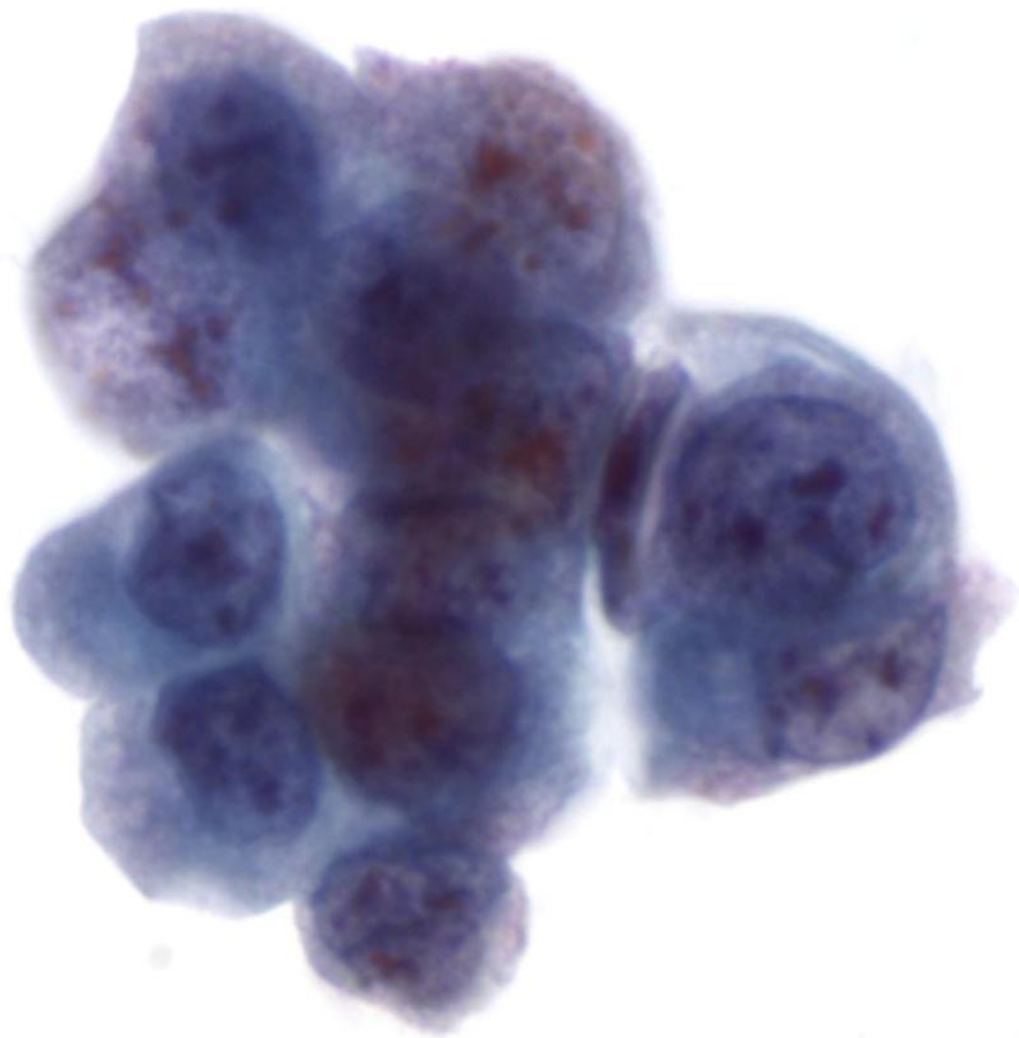




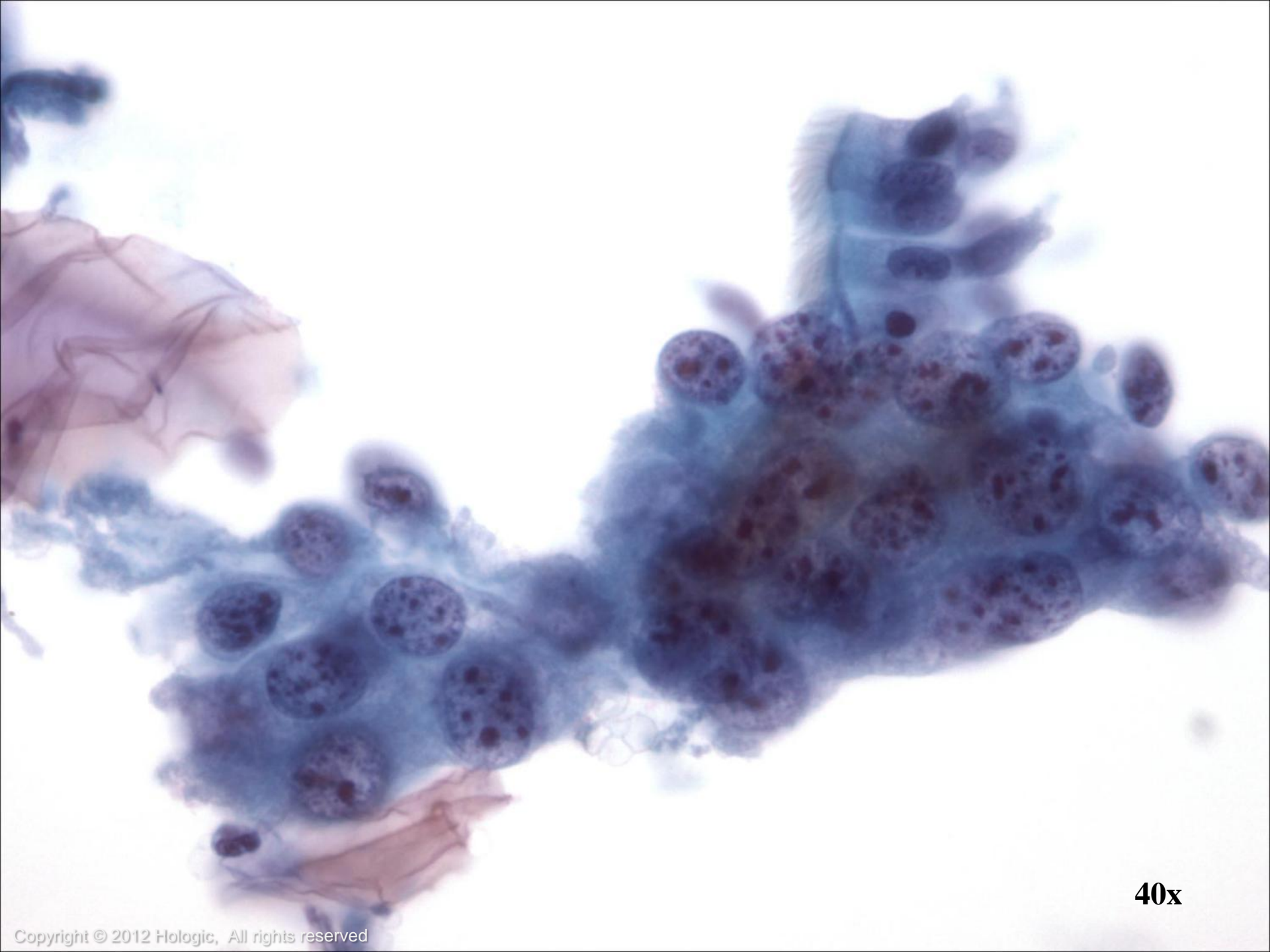40x



60x

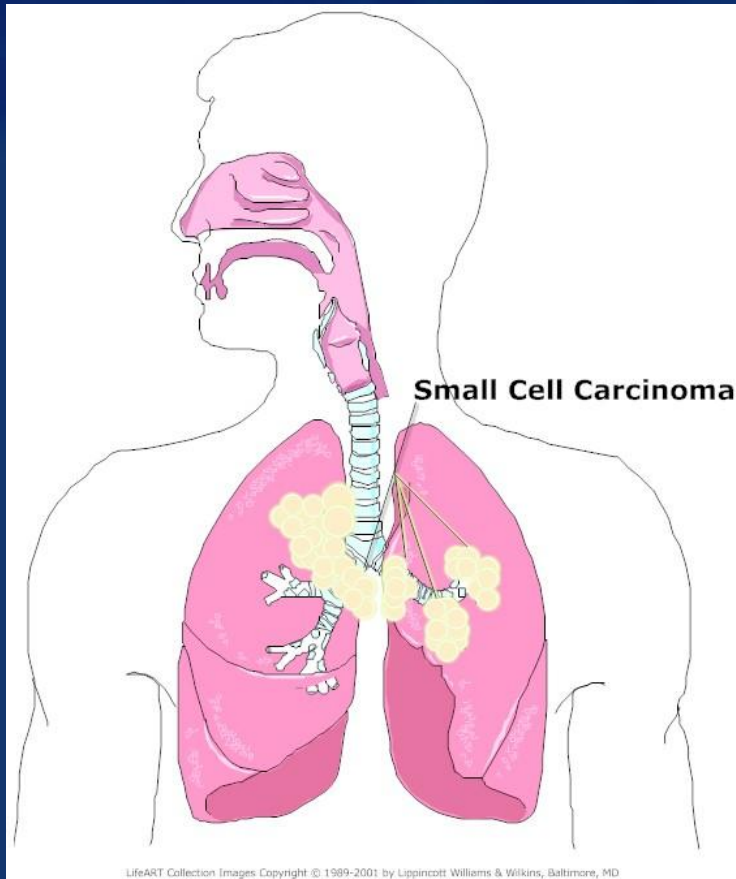


60x



40x

Small Cell Undifferentiated Carcinoma



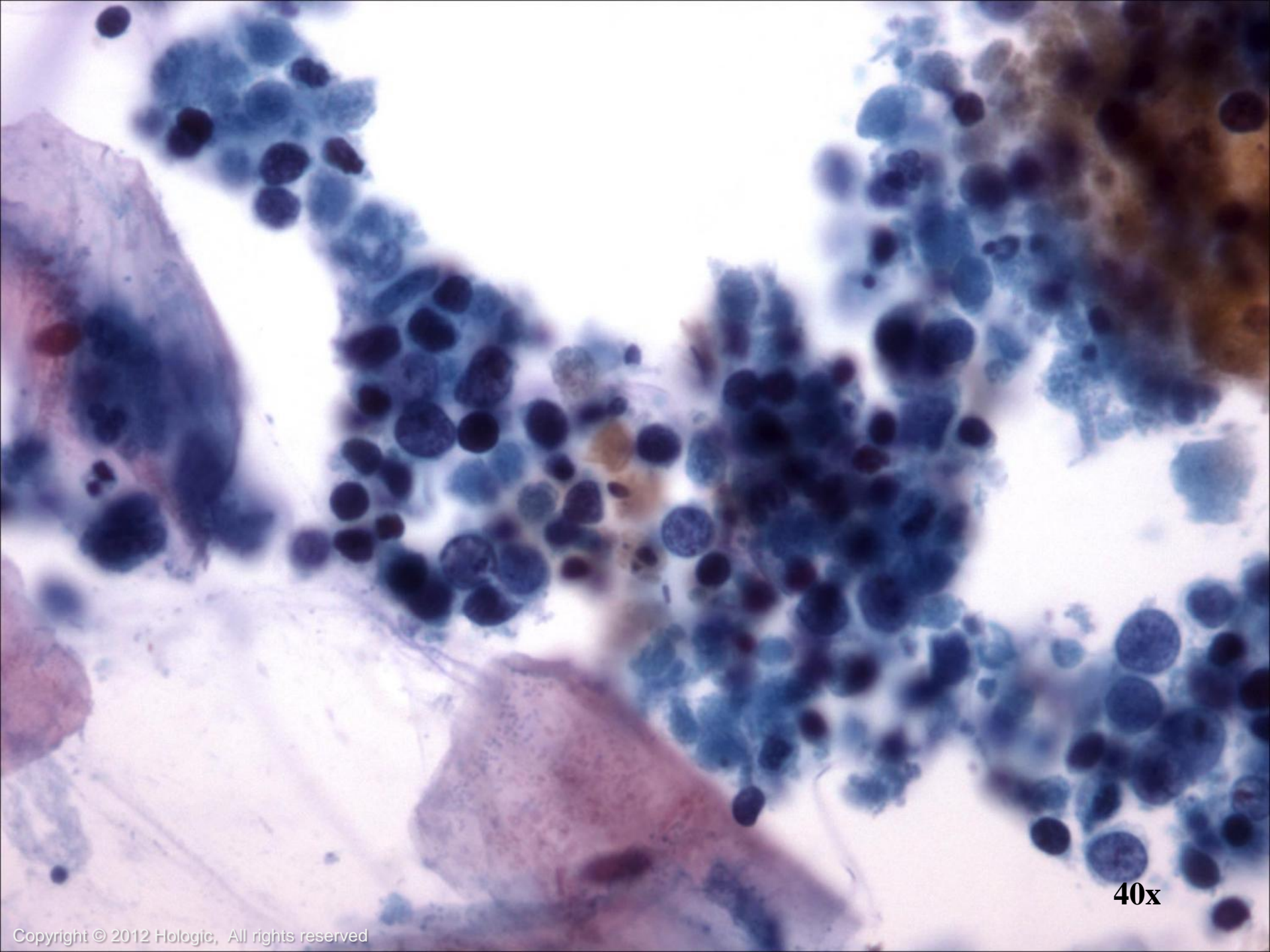
- Aggressive tumor
- Arises in the major bronchi
- Central tumor
- Derived from or mimics Kulchitsky cells
- Capable of producing a variety of hormones

Small Cell Undifferentiated Carcinoma

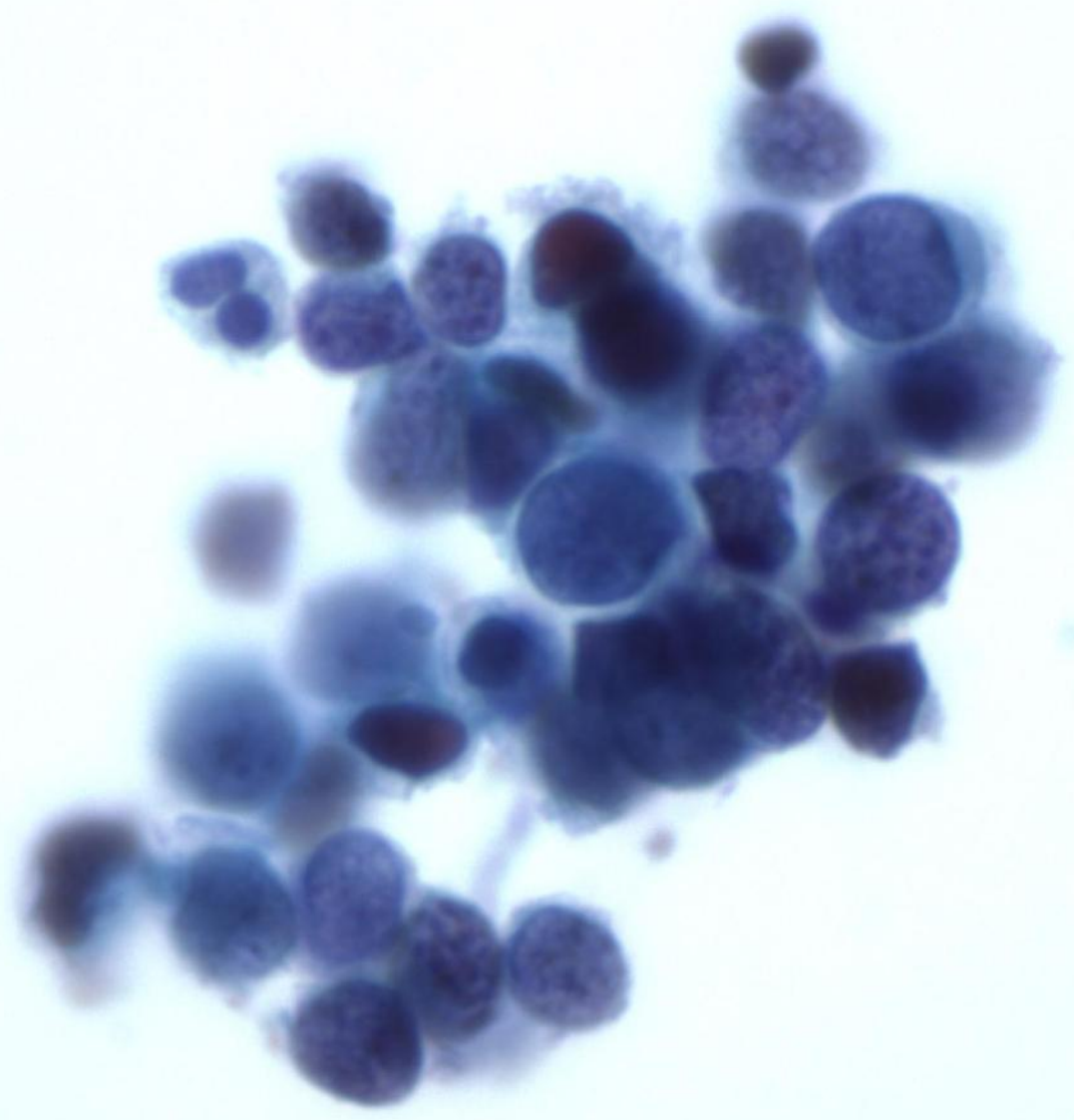
Cytologic features:

- Small, 1-4x size of lymphocytes
- Nuclear molding is prominent
- Nuclei are hyperchromatic to pyknotic
- Nucleoli are inconspicuous
- Cytoplasm is scant and delicate
- Presence of diathesis and crush artifact

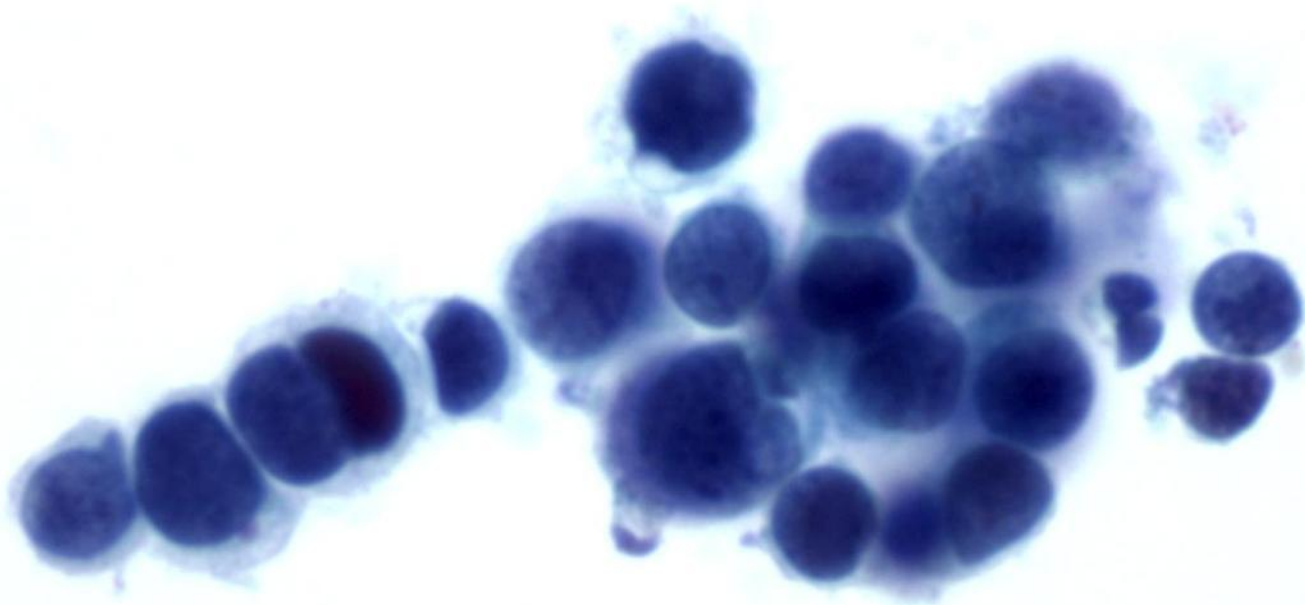




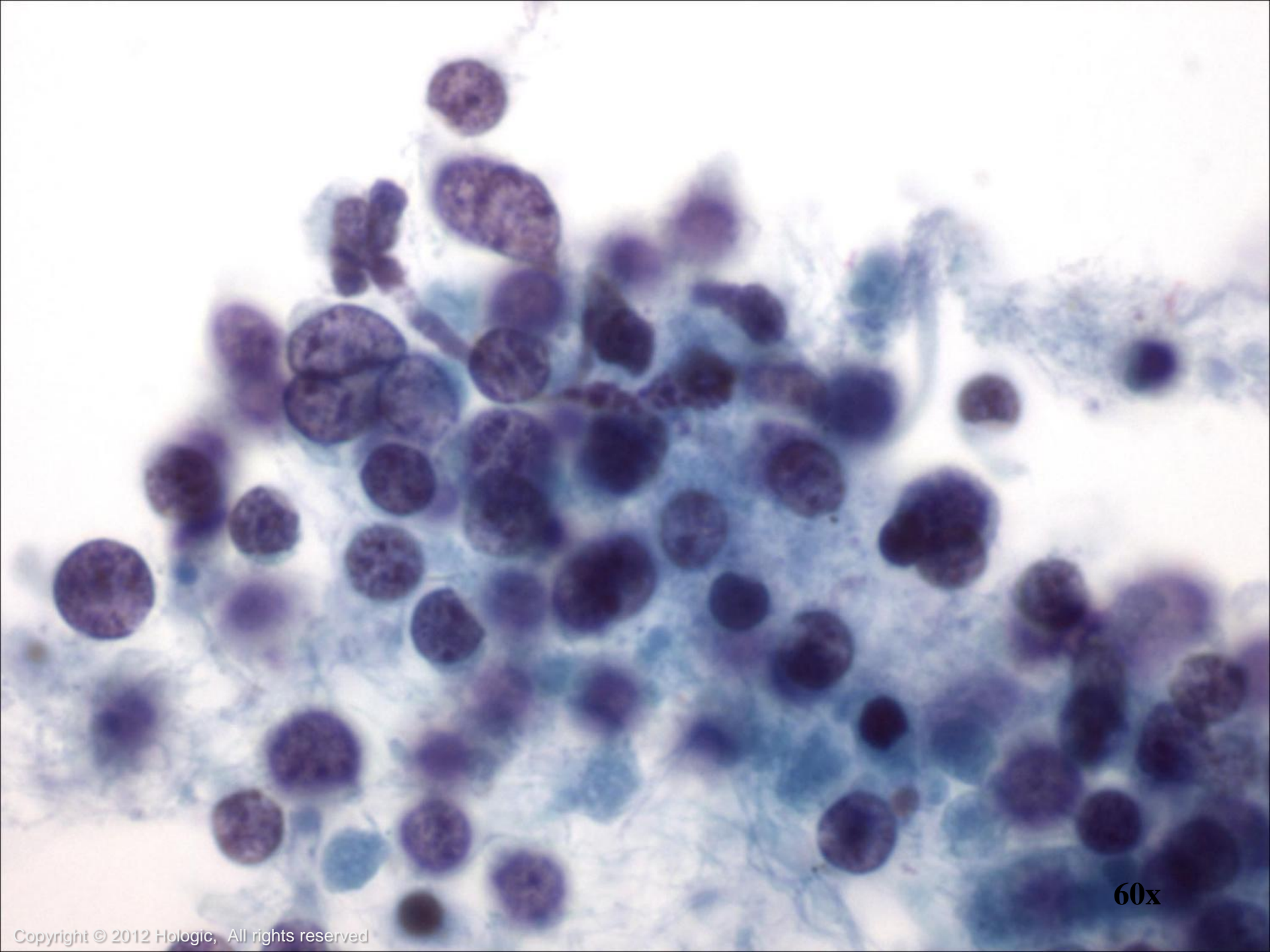
40x



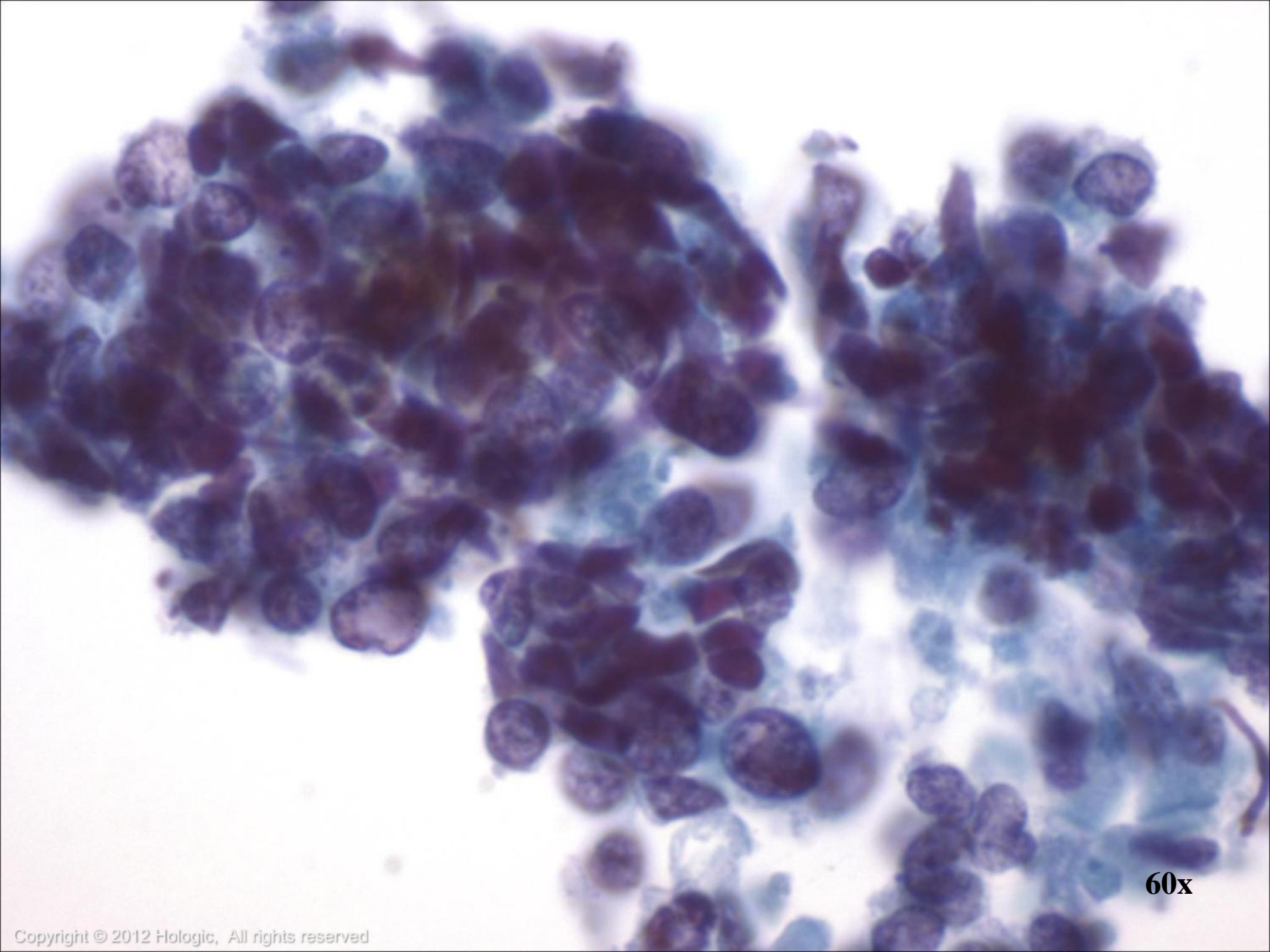
60x



60x



60x



60x

Uncommon Pulmonary Tumors

- Adenoid Cystic Carcinoma
- Mucoepidermoid Carcinoma
- Clear Cell Tumor (“Sugar Tumor”)
- Sarcomas
- Lymphomas/Leukemias



Adenoid Cystic Carcinoma

- Account for 20-30% of all cancers in the trachea but also occur in the bronchi
- Symptoms include: cough, dyspnea and hemoptysis
- Poor long-term prognosis
- Most often diagnosed by bronchial brushings or transbronchial needle aspiration

Cytologic features:



- Cylinders or spheres of small, benign-appearing epithelial cells that surround basal lamina material

Mucoepidermoid Carcinoma

- Uncommon, representing only 0.2% of lung tumors
- Develop in persons of all ages, including children
- A recurrent and tumor specific genetic aberration is present: t (11; 19), forming the MECT1-MAML2 fusion transcription

Cytologic features:

- Presence of squamous, intermediate and mucinous cells
- High-grade tumors show marked nuclear atypia



Clear Cell Tumor (“Sugar Tumor”)

- Extremely rare, can occur in persons of all ages
- Typically presents as a peripheral mass ranging from 1 to 7 cm in greatest diameter

Cytologic features:

- Bland polygonal and spindle-shaped cells with a central oval or elongated nucleus
- Cytoplasm is clear and glycogenated

Differentials include: clear cell variant of adenocarcinoma or Squamous Cell of the lung, granular cell tumor, and metastatic tumors with clear-cell features



Sarcomas

- Primary malignant mesenchymal tumors of the lung are rare
- Occur in adults of either sex
- One of the most common primary sarcomas is leiomyosarcoma
- Can be large masses or small endobronchial lesions

Cytologic features:



- Sheet-like cellular aggregates
- Malignant spindle cells are single and highly atypical

Lymphomas

- Primary Hodgkin and non-Hodgkin lymphomas can occur but metastatic lymphomas are more common
- Primary pulmonary non-Hodgkin lymphoma represents less than 10% of all extranodal lymphomas
- Most common primary non-Hodgkin lymphoma of the lung (70-90%) is MALT lymphoma, followed by diffuse large B-cell lymphoma



Primary pulmonary Hodgkin lymphoma is exceptionally rare

- Cytologic features of Hodgkin and non-Hodgkin lymphomas are similar to those seen in other body sites

Leukemias

- 10% of diffuse pulmonary infiltrates in patients with leukemia result from leukemic involvement of the lung
- Leukemic involvement of the lung may present as a mass

Cytologic features:

- Cells are dispersed as isolated cells, as with lymphomas, and cellular monomorphism is characteristic

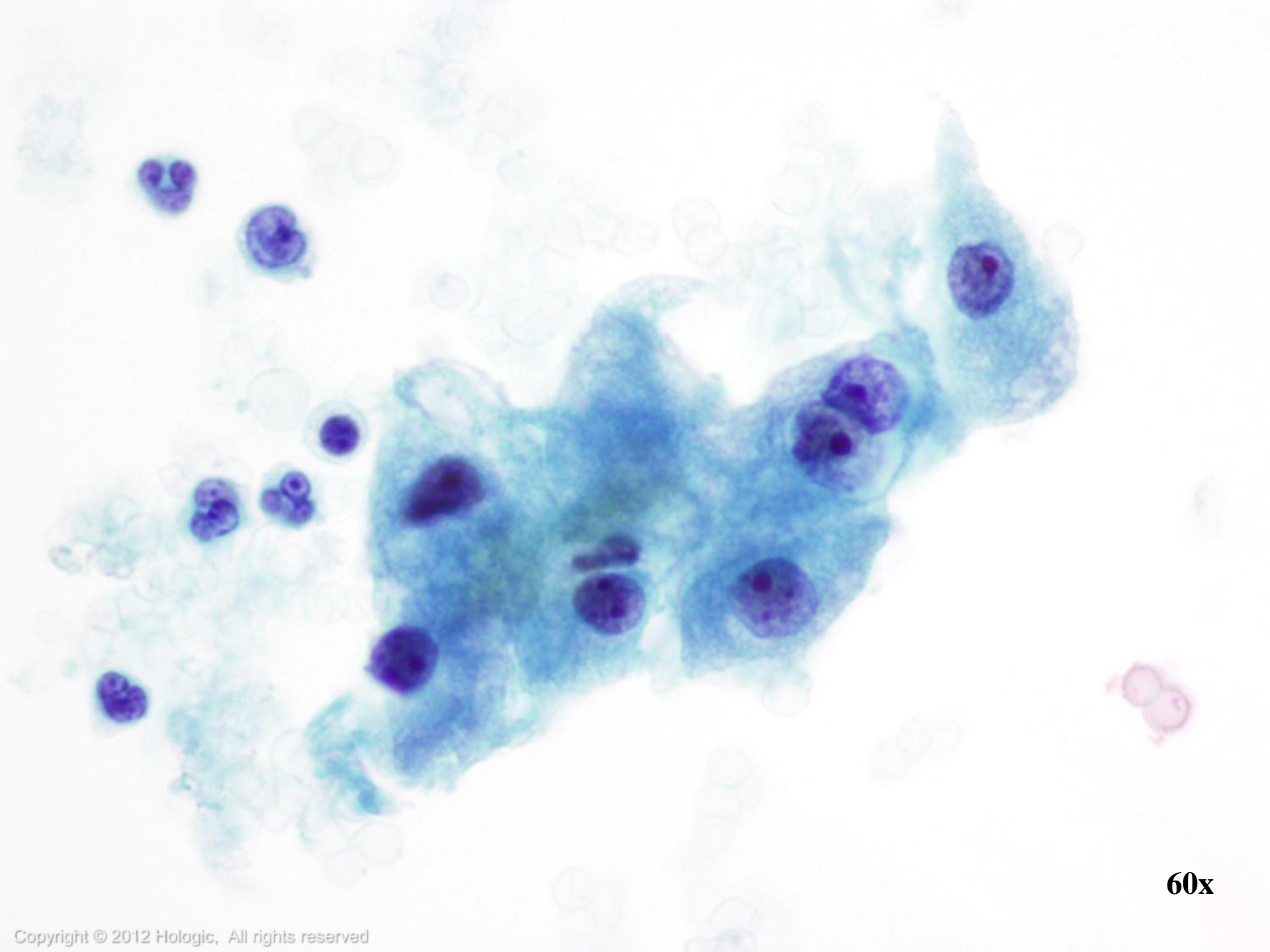
- BAL is useful for demonstrating leukemic involvement, especially when biopsy is contraindicated because of coagulopathy



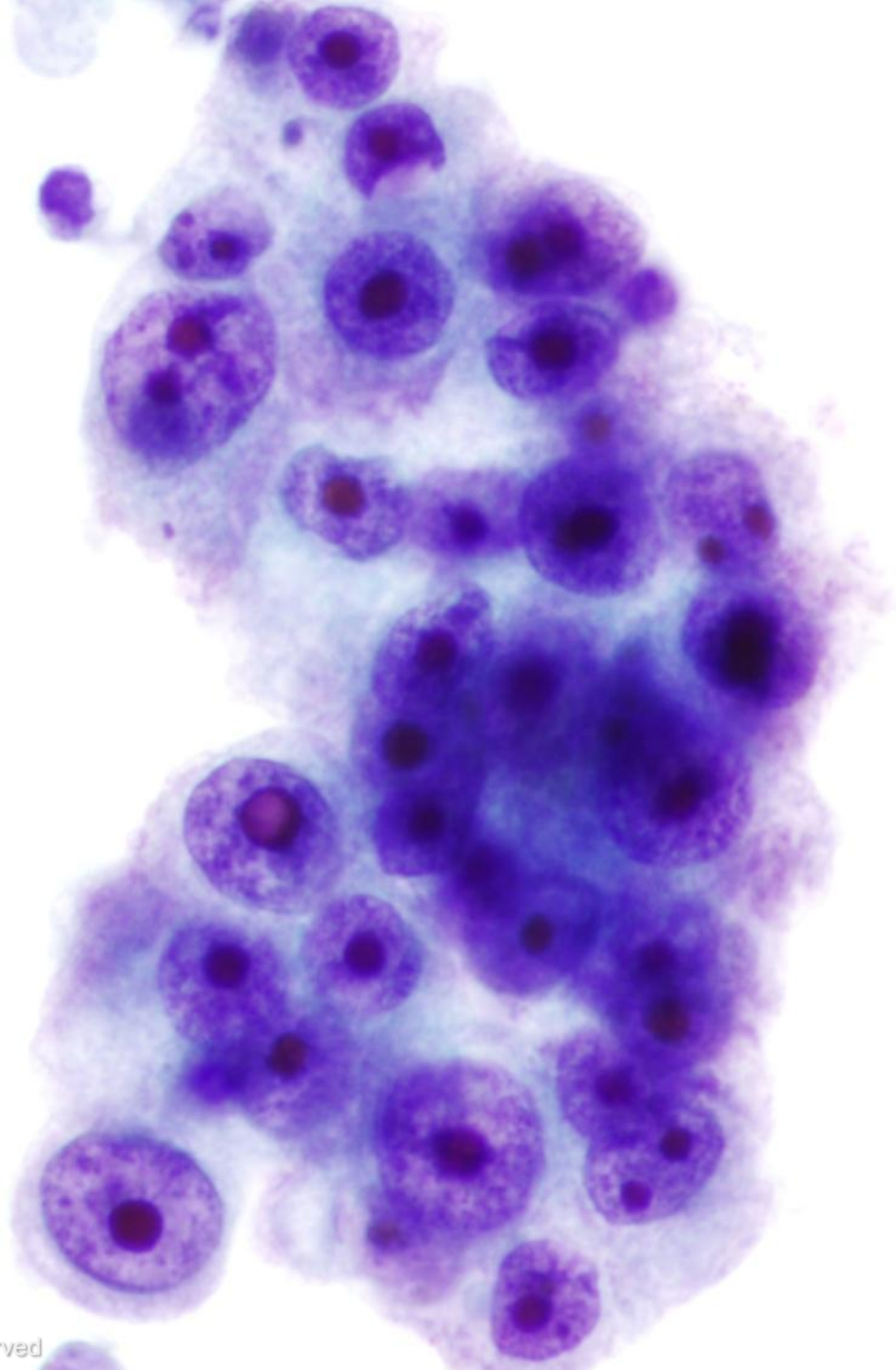
Metastatic Disease

- Three times more common than primary Adenocarcinoma of the lung
- Most common sites of origin are GI, Breast, Lymphoma/Leukemia, Melanoma and Sarcoma
- Multiple nodules favor metastatic disease
- In addition to clinical history, cytomorphologic features and immunochemistry studies may help determine primary tumor site

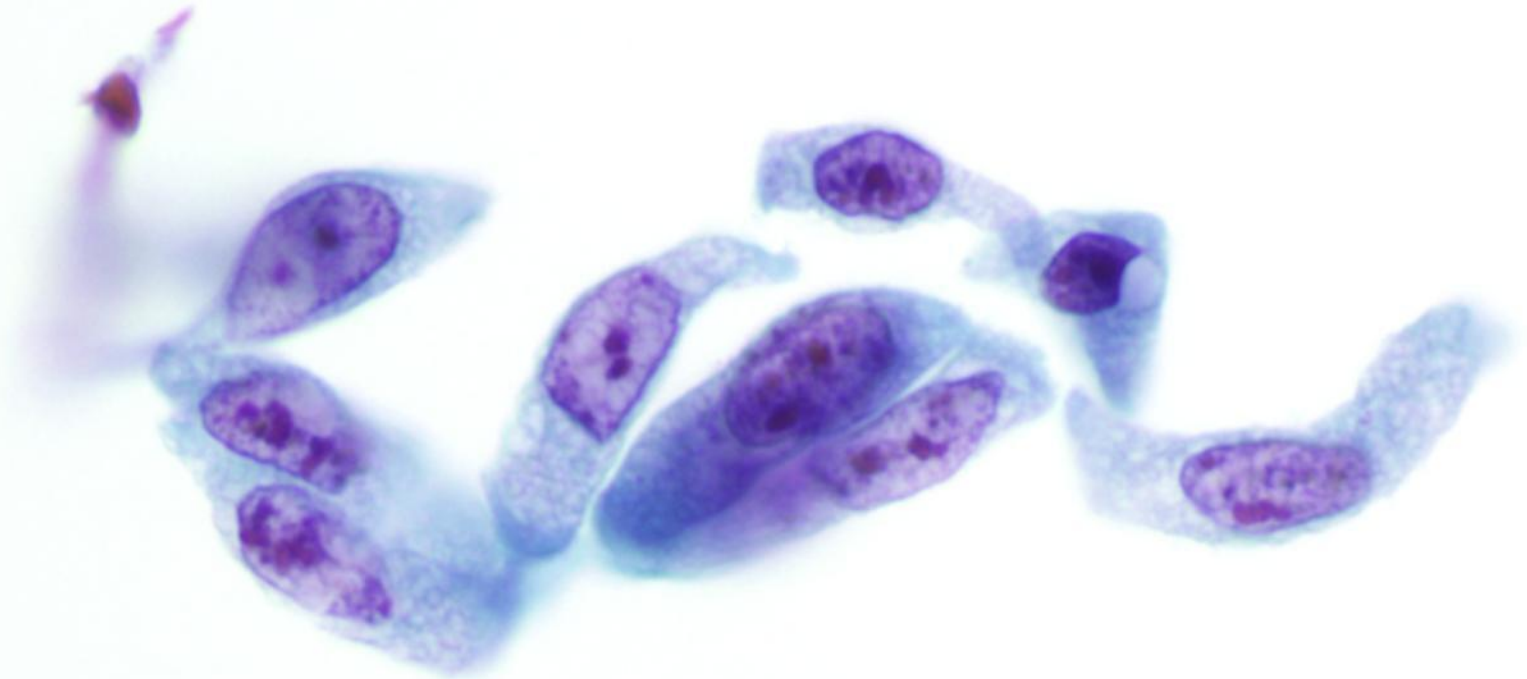




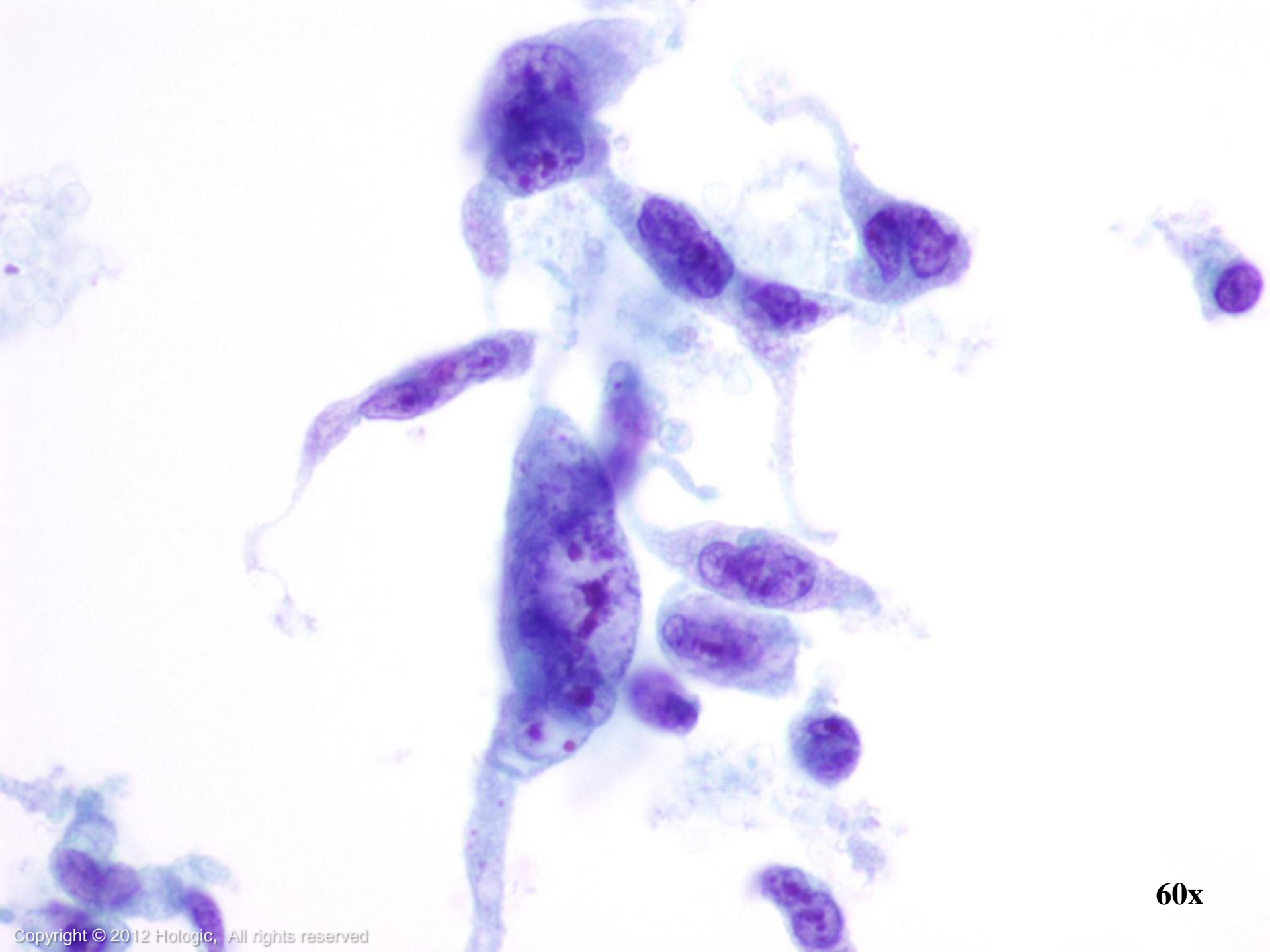
60x



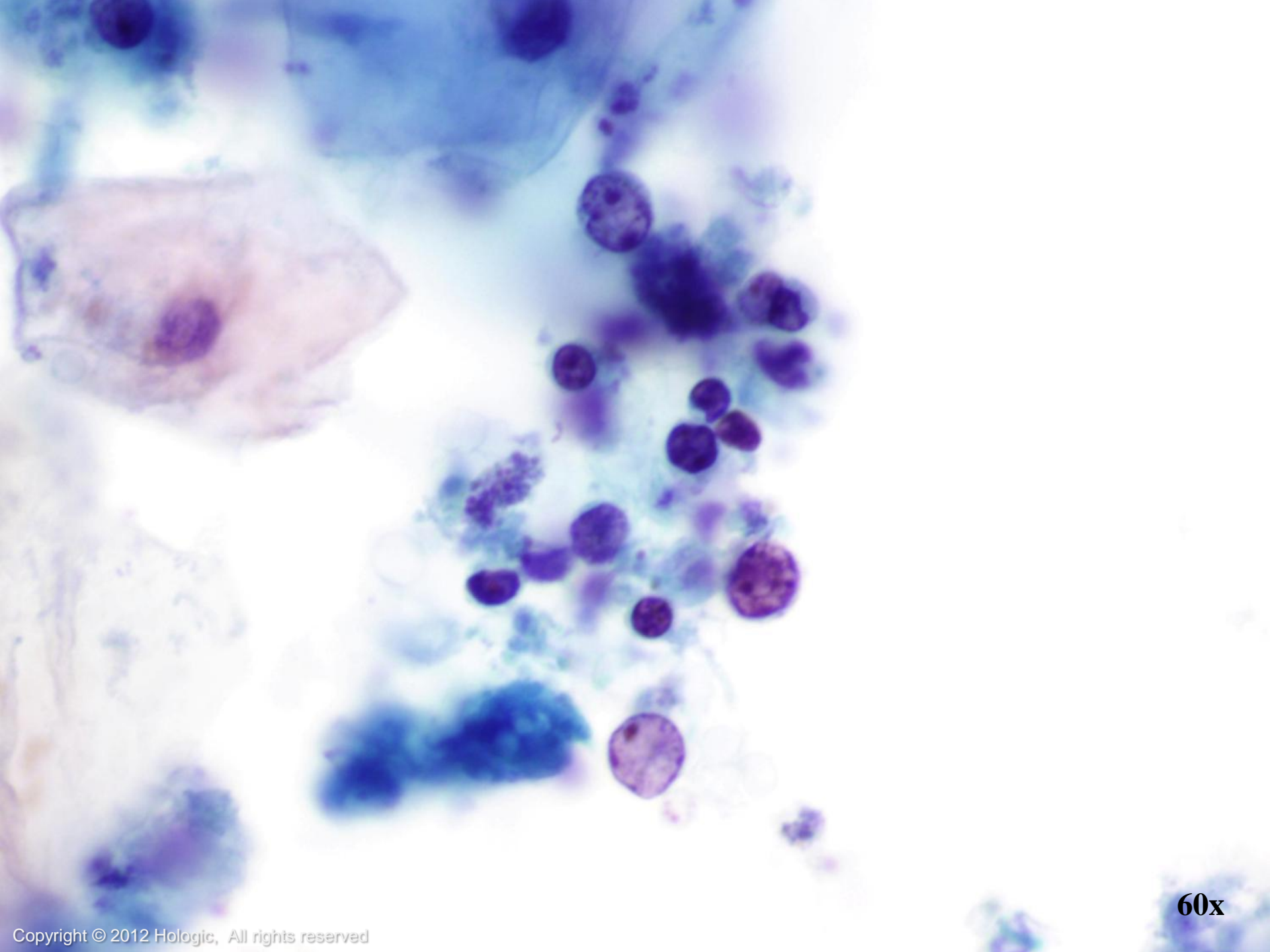
60x



60x



60x



60x

Trademark Statement

CytoLyt, Hologic, PreservCyt, ThinPrep, and UroCyte are registered trademarks of Hologic, Inc. and/or its subsidiaries in the United States. CytoLyt, Hologic, PreservCyt, ThinPrep, UroCyte and associated logos are trademarks of Hologic, Inc. and/or its subsidiaries in other countries.



All other trademarks are the property of their respective owners.

For more information...

- Visit our websites: www.hologic.com, www.thinprep.com, www.cytologystuff.com
 - Product Catalog
 - Contact Information
 - Complete Gynecologic and Non-gynecologic Bibliographies
 - Cytology Case Presentations and Unknowns
 - Slide Library Request Form



Bibliography

ThinPrep® 2000 Processor Operator's Manual

ThinPrep 5000 Processor Operator's Manual

DeMay, Richard M.: *Arts & Science of Cytopathology Exfoliative Cytology*. 1996: 207-235.

DeMay, Richard M.: *Practical Principles of Cytopathology*. 1999: 27-47.

Cibas, E., Ducatman, B.: *Cytology: Diagnostic Principles and Clinical Correlates*. 3rd edition, 2009: 72-98.



Keebler, C., Somrak, T. *The Manual of Cytotechnology*. 7th edition, 1993:161-172.

McKee, Grace T: *Cytopathology*. 1997: 234-254.

Bibliography

Images:

Bich, Brian. *Bronchus*. 2008. Photograph. Lake Superior College, Duluth, MN. Web. *Lake Superior College*.

[<http://employee.lsc.edu/faculty/BrianBich/Picture%20Library/Forms/AllItems.aspx?RootFolder=%2Ffaculty%2FBrianBich%2FPicture%20Library%2FAnat%2DPhys%20II%20%28Biol%201141%29%2FRespiratory%20System%20Tissues%2FBronchi%20and%20Bronchioles%20%2D%20Tutorial&View=%7b997D7559-348B-48F0-A9FE-07741C9C8B65%7d>] 3 Feb 2012.



SmartDraw[®] (Standard Edition) [Software]. (2011). Retrieved from <http://www.smartdraw.com>

ThinPrep[®] Non-Gyn Morphology Reference Atlas: Respiratory: 55-111.