



# ThinPrep<sup>®</sup> Non-Gyn Lecture Series

## Thyroid Cytology

# Benefits of ThinPrep<sup>®</sup> Technology

The use of ThinPrep Non-Gyn for Fine Needle Aspiration specimens from the Thyroid:

- Optimizes cell preservation
- Standardizes specimen preparation
- Simplifies slide screening
- Minimizes number of slides per patient
- Offers versatility to perform ancillary testing



# Required Materials

- ThinPrep<sup>®</sup> 2000 Processor or ThinPrep 5000 Processor
- ThinPrep Microscope Slides
- ThinPrep Non-Gyn Filters (Blue)
- Multi-Mix<sup>™</sup> Racked Vortexor
- CytoLyt<sup>®</sup> and PreservCyt<sup>®</sup> Solutions



# Required Materials

- 50 ml capacity swing arm centrifuge
- 50 ml centrifuge tubes
- Slide staining system and reagents
- 1 ml plastic transfer pipettes
- 95% alcohol
- Coverslips and mounting media

*Optional: Glacial acetic acid, DTT, and saline for troubleshooting*



# Recommended Collection Media

- CytoLyt®
- Balanced electrolyte solutions *such as*
  - Plasma-Lyte®
  - Polysol®



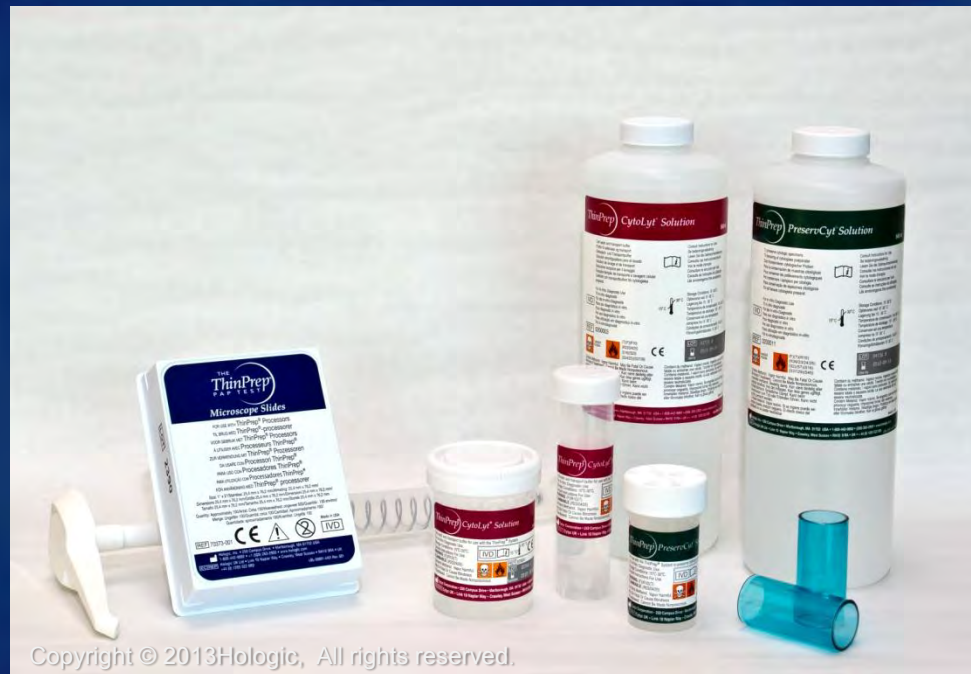# Non-Recommended Collection Media

- Sacomanno and other solutions containing carbowax
- Alcohol
- Mucollexx<sup>®</sup>
- Culture media, RPMI solution
- PBS
- Solutions containing formalin



# Hologic<sup>®</sup> Solutions

- CytoLyt<sup>®</sup>
- PreservCyt<sup>®</sup>



Copyright © 2013 Hologic, All rights reserved.



# Hologic<sup>®</sup> Solutions

## *CytoLyt<sup>®</sup> Solution*

- Methanol-based, buffered preservative solution
  - Lyses red blood cells
  - Prevents protein precipitation
  - Dissolves mucus
  - Preserves morphology for 8 days at room temp.
- Intended as transport medium
- Used in specimen preparation prior to processing





# Hologic<sup>®</sup> Solutions

## *PreservCyt<sup>®</sup> Solution*

- Methanol based, buffered solution
- Specimens must be added to PreservCyt prior to processing
- PreservCyt Solution cannot be substituted with any other reagents
- Cells in PreservCyt Solution are preserved for up to 3 weeks at a temperature range of 4°-37°C



# FNA Biopsy

- Performed by a cytopathologist or clinician.
- A 23 gauge or 25 gauge needle with a 10ml syringe is used
- The area is cleaned with 95% ethanol
- The needle is passed thru the skin and into the nodule. Several strokes are made with or without vacuum created by the syringe plunger



# Sample Collection

- Optimal: Deposit and rinse the entire sample into a centrifuge tube containing 30 ml of CytoLyt<sup>®</sup> solution
- Secondary method: Collect into a balanced electrolyte solution such as Polysol<sup>®</sup> or Plasma-Lyte<sup>®</sup> injection solutions
- If direct or air dried slides are desired, prepare prior to rinsing the needle



*Note:* If possible, flush the needle and syringe with a sterile anticoagulant solution prior to aspirating the sample. Some anticoagulants may interfere with other cell processing techniques, so use caution if you plan to use the specimen for other testing.

# Sample Preparation

1. Collection
2. Concentrate by centrifugation - 600g for 10 minutes
3. Pour off supernatant and vortex to re-suspend cell pellet
4. Evaluate cell pellet
  - If cell pellet is not free of blood, add 30 ml of CytoLyt<sup>®</sup> to cell pellet and repeat from step 2
5. Add recommended # of drops of specimen to PreservCyt<sup>®</sup> vial
6. Allow to stand for 15 minutes
7. Run on ThinPrep<sup>®</sup> 2000 Processor using Sequence 3 or ThinPrep 5000 using Sequence Non-Gyn
8. Fix, stain, and evaluate



# Sample Preparation Techniques

- Centrifugation - 600g for 10 minutes or 1200g for 5 minutes
  - Concentrates the cellular material in order to separate the cellular components from the supernatant



*Refer to Centrifuge Speed Chart in the ThinPrep<sup>®</sup> 2000 or ThinPrep 5000 Processor Manual, Non-Gynecologic section, to determine the correct speed for your centrifuge to obtain force of 600g or 1200g*

# Sample Preparation Techniques

- Pour off supernatant
  - Invert the centrifuge tube 180° in *one smooth movement*, pour off all supernatant, and return tube to its original position

*(Note: Failure to completely pour off the supernatant may result in a sparsely cellular sample due to dilution of the cell pellet).*



# Sample Preparation Techniques

- Vortex to re-suspend cell pellet
  - Randomizes the cell pellet and improves the results of the CytoLyt<sup>®</sup> solution washing procedure
  - Place the centrifuge tube on a vortexor and agitate the cell pellet for 3 seconds, or vortex manually by syringing the pellet back and forth with a plastic pipette



# Sample Preparation Techniques

- CytoLyt<sup>®</sup> Solution Wash
  - Preserve cellular morphology while lysing red blood cells, dissolving mucus, and reducing protein precipitation
  - Add 30 ml of CytoLyt Solution to cell pellet, concentrate by centrifugation, pour off the supernatant, and vortex to resuspend the cell pellet





# Sample Preparation Techniques

- Evaluate cell pellet
  - If cell pellet is white, pale pink, tan or not visible, add specimen to PreservCyt<sup>®</sup> vial (# of drops added is dependent on sample volume; see future slides)
  - If cell pellet is distinctly red or brown (indicating presence of blood), conduct a CytoLyt<sup>®</sup> wash



# Sample Preparation Techniques

- Calculate how many drops of specimen to add to PreservCyt<sup>®</sup> vial:
  - If pellet is clearly visible and the pellet volume is  $\leq 1\text{ml}$  (if not, consider the next 2 slides)
- Vortex pellet and transfer 2 drops to a fresh PreservCyt vial



# Sample Preparation Techniques

- Calculate how many drops of specimen to add to PreservCyt<sup>®</sup> vial:
  - If pellet volume is  $\geq 1$  ml
    - Add 1ml of CytoLyt<sup>®</sup> Solution into the tube and vortex briefly to resuspend the cell pellet
    - Transfer 1 drop of the specimen to a fresh PreservCyt vial



# Sample Preparation Techniques

- Calculate how many drops of specimen to add to PreservCyt<sup>®</sup> vial:
  - If pellet is not visible or scant
    - Add contents of a fresh PreservCyt vial into the tube and vortex briefly to mix the solution
    - Pour entire sample back into the vial



# Sample Preparation Troubleshooting

- Due to the biological variability among samples and variability in collection methods, standard processing may yield a slide that indicates further troubleshooting may be needed.



# Sample Preparation Troubleshooting

- After staining, you may observe the following irregularities:
  - Non-uniform distribution of cells in the cell spot *without* a “sample is dilute” message
  - Uneven distribution in the form of a ring or halo of cellular material and/or white blood cells
  - A sparse cell spot lacking in cellular component and containing blood, protein and debris – may be accompanied by a “sample is dilute” message



# Techniques Used in Troubleshooting

- Diluting the Sample 20 to 1
- Glacial Acetic Acid Wash for Blood and Non-Cellular Debris
- Saline Wash for Protein



# Techniques Used in Troubleshooting

- Diluting the Sample 20 to 1
  - Add 1ml of the sample that is suspended in PreservCyt<sup>®</sup> Solution to a new PreservCyt Solution vial (20ml). This is most accurately done with a calibrated pipette.





# Techniques Used in Troubleshooting

- Glacial Acetic Acid Wash for Blood and Non-Cellular Debris
  - If sample is bloody, it can be further washed using a solution of 9 parts CytoLyt<sup>®</sup> Solution and 1 part Glacial Acetic acid.



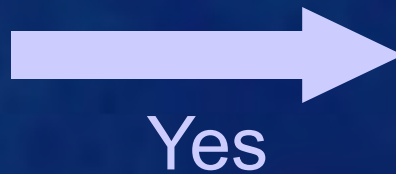
# Techniques Used in Troubleshooting

- Saline Wash for Protein
  - If sample contains protein, it can be further washed with saline solution in place of CytoLyt<sup>®</sup> Solution.



# Troubleshooting Bloody or Proteinaceous Specimens

“Sample is Dilute”  
message



Check to see if cellularity is adequate. If not, use more of the pellet, if available and prepare new slide.




No, continue to  
next slide



# Troubleshooting Bloody or Proteinaceous Specimens

Does the slide have a  
“halo” of cellular  
material and/or white  
blood cells?



Yes

Dilute the sample 20:1  
by adding 1ml of  
residual sample to a  
new PreservCyt<sup>®</sup>  
Solution vial and  
prepare new slide.

*If halo is present on the  
new slide, contact Hologic<sup>®</sup>  
Technical Service.*



No, continue to next  
slide



# Troubleshooting Bloody or Proteinaceous Specimens

Is the slide sparse and does it contain blood, protein or non-cellular debris?



No

Contact Hologic®  
Technical Service



Yes-blood  
or non-  
cellular  
debris

Centrifuge remaining specimen from PreservCyt® vial, pour off. Add 30ml of a 9:1 CytoLyt® to glacial acetic acid solution to the sample, centrifuge, pour off and vortex. Add to PreservCyt vial and prepare new slide. *If the resulting slide is sparse, contact Hologic Technical Service.*



Yes-protein

Centrifuge remaining specimen from PreservCyt vial, pour off. Add 30 ml of saline to sample, centrifuge, pour off and vortex. Add to PreservCyt vial and prepare new slide. *If resulting slide is sparse, contact Hologic Technical Service.*

# Troubleshooting Common Artifacts

- Smudged nuclear detail
- Compression artifact
- Staining artifact
- Edge of the cylinder artifact



# Troubleshooting Common Artifacts

- **Smudged nuclear detail**
  - May occur if specimen is collected in saline, PBS, or RPMI
  - To avoid this, collect the sample either fresh, in CytoLyt<sup>®</sup>, or in PreservCyt<sup>®</sup> solution



# Troubleshooting Common Artifacts

- **Compression artifact**
  - Appears as “air dry” artifact on the perimeter of the cell spot
  - Due to the compression of cells between the edge of the filter and the glass of the slide





# Troubleshooting Common Artifacts

- **Staining artifact**
  - Mimics air-drying
  - Appears as a red or orange central staining primarily in cell clusters or groups
  - Due to the incomplete rinsing of counterstains
  - To eliminate, fresh alcohol baths or an additional rinse step after the cytoplasmic stains is required



# Troubleshooting Common Artifacts

- **Edge of the cylinder artifact**
  - Narrow rim of cellular material just beyond the circumference of the cell spot
  - Result of cells from the outer edge of the wet filter cylinder being transferred to the glass slide

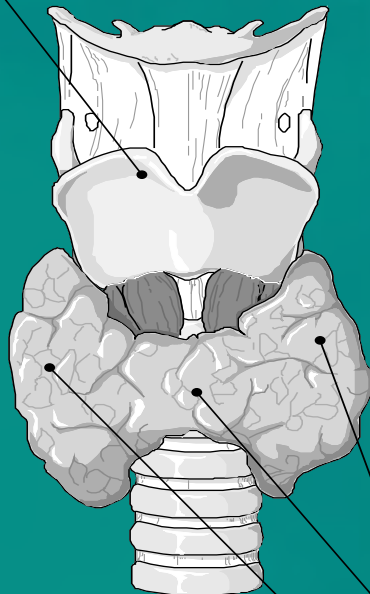


# Anatomy

## Endocrine Glands Thyroid and Parathyroid Glands

1. Cartilage

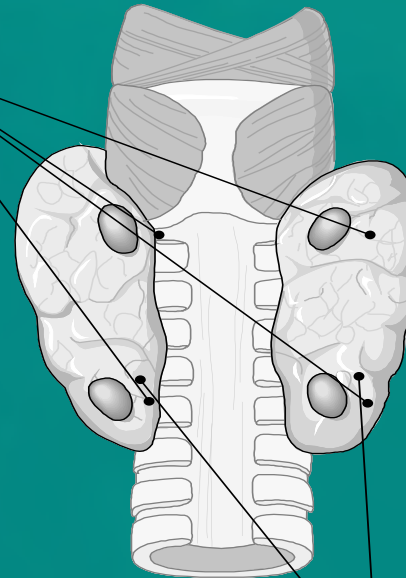
2. Parathyroid glands-Posterior



3. Left Lobe

4. Isthmus

5. Right Lobe

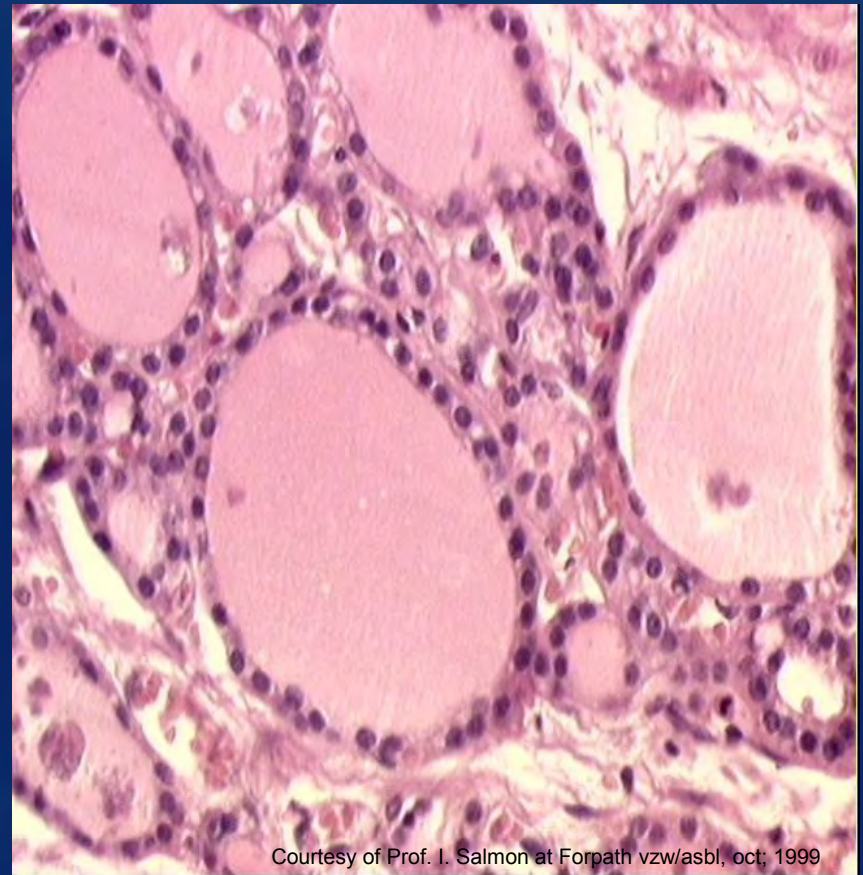


6. Right & Left Lobes-Posterior

ThinPrep  
Non-Gyn

# Histology of the Epithelium

- The Thyroid is lined by one type of epithelium:
  - A single layer of thyroid epithelial cells called *follicular cells* are arranged in spherical follicles around a central ball of colloid



Courtesy of Prof. I. Salmon at Forpath vzw/asbl, oct, 1999

# Specimen Adequacy

- Both the quantity and quality of the cellular component as well as colloid must be considered
- Guidelines for specimen adequacy vary. The following is commonly used: A minimum of six groups of well-visualized follicular cells, with at least ten cells per group
  - *NOTE : A minimum number of follicular cells are not required for the following exceptions: Specimens consisting primarily of abundant thick colloid and solid nodules containing cytologic atypia or consisting of numerous inflammatory cells should be considered satisfactory for evaluation*



# Normal Components and Findings

- Follicular Cells
  - Range in shape from cuboidal to columnar
  - Nuclei are round to oval and are about the size of a lymphocyte
  - Evenly distributed granular chromatin
  - Single, in honeycomb sheets and intact follicles with even spacing
  - Cytoplasm is fine and pale, stains blue with Pap stain



# Normal Components and Findings

- Hürthle Cells
  - Polygonal in shape and frequently binucleate
  - Eccentrically placed nuclei ranging from small to large
  - Finely granular, abundant cytoplasm staining blue to orange with Pap stain



# Normal Components and Findings

- Multinucleated giant cells
  - Commonly found with papillary carcinoma but not limited to this lesion
  - Can be found in other benign and malignant conditions





# Normal Components and Findings

- Lymphocytes
  - May be present in both benign and malignant lesions
  - Can be confused with stripped nuclei of follicular cells
  - Will have coarser chromatin, a thin rim of cytoplasm, less prominent nuclear membrane and the presence of lymphoglandular bodies



# Normal Components and Findings

- Spindle cells and squamous cells
  - May be present in both benign and malignant lesions



# Normal Components and Findings

- Calcifications

- Dystrophic

- Peripheral “eggshell” or rim-like

- Usually found in benign cysts but can be found with follicular neoplasms

- Coarse, dense nodular

- Psammomatous

- Concentrically laminated, crystalline structures associated most often with papillary carcinoma



# Normal Components and Findings

- Hemosiderin
  - Associated with bleeding
  - Present in cyst aspirations and can help to favor a benign thyroid nodule over a follicular neoplasm
  - Stains golden-brown with Pap stain



# Normal Components and Findings

- Amyloid
  - Similar to dense colloid: waxy appearance
  - Can be distinguished with Congo red stain
  - Associated with medullary carcinoma, but also present in amyloid goiter



# Normal Components and Findings

- Mucin
  - When present it's thought that the aspirated lesion is likely not located in the thyroid, however it may be associated with all types of thyroid cancers



# Normal Components and Findings

- **Colloid**
  - A glycoprotein that is the storage site for iodinated thyroid hormones
  - An active thyroid produces a paler, thinner colloid
  - With less active thyroid, colloid tends to be thicker and denser
  - Stains blue, green, pink, or orange with Pap stain

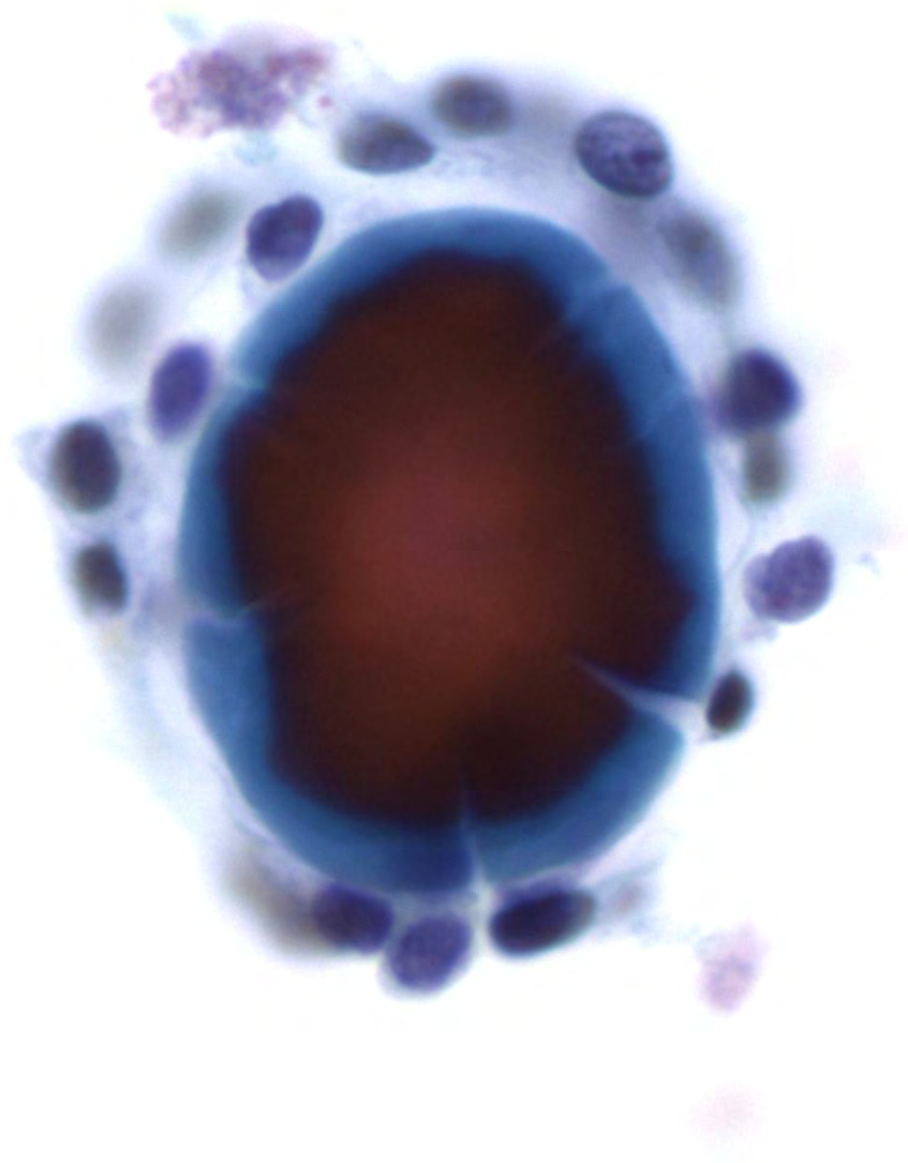


- **Dense/solid**

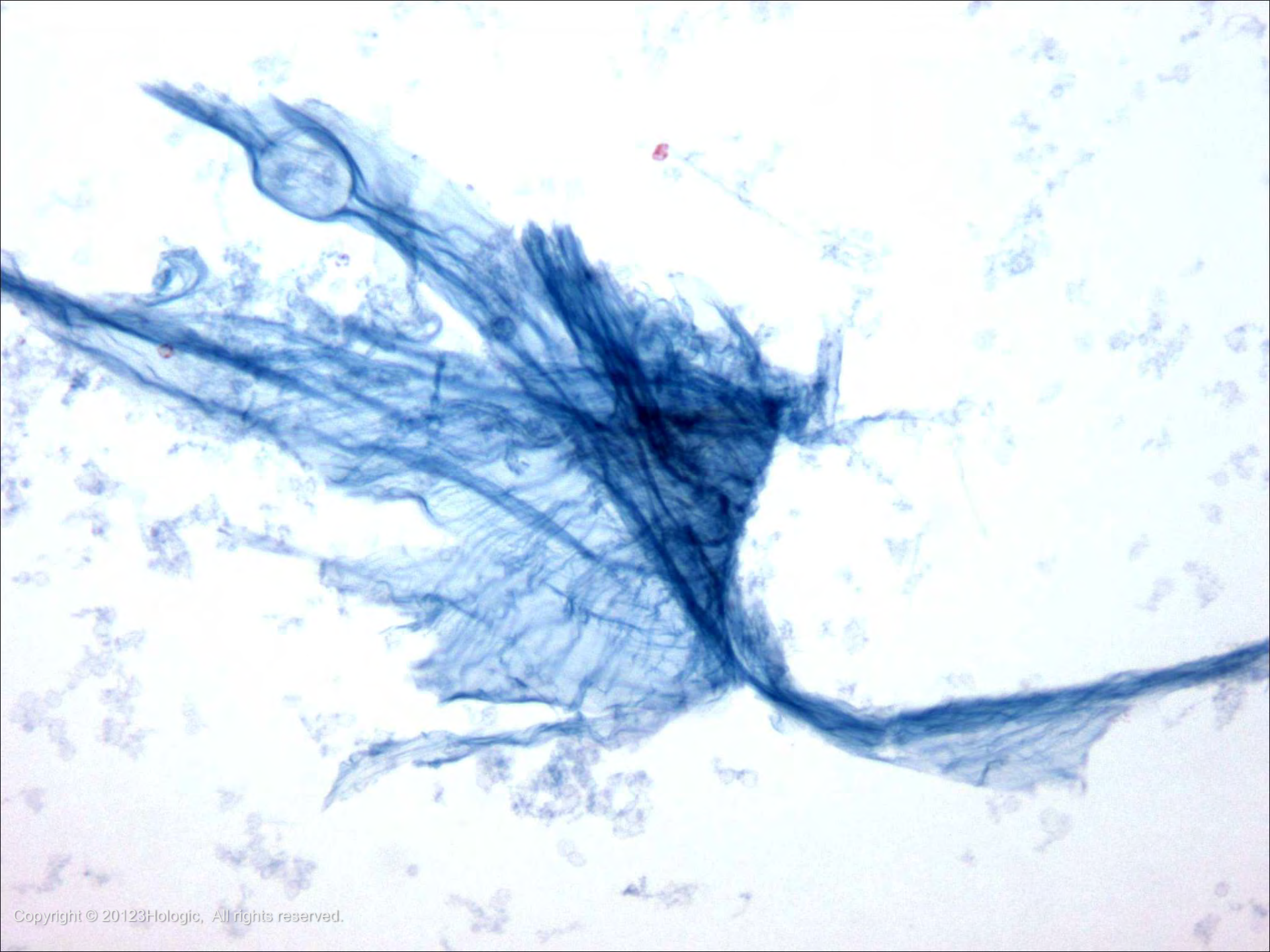
- Irregularly shaped, rounded droplets
- Often shows perpendicular cracking

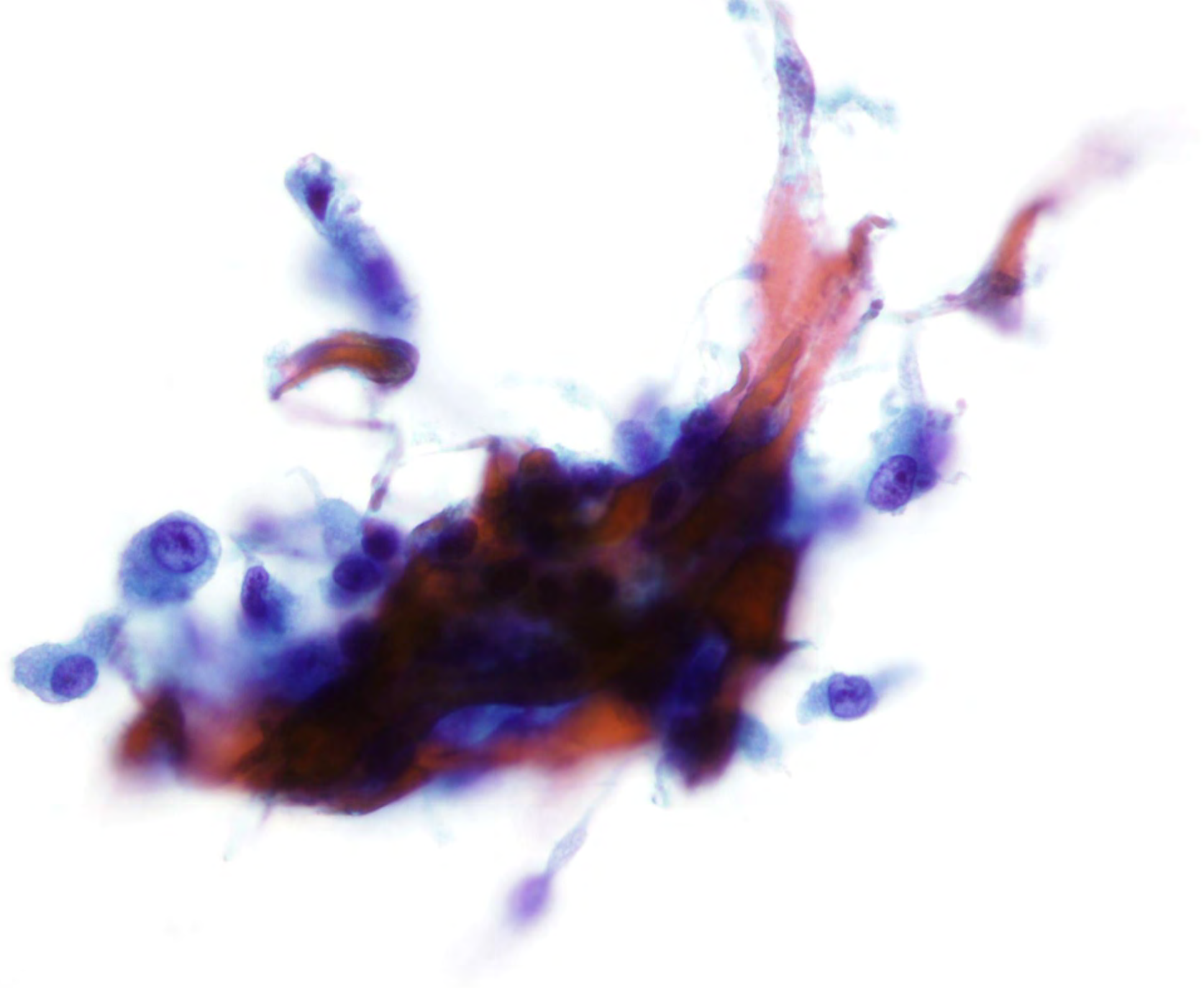
- **Watery/diffuse**

- Thin, membrane/cellophane/tissue paper-like









# Normal Components and Findings

- Possible Contaminants
  - Ciliated cells from thyroglossal duct cysts or by accidental sampling of the trachea
  - Fat, although rare, may be present from the subcutaneous adipose tissue in the neck and can also rarely occur in a range of thyroid lesions
  - Skeletal Muscle needs to be distinguished from dense colloid; has striations and nuclei



# Nondiagnostic Findings Types

- Cyst fluid only
- Obscuring factors
- Virtually acellular

– *NOTE : A minimum number of follicular cells are not required for the following exceptions: Specimens consisting primarily of abundant thick colloid and solid nodules containing cytologic atypia or consisting of numerous inflammatory cells should be considered to be satisfactory for evaluation*



# Nondiagnostic Findings Overview

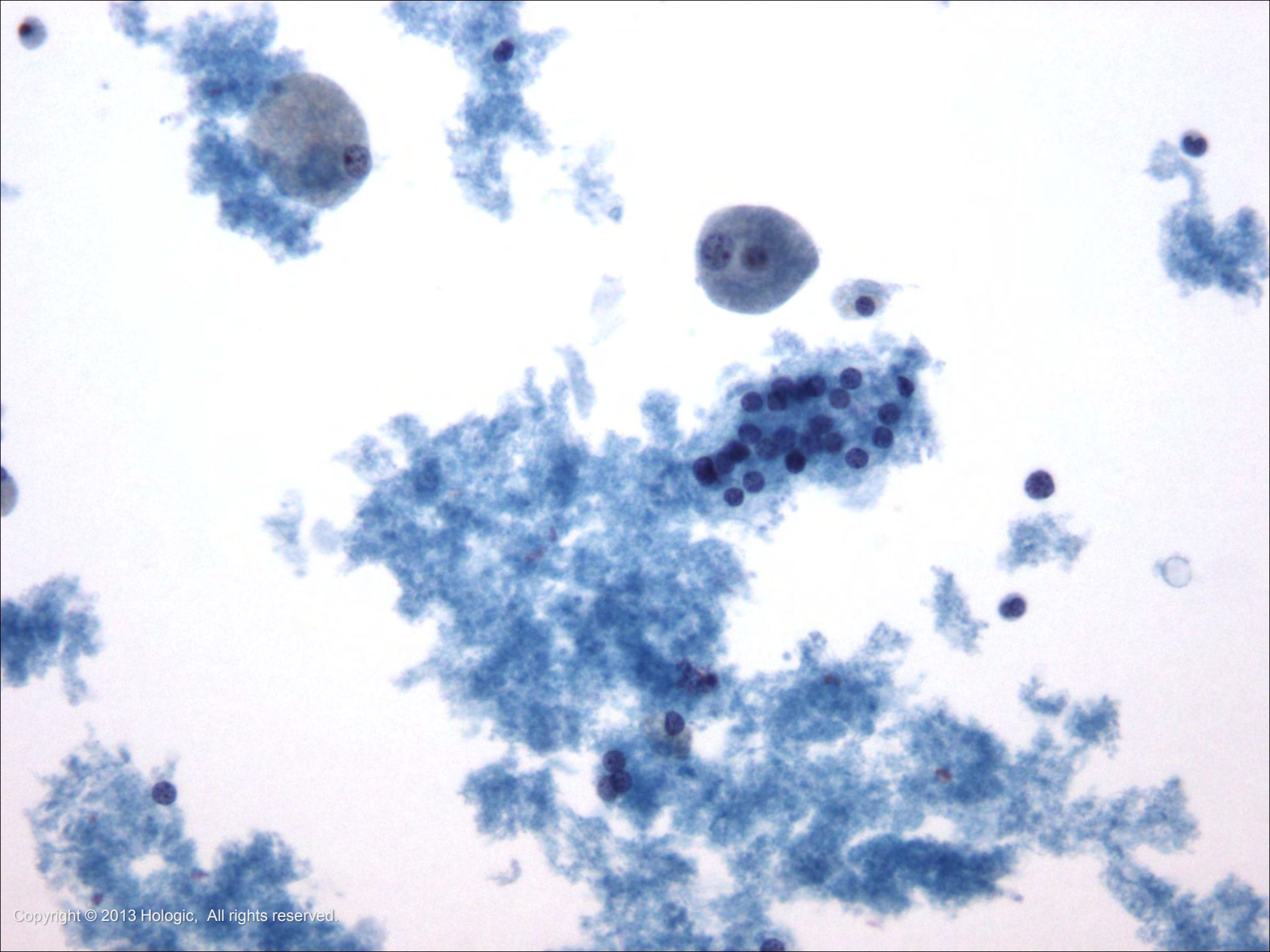
- Cyst
  - 15-25% of all thyroid nodules are cystic
  - Exclusion of malignancy is not possible with a diagnosis of cyst
  - Benign and malignant thyroid lesions can be cystic, papillary carcinoma being the most common cystic thyroid cancer
  - Need to be wary of both false negative and false positive diagnosis



# Nondiagnostic Findings Cytology

- Cyst
  - Abundant hemosiderin-laden macrophages
  - Foamy histiocytes
  - Blood
  - Proteinaceous debris
  - Watery colloid - amount will vary and may be difficult to appreciate
  - Rare follicular cells may be present
    - May show reactive/degenerative changes that can mimic cancer





# Benign Findings-Inflammatory Types

- Acute thyroiditis
- Granulomatous thyroiditis
  - Subacute (de Quervain's)
  - Fungal
    - Aspergillus, Blastomyces, Candida, Pneumocystis
  - Parasitic
    - Echinococcus, Wucheria, Treponema
  - Mycobacterial thyroiditis
    - Tuberculosis
- Chronic Thyroiditis
  - Lymphocytic (Hashimoto) thyroiditis
  - Riedel thyroiditis/disease





# Benign Findings-Inflammatory Overview

- Acute Thyroiditis
  - Very painful, potentially life threatening
  - Very rare due to the accumulation of iodine in the thyroid which acts as a “germ killer”
  - Those at risk are the young, old, immunosuppressed, and malnourished



*continued on next slide*

# Benign Findings-Inflammatory Overview

- Acute Thyroiditis - continued
  - Most common cause is bacterial (less commonly fungal)
  - *Staphylococcus aureus*, *Streptococcus pyogenes*, and *Streptococcus pneumoniae* are responsible for approximately 80% of cases
  - Typically not aspirated. If performed, aspirate is a characteristic yellow-green pus



# Benign Findings-Inflammatory Cytology

- Acute Thyroiditis
  - Abundant neutrophils and histiocytes
  - Granulation tissue, necrosis, and debris
  - Scant epithelial cells. When present may have reactive/degenerative changes
  - Bacteria may be noted



# Benign Findings-Inflammatory Overview

- Granulomatous thyroiditis (Subacute, de Quervain's)
  - Usually diagnosed clinically (without FNA)
  - Most common cause of painful thyroid disease
  - Mainly affects middle-aged women
  - Possible viral etiology; possible genetic predisposition
  - Self-limiting disease for most: recovery in a few months
  - Symptomatic relief with nonsteroidal anti-inflammatory agents



# Benign Findings-Inflammatory Cytology

- Granulomatous thyroiditis (Subacute, de Quervain's)
  - Typically hypocellular
  - Telltale multinucleated giant cells engulfing colloid
  - Granulomas and loose clusters of epithelioid histiocytes
  - Scant follicular cells which may show reactive changes
  - Background of lymphocytes, plasma cells, eosinophils, and neutrophils



# Benign Findings-Inflammatory Overview

- Chronic lymphocytic (Hashimoto) thyroiditis
  - Most common form of thyroiditis
  - Must be distinguished from MALT lymphoma
  - Autoimmune disease, most common in middle aged women and adolescents
  - Many patients don't need to be aspirated and can be diagnosed clinically
  - One-third of patients have atypical presentation and are biopsied

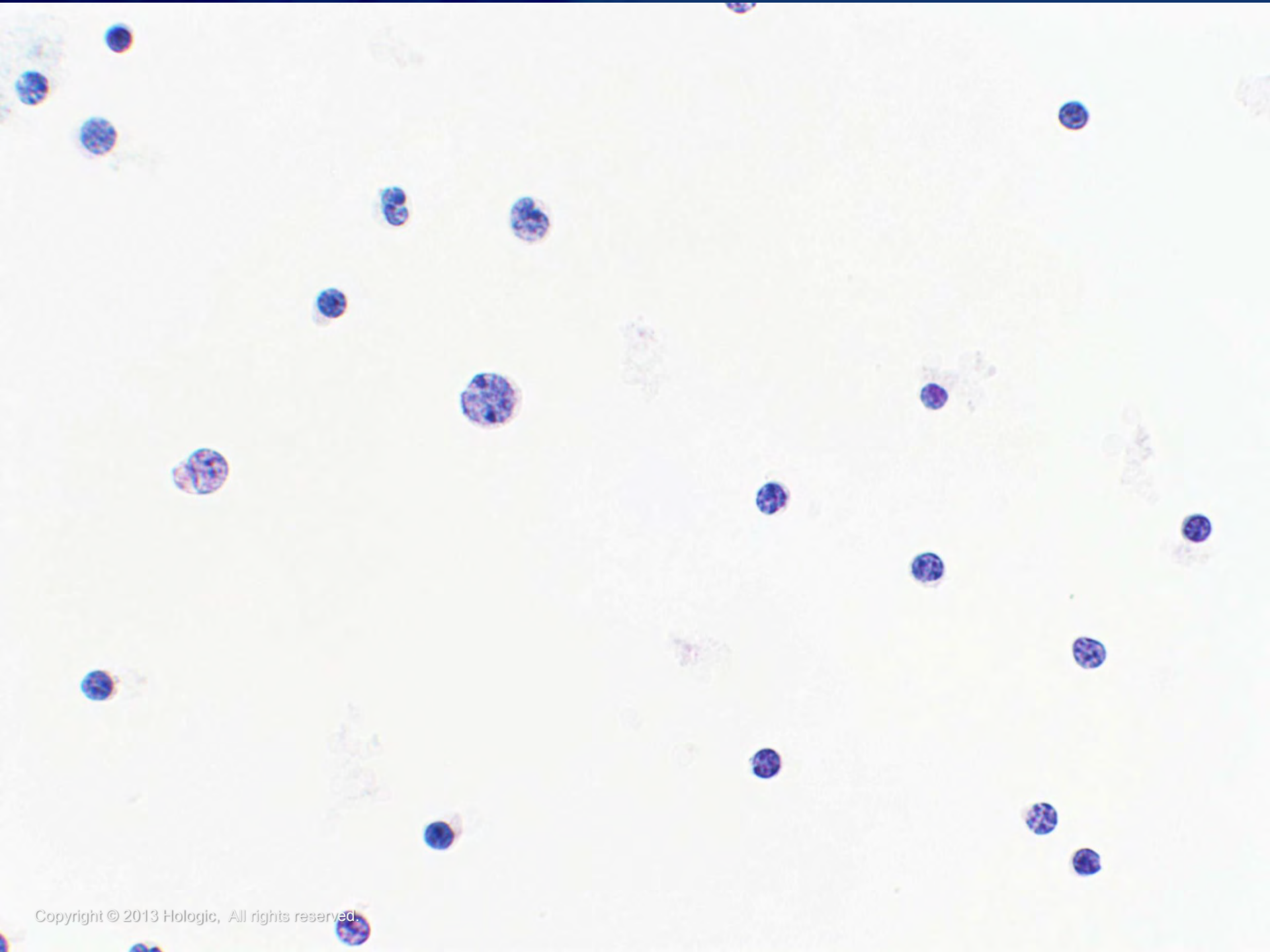


# Benign Findings-Inflammatory Cytology

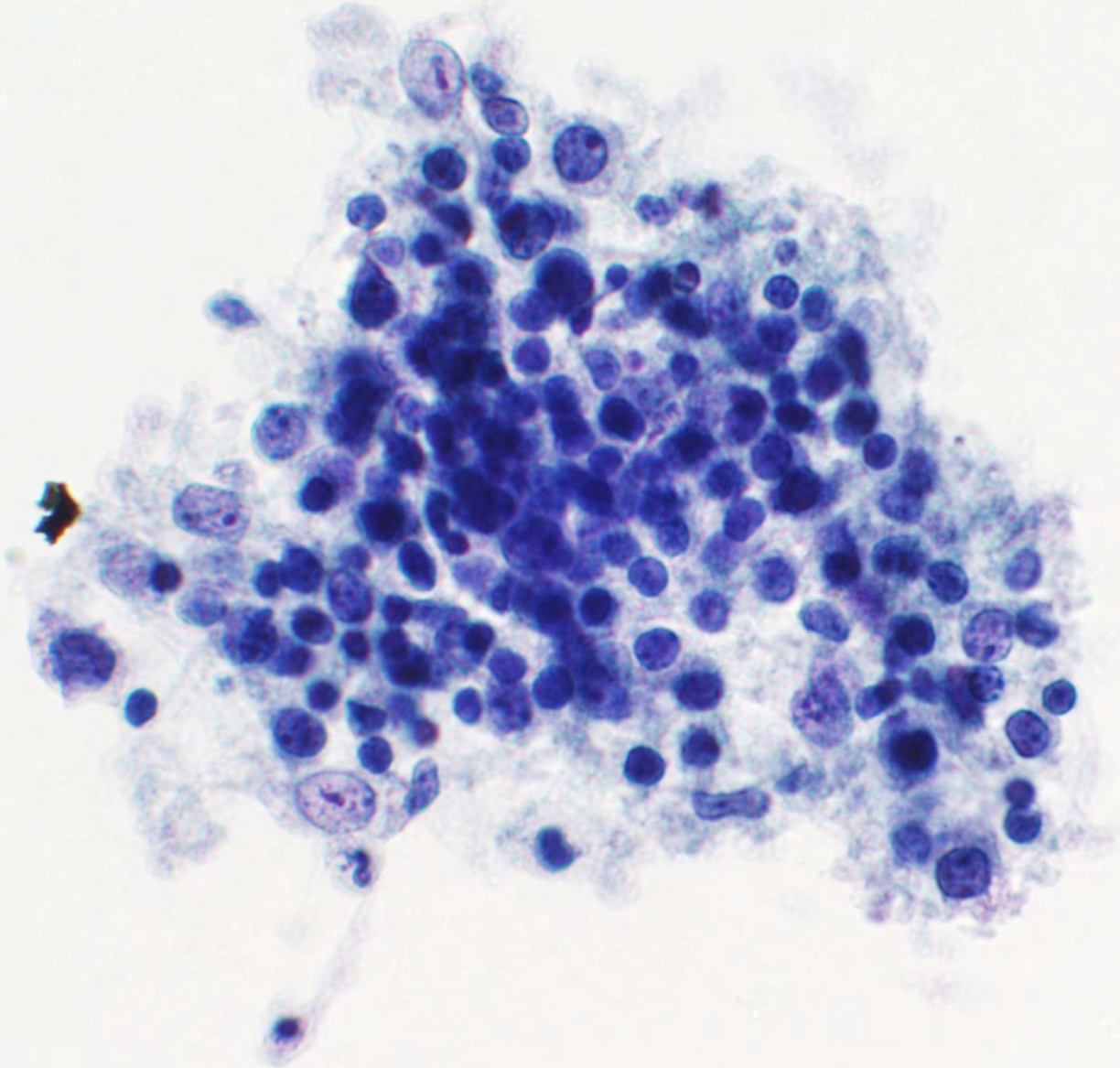
- Chronic lymphocytic (Hashimoto) thyroiditis
  - Hypercellular
  - Polymorphic lymphoid cells: small mature lymphocytes, larger reactive lymphoid cells, occasional plasma cells
  - Hürthle cells (isolated cells and in sheets)

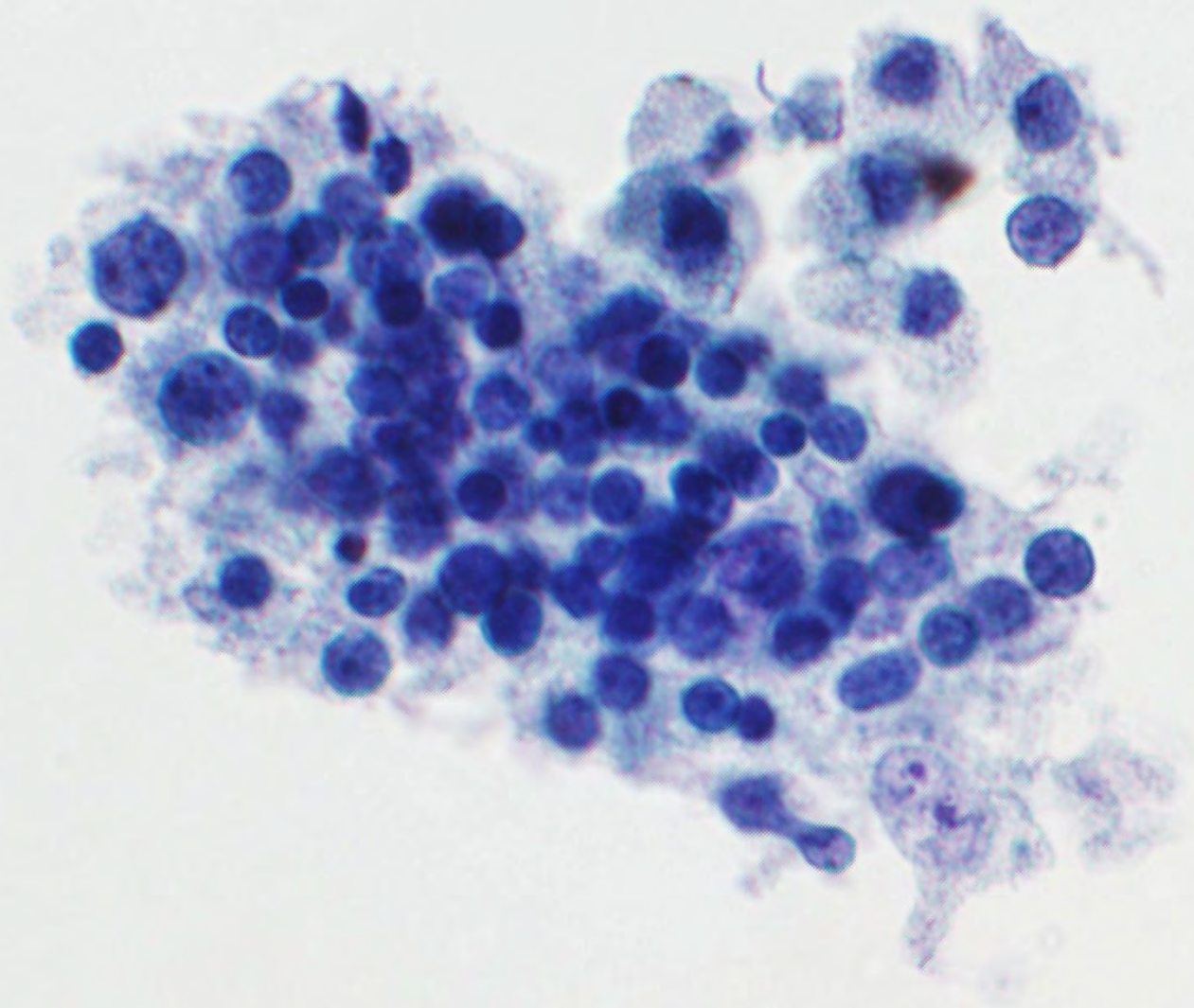


*Note: There is no minimum requirement for follicular or Hürthle cell component to be considered satisfactory*









# Benign Findings-Inflammatory Overview

- Riedel Thyroiditis
  - Unknown cause
  - Primarily middle-aged or older women, many of whom have a history of Hashimoto thyroiditis
  - Most rare of all types of thyroiditis
  - Epstein-Barr virus could be a causative agent
  - Patients present with a painless, non-tender thyroid



# Benign Findings-Inflammatory Cytology

- Riedel Thyroiditis
  - Frequently hypocellular to acellular
  - Spindle-shaped mesenchymal cells
  - Collagen strands
  - May be a few lymphocytes, plasma cells, neutrophils, eosinophils, and rare giant cells



# Benign Findings-Inflammatory Overview & Cytology

- Black Thyroid

- Associated with **minocycline**, an antibiotic in the tetracycline family given for acne treatment
- Similar appearance to melanin, but is a breakdown product of minocycline
- Coarse, dark brown/black pigment in the cytoplasm of macrophages, follicular cells, and colloid



# Benign Findings-Epithelial Types

- Benign Follicular Nodule (BFN)
  - Nodular goiter
  - Colloid nodule
  - Hyperplastic (adenomatoid) nodule
  - Follicular adenoma (macrofollicular type)
  - Graves' disease



# Benign Findings-Epithelial Overview

- **Benign Follicular Nodule (BFN):**
  - Although these benign lesions have different clinical and histologic features, they are impossible to distinguish by FNA
  - A diagnosis of BFN warrants the same conservative treatment regardless of the specific histologic classification
  - Histologic terms like “c/w colloid nodule” or “c/w adenomatoid nodule” are acceptable modifiers under the **Benign** general categorization



# Benign Findings-Epithelial Cytology

- Benign Follicular Nodule (BFN):
  - Variable amounts of colloid
  - Benign-appearing follicular cells
  - Hürthle cells
  - Macrophages



*Note: There may be rare microfollicles, but they should be out numbered by macrofollicles*



# Benign Findings-Epithelial Overview

- Nodular Goiter (NG)
  - Most common thyroid nodular disease
  - Nodules are usually comprised mostly of macrofollicles
  - A minority of nodules in NG are comprised mostly of microfollicles; these are often classified as abnormal by FNA (“false positives”)



# Benign Findings-Epithelial Cytology

- Nodular Goiter
  - Scant to moderate cellularity
  - Abundant colloid
  - Pigment-laden and/or foamy histiocytes
  - Follicular cells arranged in variably sized sheets (macrofollicular fragments) and in intact macrofollicles

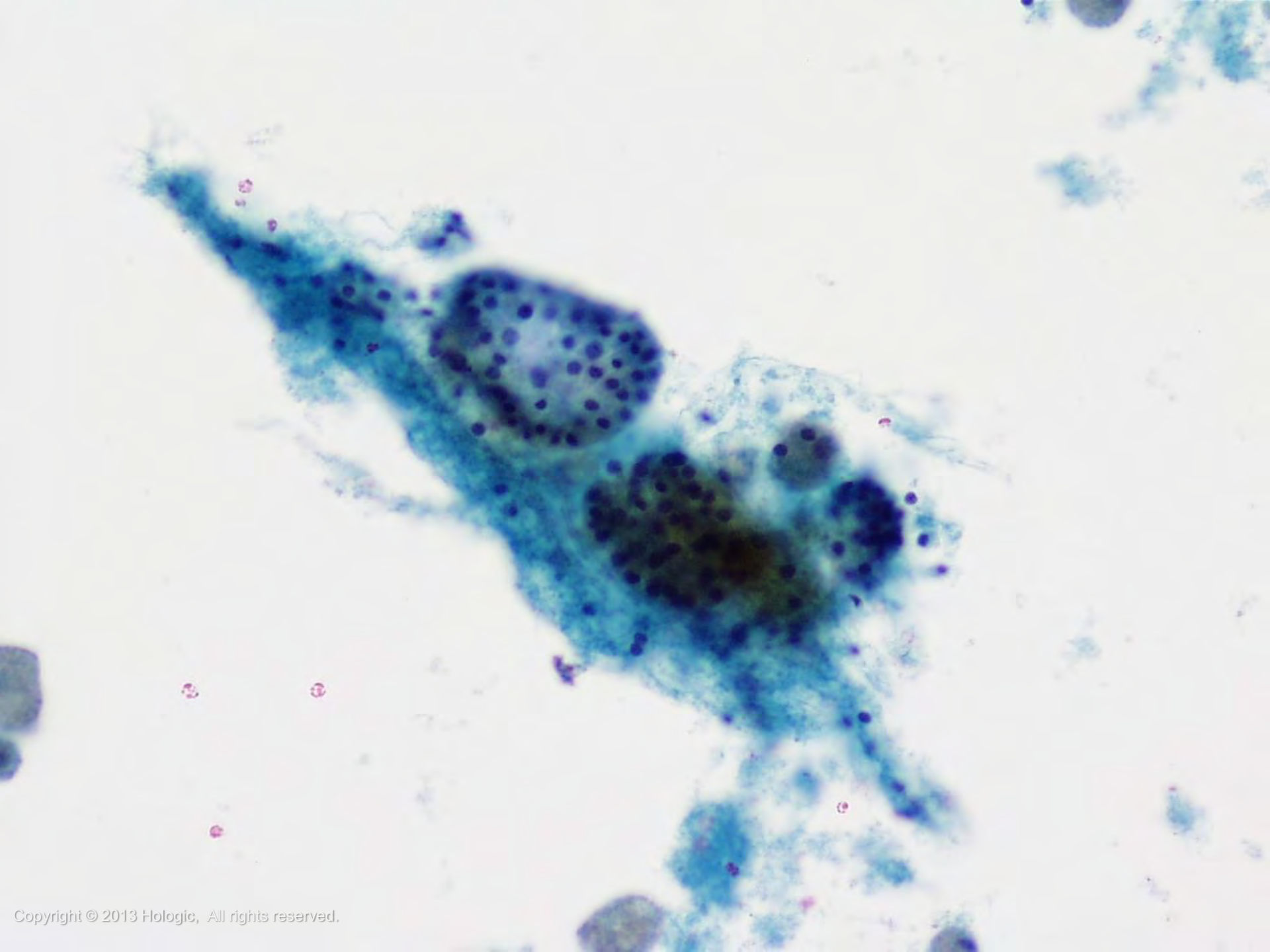


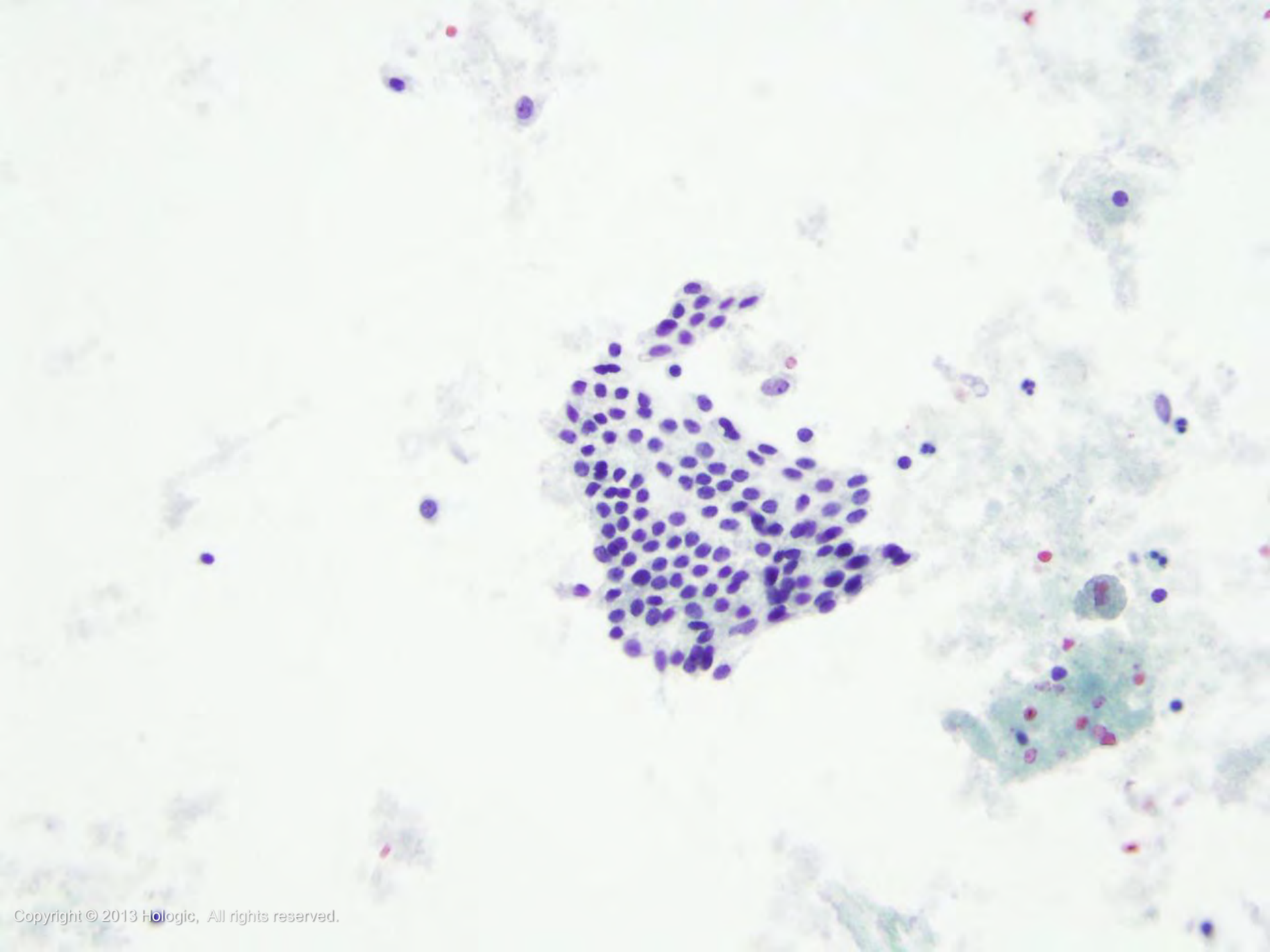
*continued on next slide*

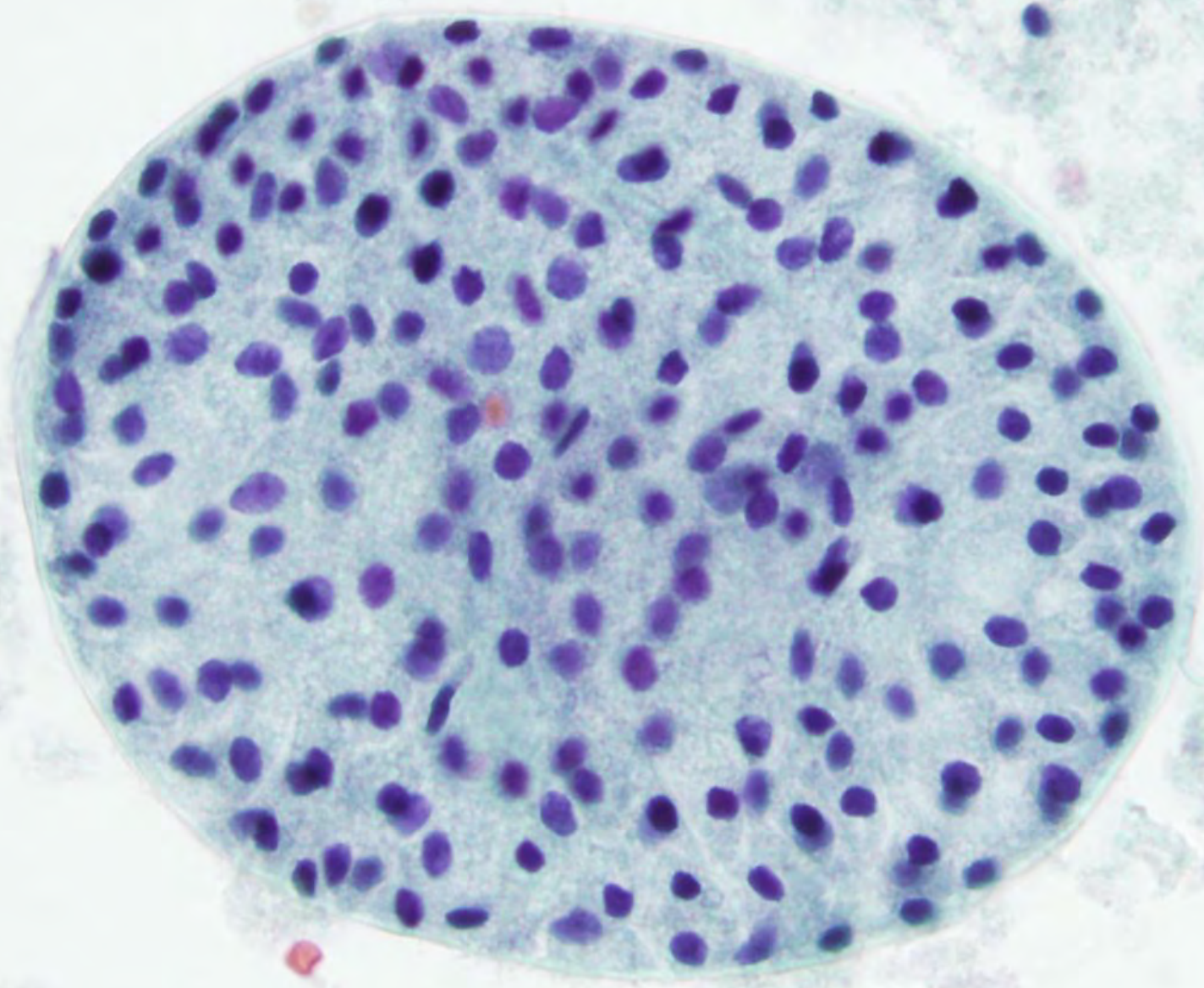
# Benign Findings-Epithelial Cytology

- Nodular Goiter - continued
  - Nuclei of the follicular cells uniformly spaced within the sheet, centrally placed within the cytoplasm, small and round
  - Naked nuclei
  - Scattered Hürthle cells









# Benign Findings-Epithelial Overview

- Colloid Nodule
  - Subtype of nodular goiter nodule that has markedly enlarged follicles filled with abundant colloid
  - Little risk of malignancy
  - However, a small (usually biologically insignificant) malignant nodule could be present next to the sampled colloid nodule



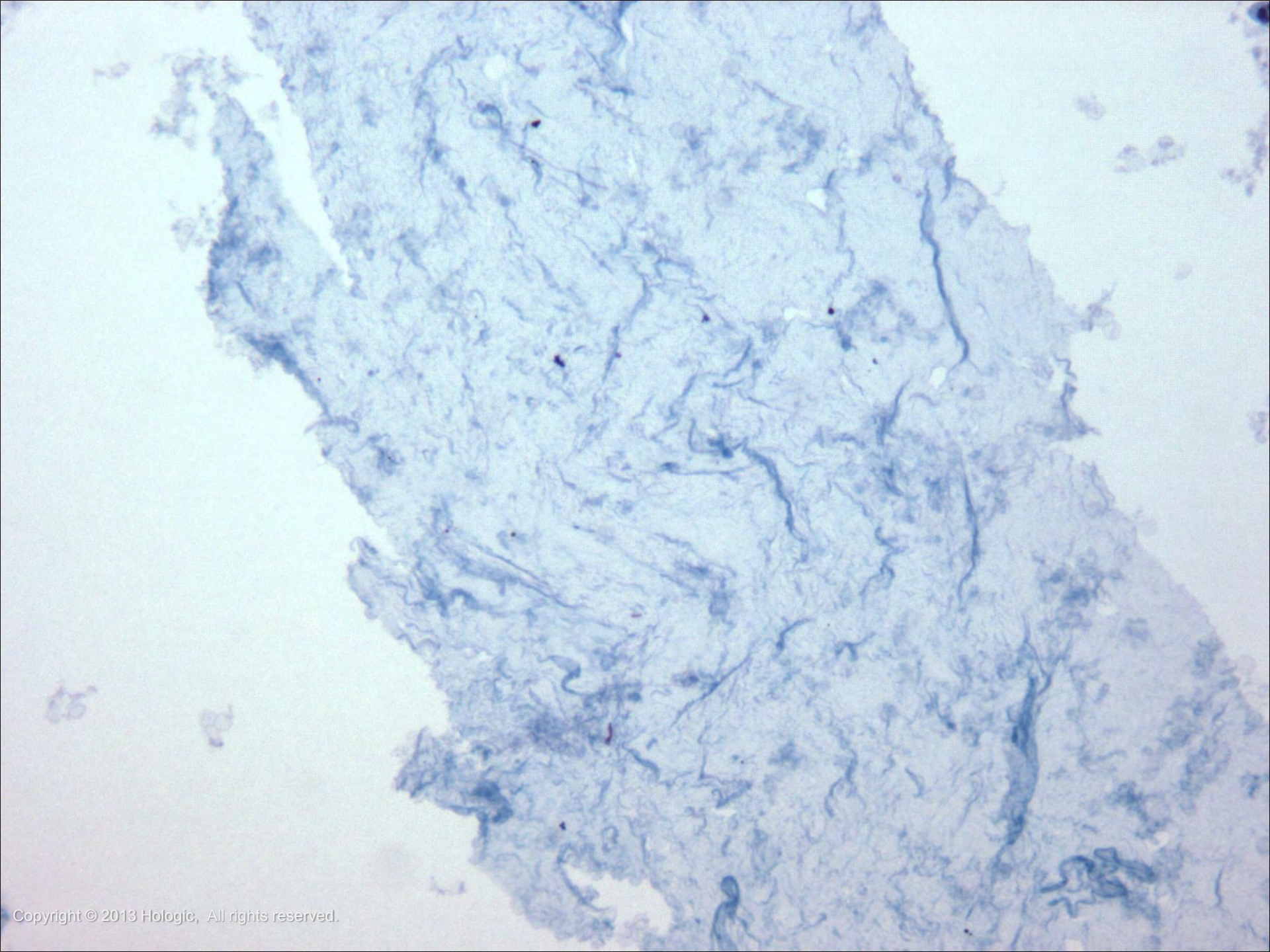
# Benign Findings-Epithelial Cytology

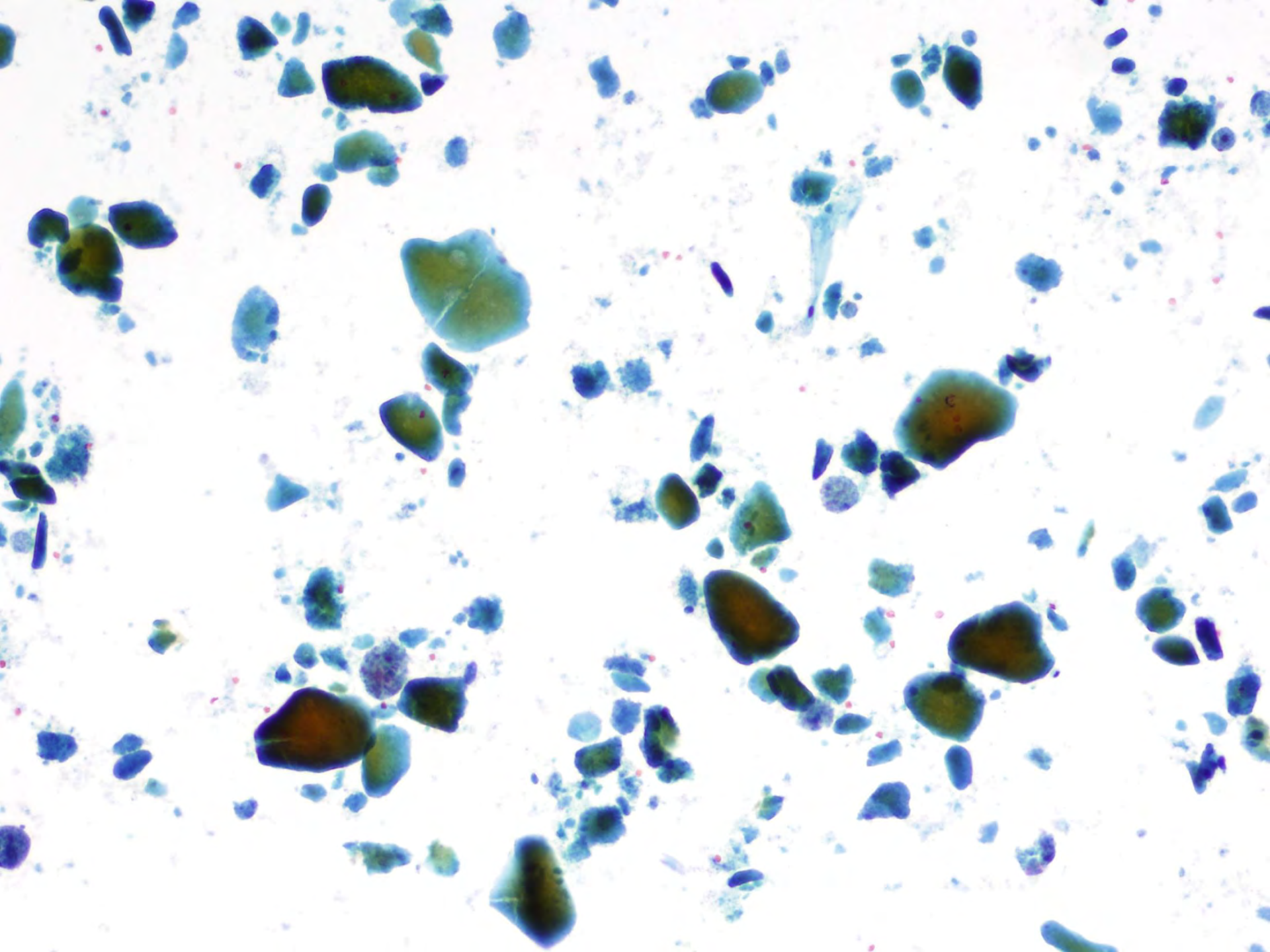
- Colloid Nodule
  - Abundant colloid
  - Minimal cellularity: very few or no follicular cells present

*Note: Be sure to distinguish colloid from serum*









# Benign Findings-Epithelial Overview

- Hyperplastic (adenomatoid) nodule
  - Subtype of nodular goiter nodule that consists predominantly of microfollicles
  - Represents a minority of nodular goiter nodules



# Benign Findings-Epithelial Cytology

- Hyperplastic (adenomatoid) nodule
  - Moderate to marked cellularity
  - Scant colloid
  - Predominance of microfollicles

*Note: Such cases are interpreted as “Follicular Neoplasm/Suspicious for Follicular Neoplasm” and represent one of the major limitations of FNA.*



# Benign Findings-Epithelial Overview

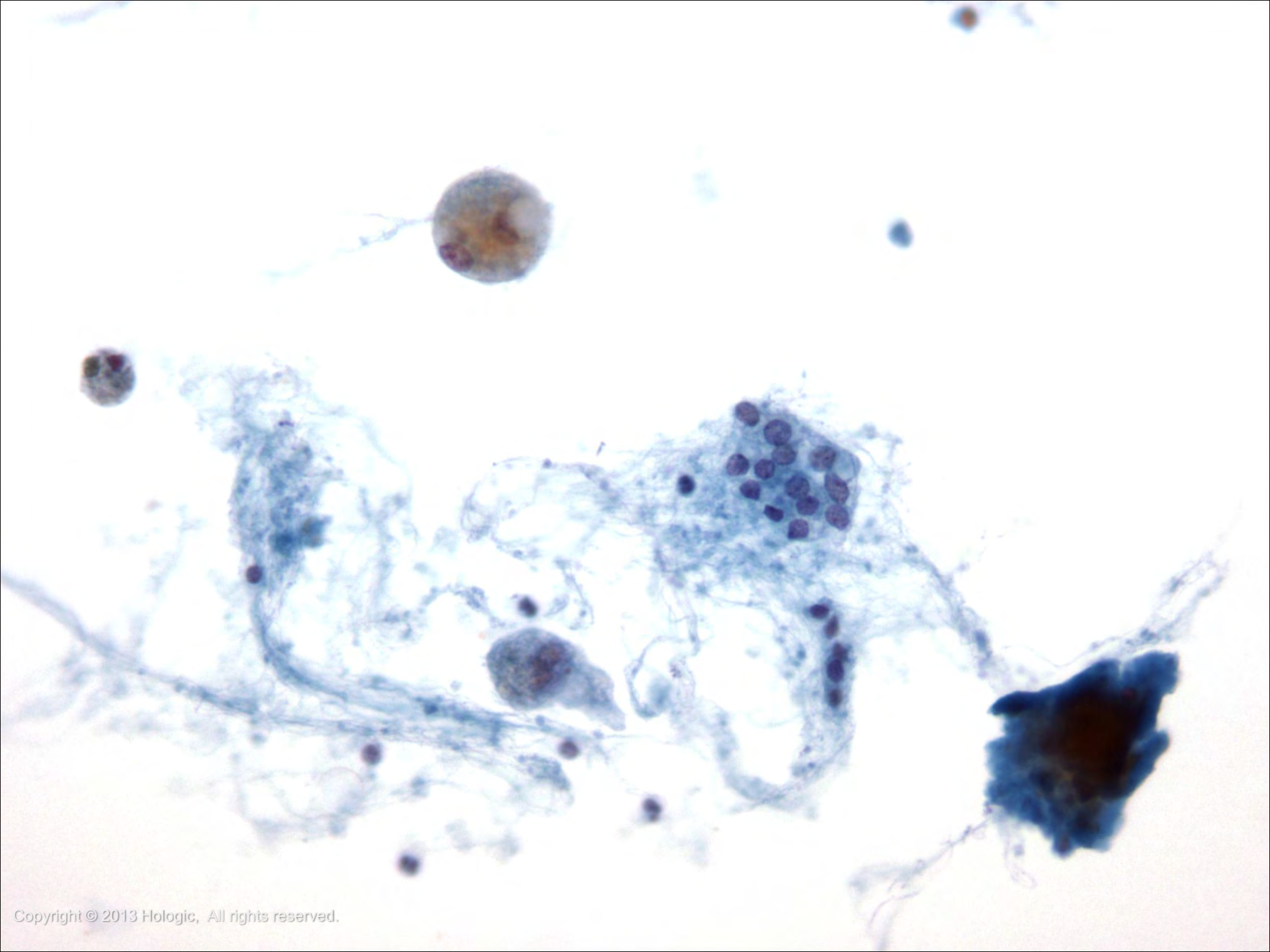
- Follicular Adenoma (macrofollicular type)
  - Most common thyroid neoplasm
  - Almost always a solitary nodule

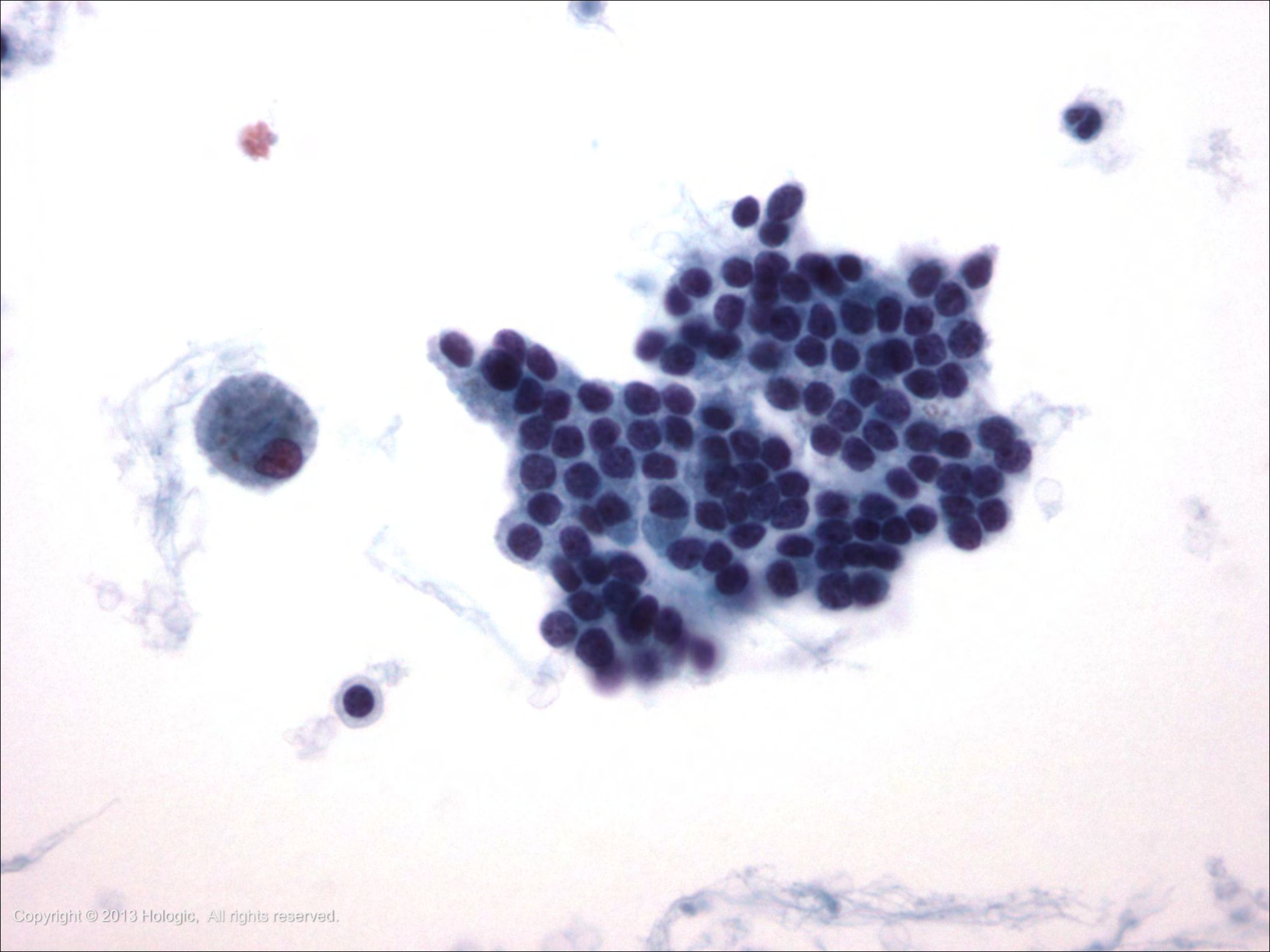


# Benign Findings-Epithelial Cytology

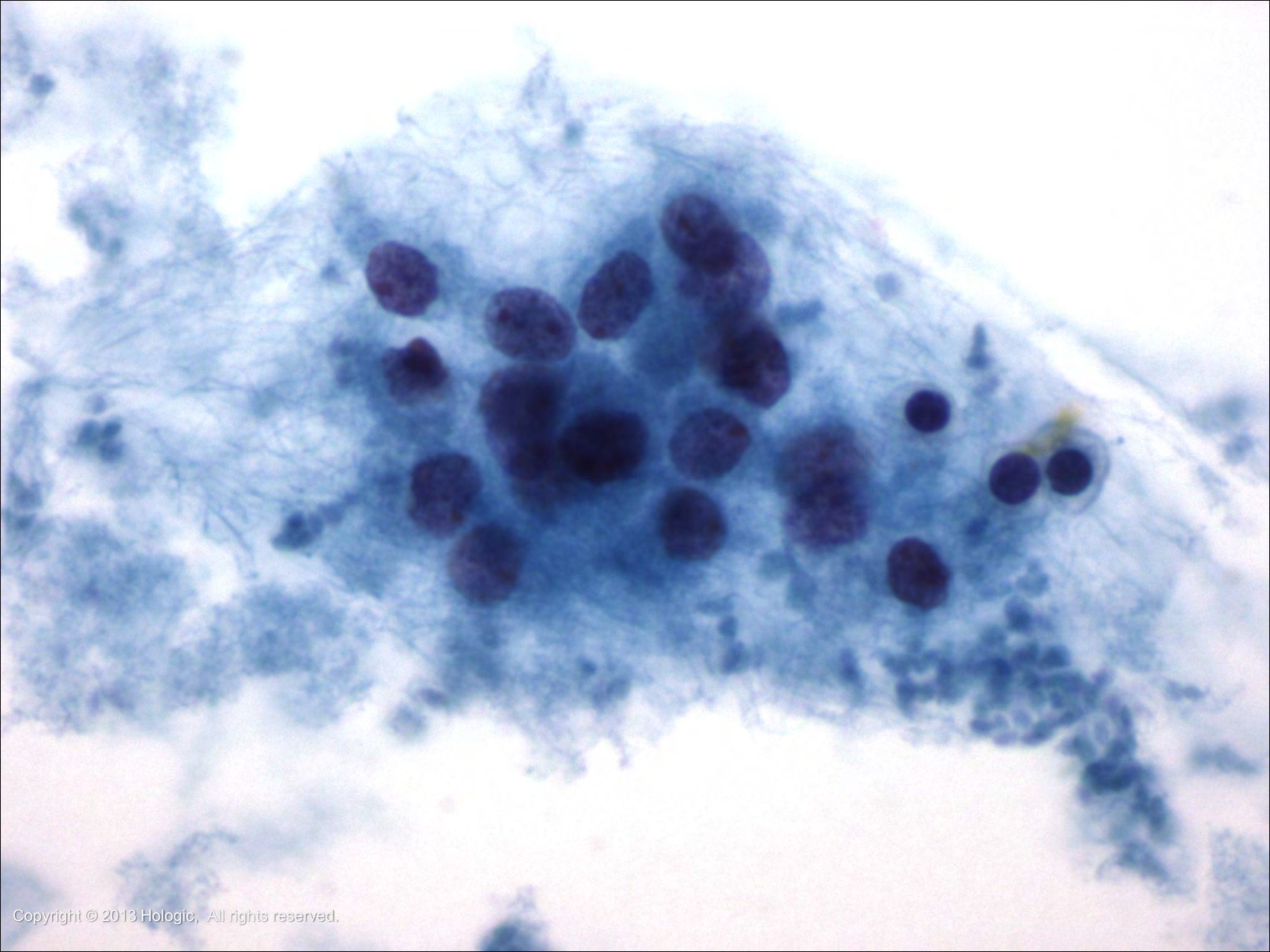
- Follicular Adenoma (macrofollicular type)
  - Variable cellularity
  - Follicular cells display benign features
  - Nuclei can be enlarged, coarsely granular, and hyperchromatic
  - The cytoplasm is finely granular
  - Hürthle cell variant











# Benign Findings-Epithelial Overview

- Graves' disease
  - Autoimmune disorder
  - Mainly affects middle-aged women
  - Commonly diagnosed clinically due to hyperthyroidism
  - Diffuse rather than nodular enlargement in the majority of patients



*continued on next slide*

# Benign Findings-Epithelial Overview

- Graves' disease - continued
  - FNA rarely performed
  - Risk factor for aggressive thyroid cancer, particularly when the nodule is cold (Papillary carcinoma the most common)
  - Drugs given to treat this disease may cause changes that can be confused with malignancy



# Benign Findings-Epithelial Cytology

- Graves' Disease
  - Cellular aspirate
  - Follicular cells
    - Variable number
    - Large flat sheets and rarely microfollicles
    - Abundant, foamy cytoplasm
    - Enlarged vesicular nuclei with frequent anisonucleosis and prominent nucleoli
    - Infrequently, chromatin clearing and intranuclear grooves can be seen which can be confused with papillary carcinoma



*continued on next slide*

# Benign Findings-Epithelial Cytology

- Graves' Disease - continued
  - Abundant pale watery colloid
  - If the patient has been treated, atypical follicular cells can be present and confused with malignancy
  - Lymphocytes (usually T cells) and Hürthle cells
  - Flame cells (Romanowsky stains)



# Atypia of Undetermined Significance

## Overview

- Alternative name: Follicular Lesion of Undetermined Significance
  - The degree of atypia is not severe enough to warrant a suspicious or malignant diagnosis
  - Clinical correlation and repeat FNA are the usual management



# Atypia of Undetermined Significance Cytology

Several different patterns:

- Predominance of microfollicles in a sparsely cellular sample
- Exclusively Hürthle cells in a sparsely cellular sample
- Exclusively Hürthle cells in a patient with Hashimoto thyroiditis or multinodular goiter



*continued on next slide*

# Atypia of Undetermined Significance Cytology

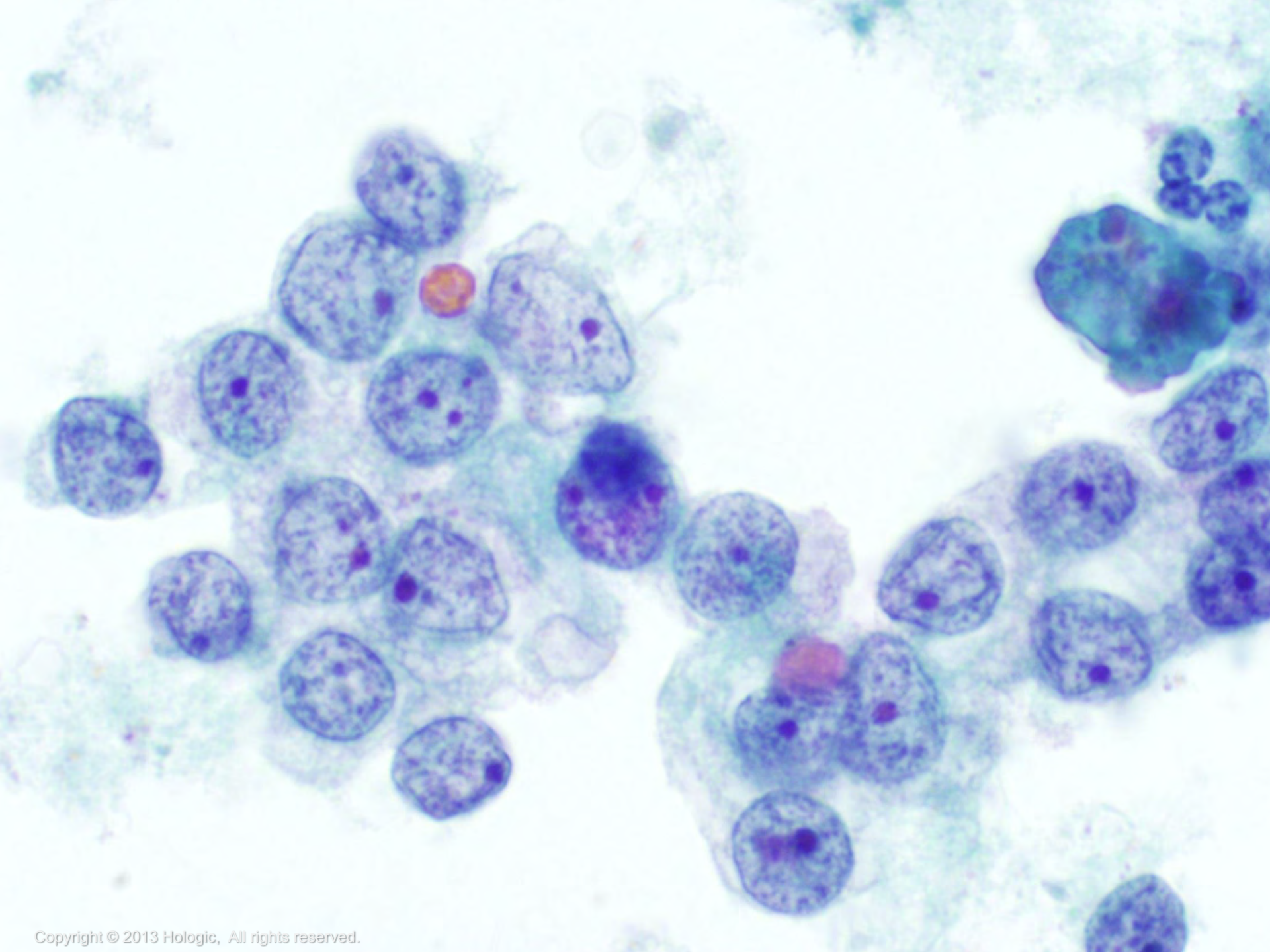
## Several different patterns - continued

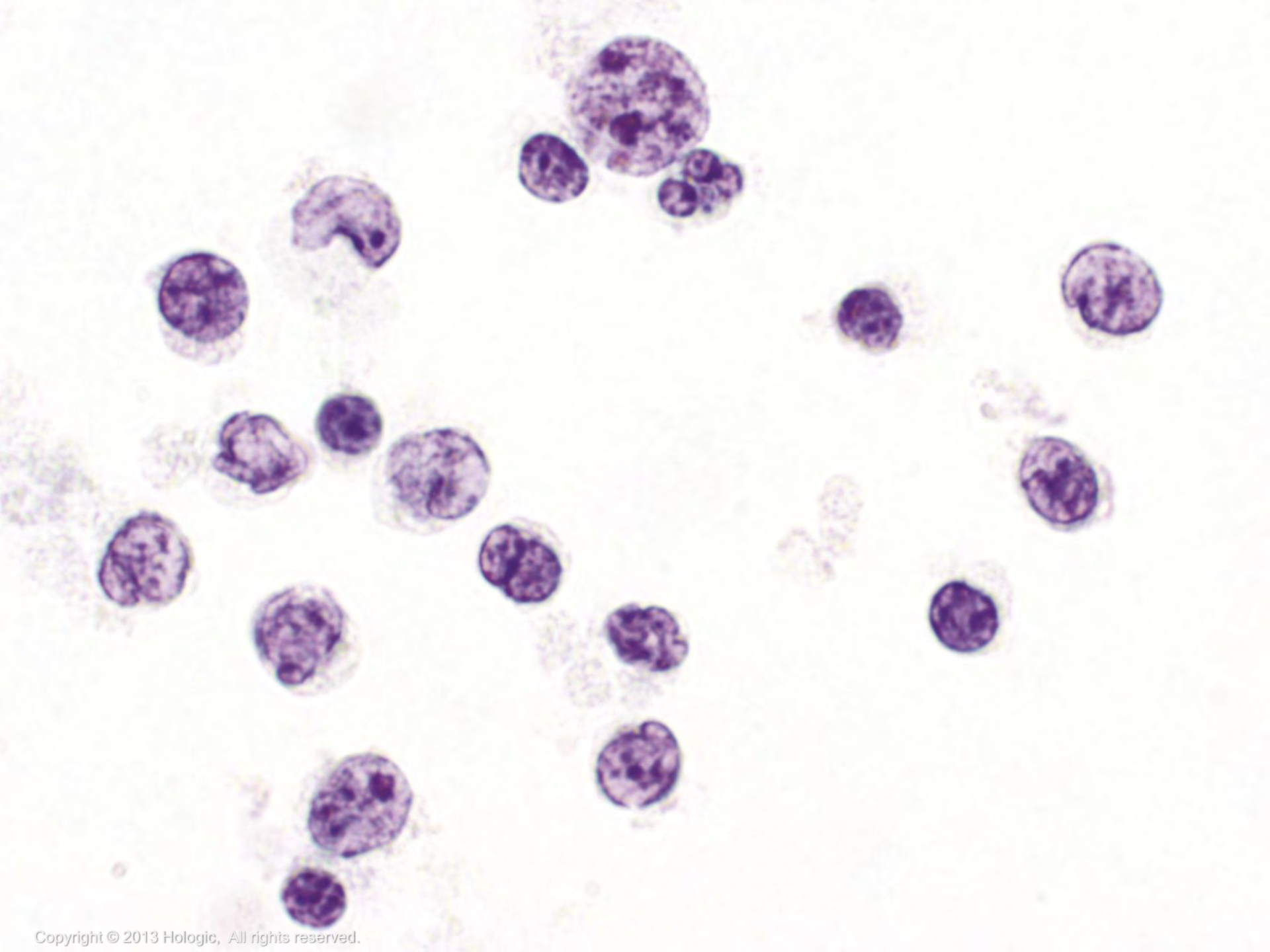
- Atypia obscured by preparation artifact; atypical cyst lining cells; marked nuclear enlargement with prominent nucleoli
- Cells with mild nuclear atypia (e.g., in Hashimoto thyroiditis)
- Atypical lymphoid infiltrate (flow cytometry needed)











# Suspicious Findings Types

- Suspicious for Follicular Neoplasm  
*Synonym: Follicular Neoplasm*
- Suspicious for Follicular Neoplasm,  
Hürthle cell type  
*Synonym: Follicular Neoplasm, Hürthle  
cell type*
- Suspicious for Papillary Carcinoma
- Suspicious for Medullary Carcinoma



# Suspicious for Follicular Neoplasm Overview

- Follicular carcinoma is the second most common malignancy of the thyroid
- If well-differentiated, a good prognosis
- Impossible to diagnose invasion on FNA, so can only triage worrisome patterns to surgery



*continued on next slide*

# Suspicious for Follicular Neoplasm Overview

continued

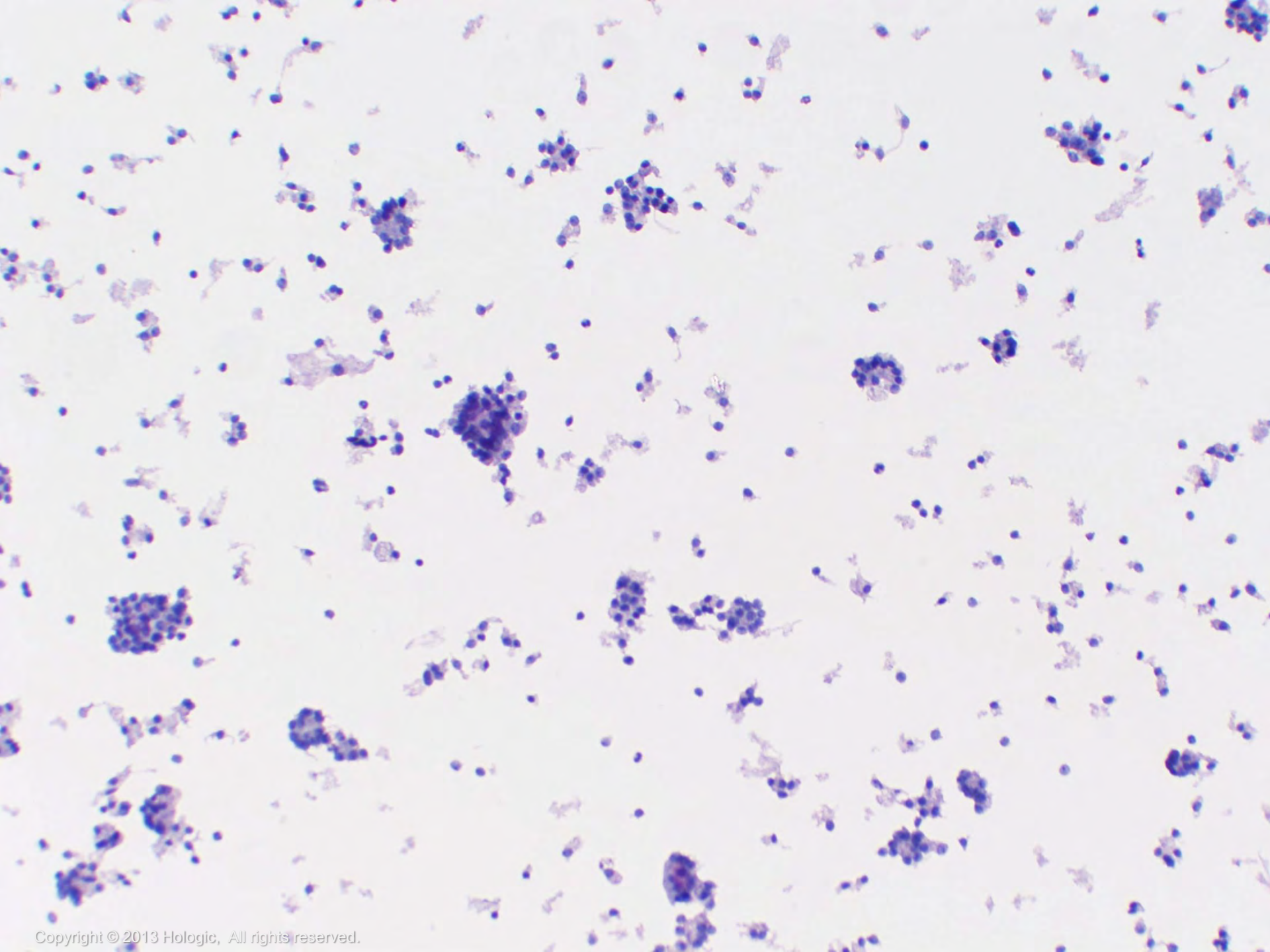
- Most FNAs triaged to surgery with this diagnosis prove to be benign
- FNA has high sensitivity but low specificity for follicular carcinoma, therefore it's considered a screening rather than diagnostic test for this diagnosis
- Lobectomy is the usual management for this diagnosis



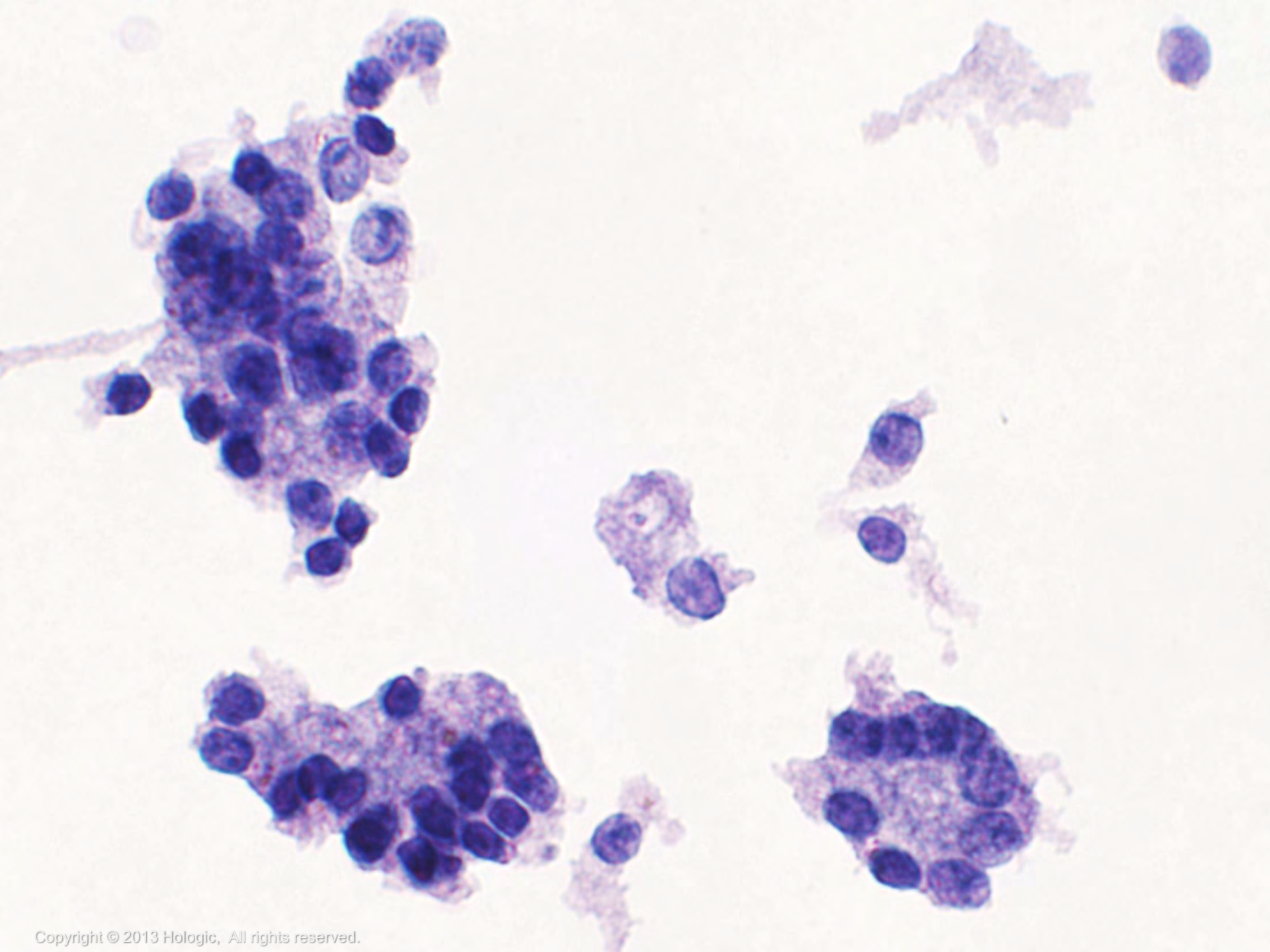
# Suspicious for Follicular Neoplasm Cytology

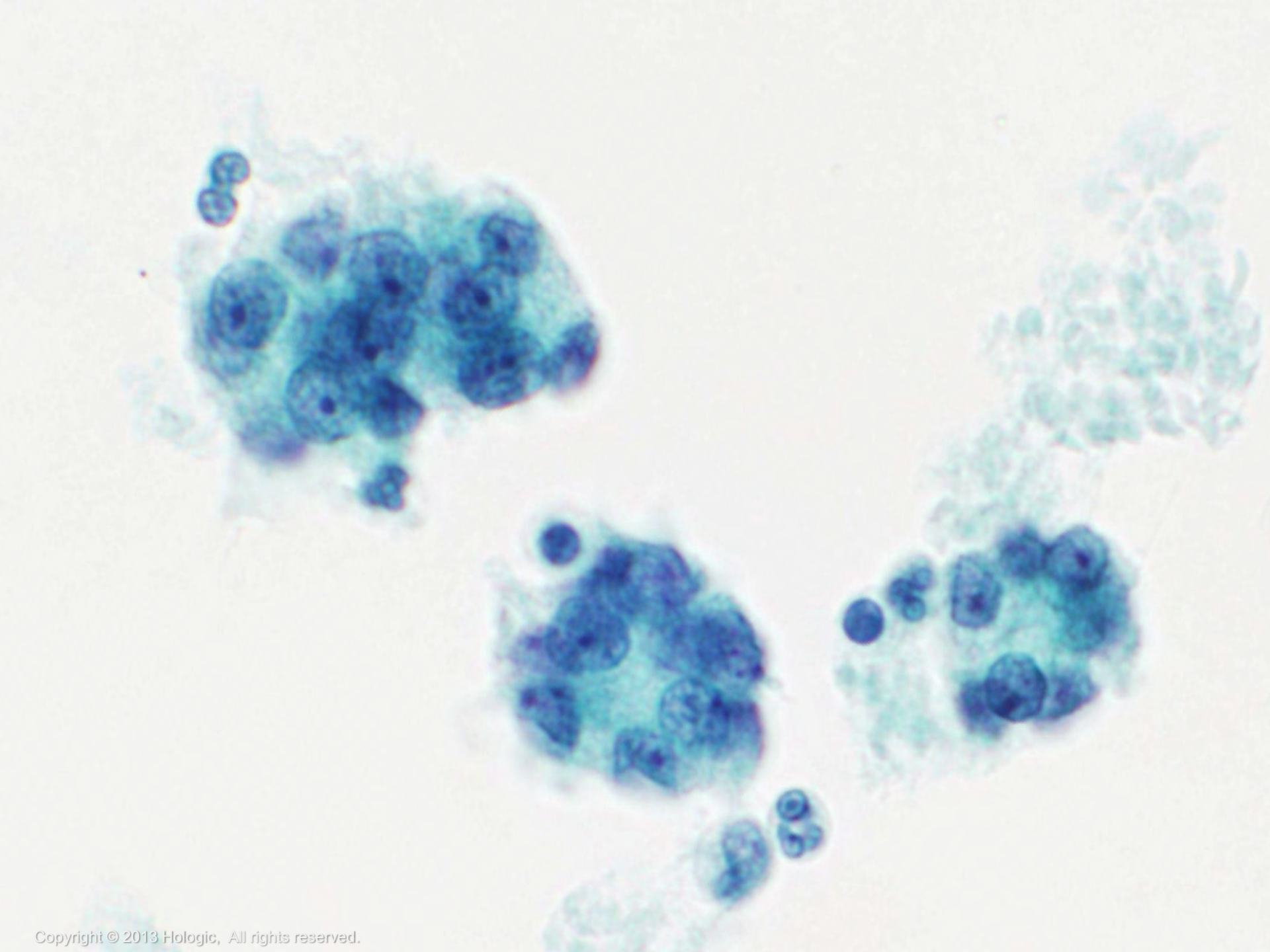
- Moderate to marked cellularity
- Little or no colloid
- **Significant architectural changes:**
  - Predominance of microfollicles and/or trabeculae
- Cell crowding and overlapping
- Hyperchromasia, anisonucleosis, and prominent nucleoli may be present but are not essential for diagnosis











# Suspicious for Follicular Neoplasm, Hürthle Cell Type Overview

- Uncommon subset of follicular neoplasm composed exclusively (or virtually exclusively) of oncocytic cells
- The majority prove to be adenomas rather than carcinomas



# Suspicious for Follicular Neoplasm, Hürthle Cell Type Cytology

- Polygonal cells
- Isolated cells or three-dimensional groups (loosely cohesive or crowded)
- Abundant dense, granular cytoplasm
- Nuclei are round and eccentrically placed with a prominent central nucleolus



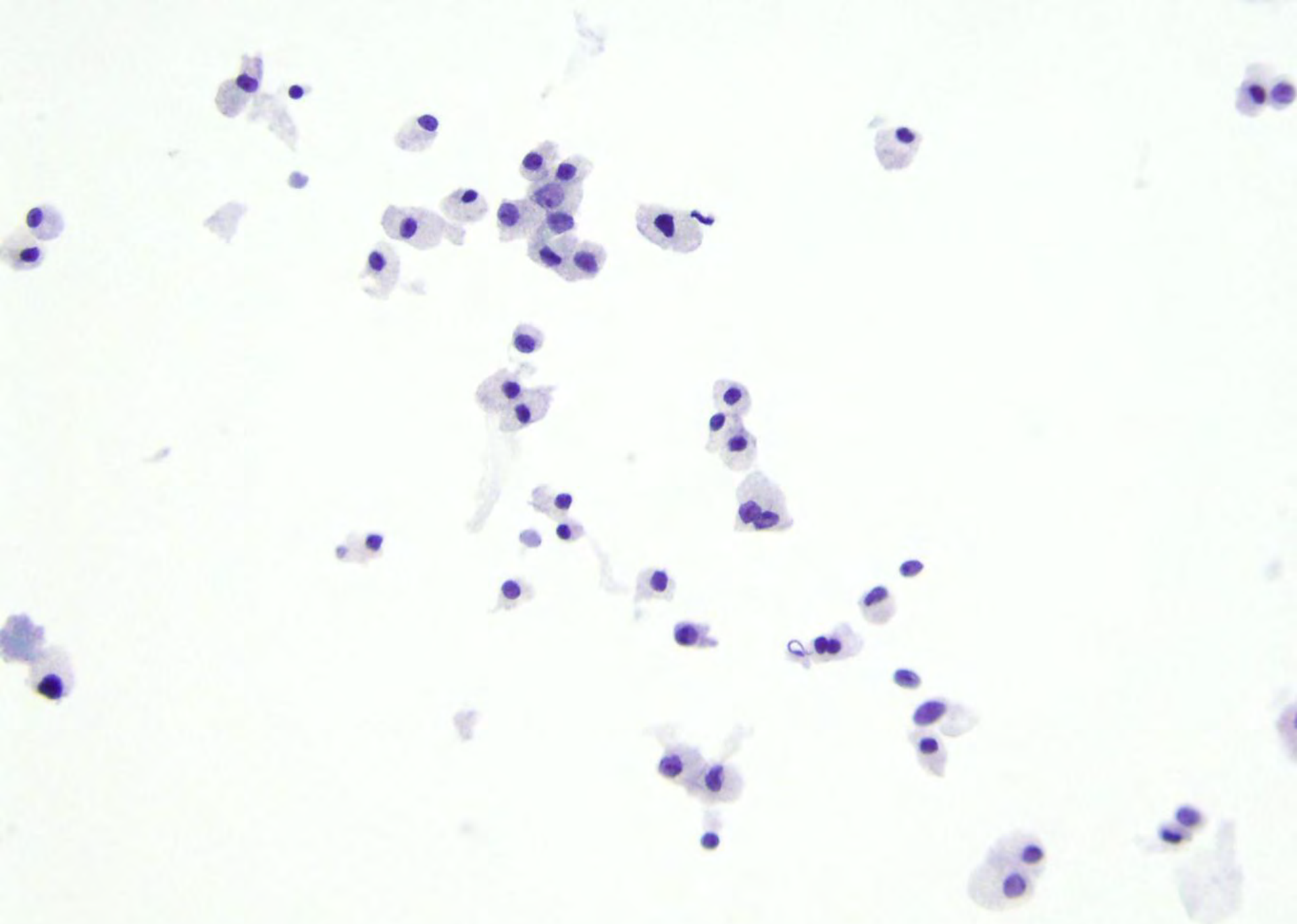*continued on next slide*

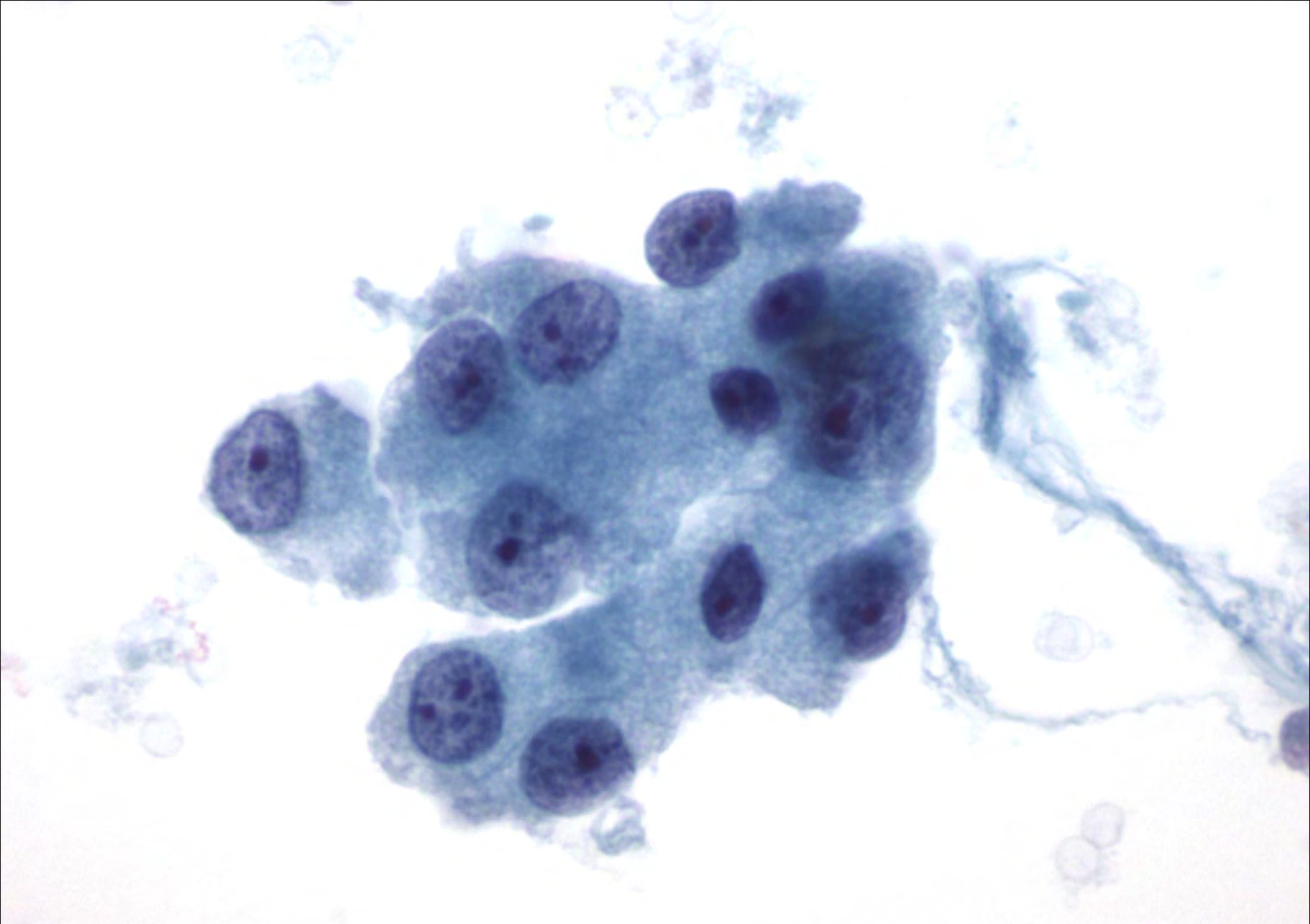
# Suspicious for Follicular Neoplasm, Hürthle Cell Type Cytology

continued

- Plasmacytoid appearance
- Occasional binucleation
- Variation in size of cells and nuclei can occur
- Colloid scant or absent
- No increase in lymphocytes







# Suspicious for Papillary Carcinoma Overview

- Suspicious for Papillary Carcinoma
  - Subjective diagnosis used when criteria falls short of a malignant diagnosis
  - Suboptimal sampling
  - Suboptimal preservation
  - Unusual presentation
  - Insufficient quality or quantity





# Suspicious for Papillary Carcinoma Cytology

## First pattern:

- A moderate to highly cellular specimen composed of benign follicular cells that are arranged predominantly in macrofollicular sheets. Only some of the cells display the following features of papillary carcinoma;
  - Nuclear enlargement, pallor, grooves, membrane irregularities and/or molding with the exception of intranuclear pseudoinclusions which are rare or absent



# Suspicious for Papillary Carcinoma Cytology

## Second pattern:

- A specimen with variable cellularity displaying the following nuclear changes associated with papillary carcinoma, however;
  - Nuclear enlargement and pallor are only mild to moderately displayed
  - Nuclear membrane irregularities, molding and intranuclear pseudoinclusions are minimal or absent
  - Nuclear grooves are conspicuous



# Suspicious for Papillary Carcinoma Cytology

Third pattern:

- A very sparsely cellular sample with many features of papillary carcinoma present



# Suspicious for Papillary Carcinoma Cytology

## Fourth pattern:

- Follicular cells are arranged in groups and sheets
- Nuclei are enlarged and pale with some grooves
- Intranuclear pseudoinclusions are rare or absent
- Hemosiderin laden macrophages are present
- Large, vacuolated atypical histiocytoid cells with enlarged nuclei
- Rare psammoma body like calcifications



# Suspicious for Medullary Carcinoma Overview & Cytology

- Subjective diagnosis used when criteria falls short of a malignant diagnosis
- Suboptimal preservation can lead to smudged chromatin and overall cell degeneration
- Can be confused with a lymphoid lesion due to the single cell population of loosely cohesive/single cells with high n/c ratios
- Insufficient quantity or unusual presentation
- Immunocytochemical stains and serum calcitonin level of the patient can be helpful



# Malignant Findings Types

- Papillary Carcinoma
- Hyalinizing Trabecular Tumor
- Medullary Thyroid Carcinoma
- Poorly Differentiated Carcinoma
- Undifferentiated (Anaplastic) Carcinoma
- Squamous Cell Carcinoma
- Primary Lymphomas
- Metastatic Carcinomas and Lymphomas



# Malignant Findings Overview

- Papillary Carcinoma
  - Most common malignancy of the thyroid
  - Can occur at any age, including childhood
  - More common in women than men
  - Good prognosis
  - Flat sheets mimic benign macrofollicular fragments. **Nuclear detail must be examined**
  - Many of the following criteria must be present in order to make the diagnosis of papillary carcinoma



# Malignant Findings

## Cytology

- Papillary Carcinoma
  - Syncytial-like flat sheets and papillary groups
    - Sometimes in a swirling pattern
  - Increased cellularity with crowding and overlapping
  - Nuclei are enlarged, pale, round to oval or irregular in shape and display grooves and molding
  - Chromatin is pale and powdery with micronucleoli

*continued on next slide*

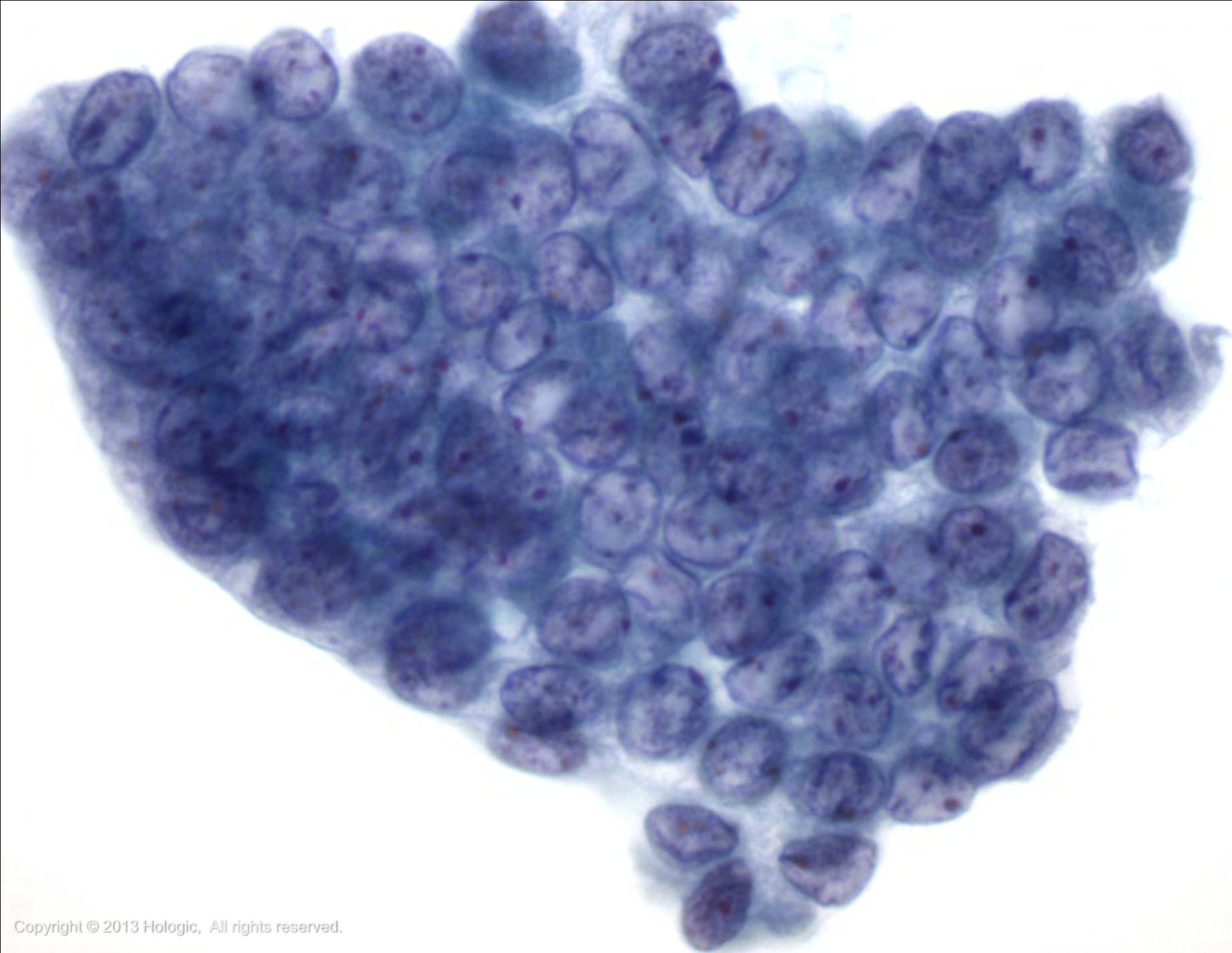


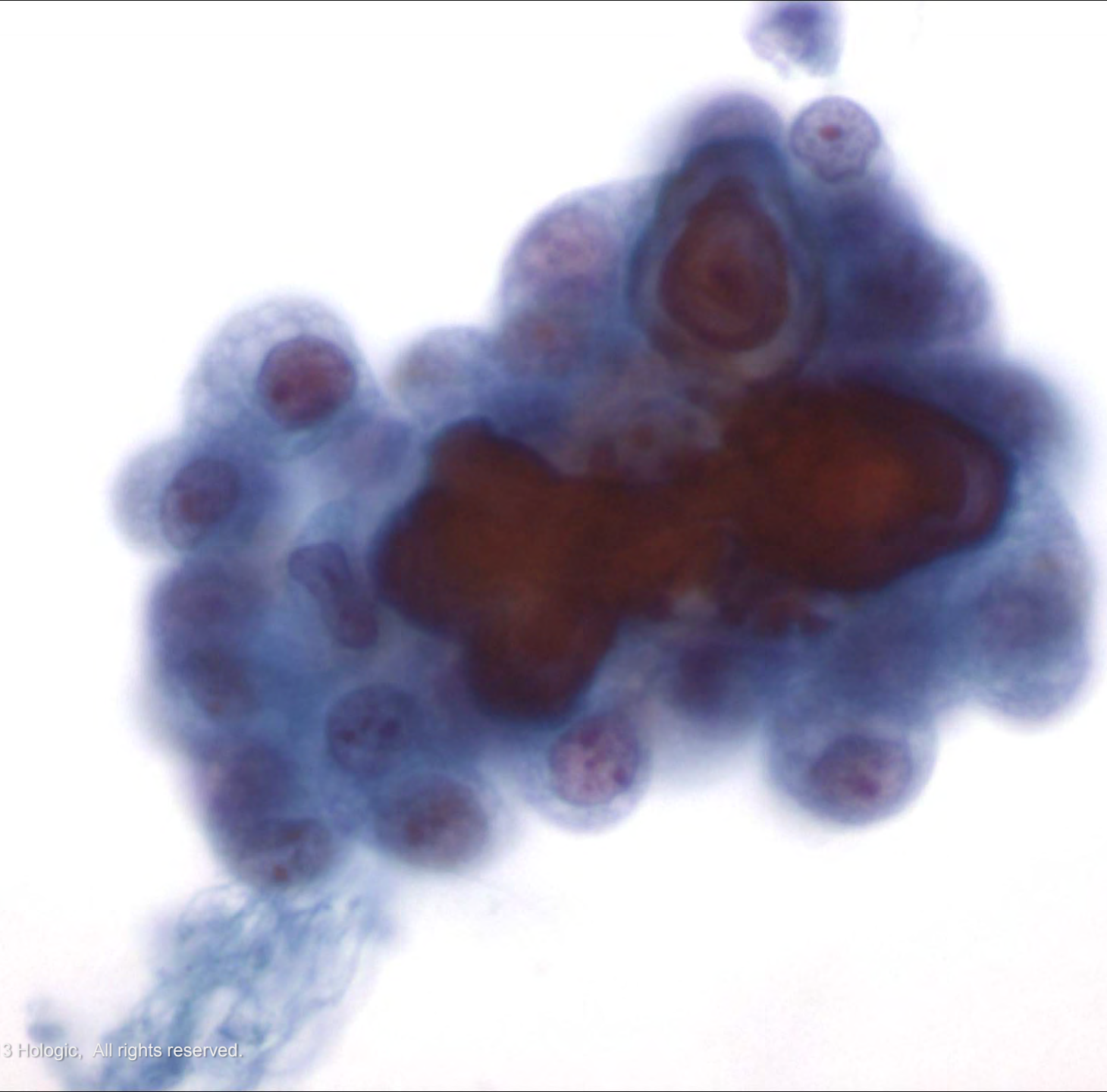


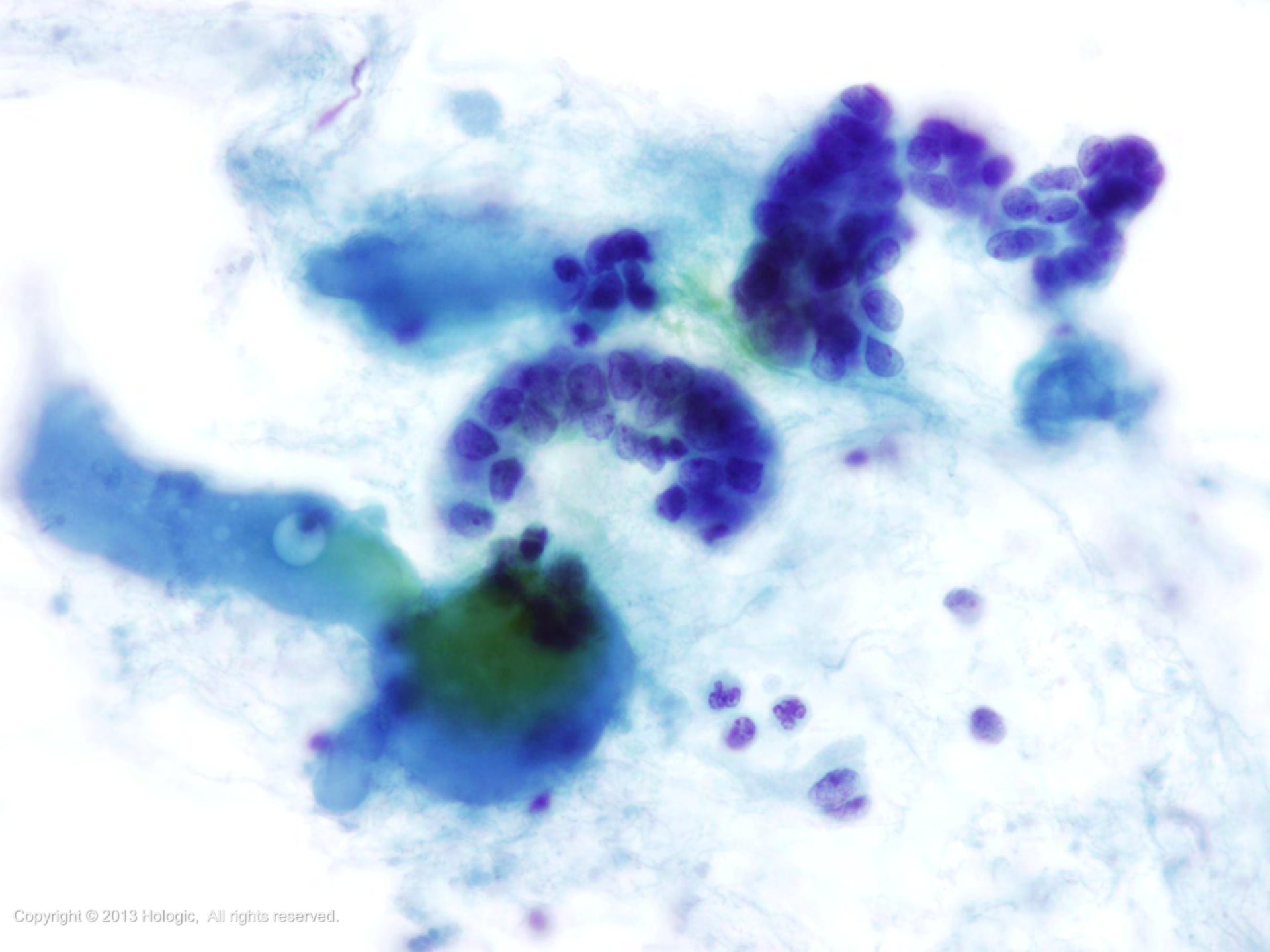
# Malignant Findings Cytology

- Papillary Carcinoma - continued
  - Intranuclear cytoplasmic inclusions (can also be seen in other thyroid neoplasms)
  - Psammoma bodies are rare
  - Multinucleated giant cells often present
  - Colloid may be present
  - Hürthle cells and hemosiderin-laden macrophages can be seen









# Malignant Findings Overview

- Papillary Carcinoma Variants
  - Variants have the same abnormal features of papillary carcinoma, but with architectural, background, or cytoplasmic differences
  - Some variants carry a different prognosis
  - Not necessary to subtype papillary carcinoma by FNA because the initial management of all subtypes is the same (total thyroidectomy)
  - Histopathologic examination permits definitive subtyping



# Malignant Findings Cytology

- Papillary Carcinoma Variants
  - *Follicular variant*
    - Nuclear features are more subtle
    - Cells arranged in microfollicles



# Malignant Findings

## Cytology

- Papillary Carcinoma Variants
  - *Cystic variant*
    - Neoplastic follicular cells have abundant granular or vacuolated cytoplasm
    - Cystic background of watery colloid and hemosiderin-laden macrophages



# Malignant Findings Cytology

- Papillary Carcinoma Variants

- *Warthin-like variant*

- Neoplastic cells have oncocytic cytoplasm
    - Increased number of lymphocytes.

*When lymphocytes are admixed with neoplastic cells, be sure the changes are truly malignant and not just reactive*





# Malignant Findings Cytology

- Papillary Carcinoma Variants
  - *Oncocytic variant*
    - Abundant oncocytic (granular) cytoplasm dominates
    - No increase in lymphocytes



# Malignant Findings

## Cytology

- Papillary Carcinoma Variants
  - *Tall cell variant*
    - At least half of the neoplastic cells are elongated (at least 2-3 times as long as they are wide)
    - Abundant granular cytoplasm
    - Intranuclear cytoplasmic inclusions are frequent and often multiple. Occasional lymphocytes may be seen
    - Worse prognosis



# Malignant Findings Cytology

- Papillary Carcinoma Variants
  - *Macrofollicular variant*
    - Nuclear features are more subtle
    - Macrofollicular sheets make up at least half of the specimen



# Malignant Findings

## Cytology

- Papillary Carcinoma Variants
  - *Columnar cell variant*
    - Elongated, columnar, stratified, crowded cells
    - Less cytoplasm than the tall cell variant (higher n:c ratio)
    - Nuclei are hyperchromatic, oval, and uniform
    - Discreet nucleoli
    - Nuclear features of papillary carcinoma are more subtle
    - Very rare
    - Worse prognosis



# Malignant Findings Overview & Cytology

- Hyalinizing Trabecular Tumor
  - Controversial, rare neoplasm
  - Some consider it a variant of papillary carcinoma
  - Difficult to diagnose cytologically
  - Histopathology: tight groups of cells with a core of hyaline stromal material



*continued on next slide*

# Malignant Findings Overview & Cytology

- Hyalinizing Trabecular Tumor-continued
  - Many of the same features of papillary carcinoma including: psammoma bodies, intranuclear cytoplasmic inclusions, nuclear grooves
  - Most are interpreted as malignant or suspicious for papillary carcinoma by FNA



# Malignant Findings Types

- Medullary Thyroid Carcinoma
  - Many histologic variants (not necessary to subtype)
    - Small cell, papillary, follicular/glandular, spindle cell, oncocytic, clear cell, giant cell, mixed follicular/medullary (parafollicular), neuroblastoma like, paraganglioma like, angiosarcoma like, melanin producing, amphicrine, squamous cell



# Malignant Findings Overview

- Medullary Thyroid Carcinoma
  - Sporadic or familial
  - Tumor of the parafollicular C cells
  - Elevated serum calcitonin levels
  - Congo red stain for amyloid and immunohistochemical stains aid in the diagnosis
    - Immunohistochemistry:
      - *Positive:* calcitonin, CEA, chromogranin, synaptophysin
      - *Negative:* thyroglobulin





# Malignant Findings

## Cytology

- Medullary Thyroid Carcinoma
  - Isolated, noncohesive cells are the predominant pattern
  - Cell clusters can be present
  - Cells may be many different shapes: round, polygonal, plasmacytoid, and spindled
  - Amyloid is frequently present and stains red with Congo red stain, but when polarized light is applied changes to apple-green

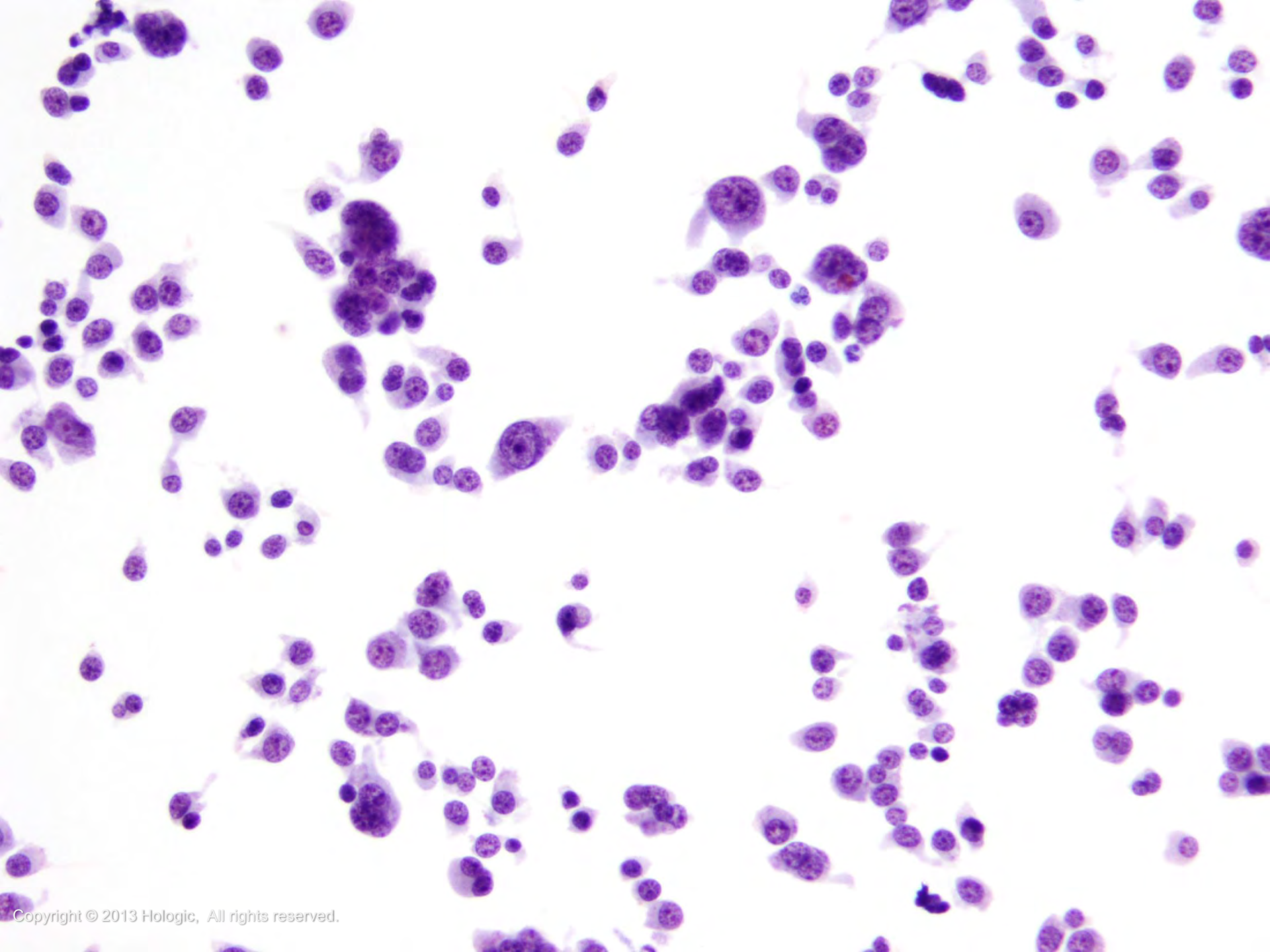


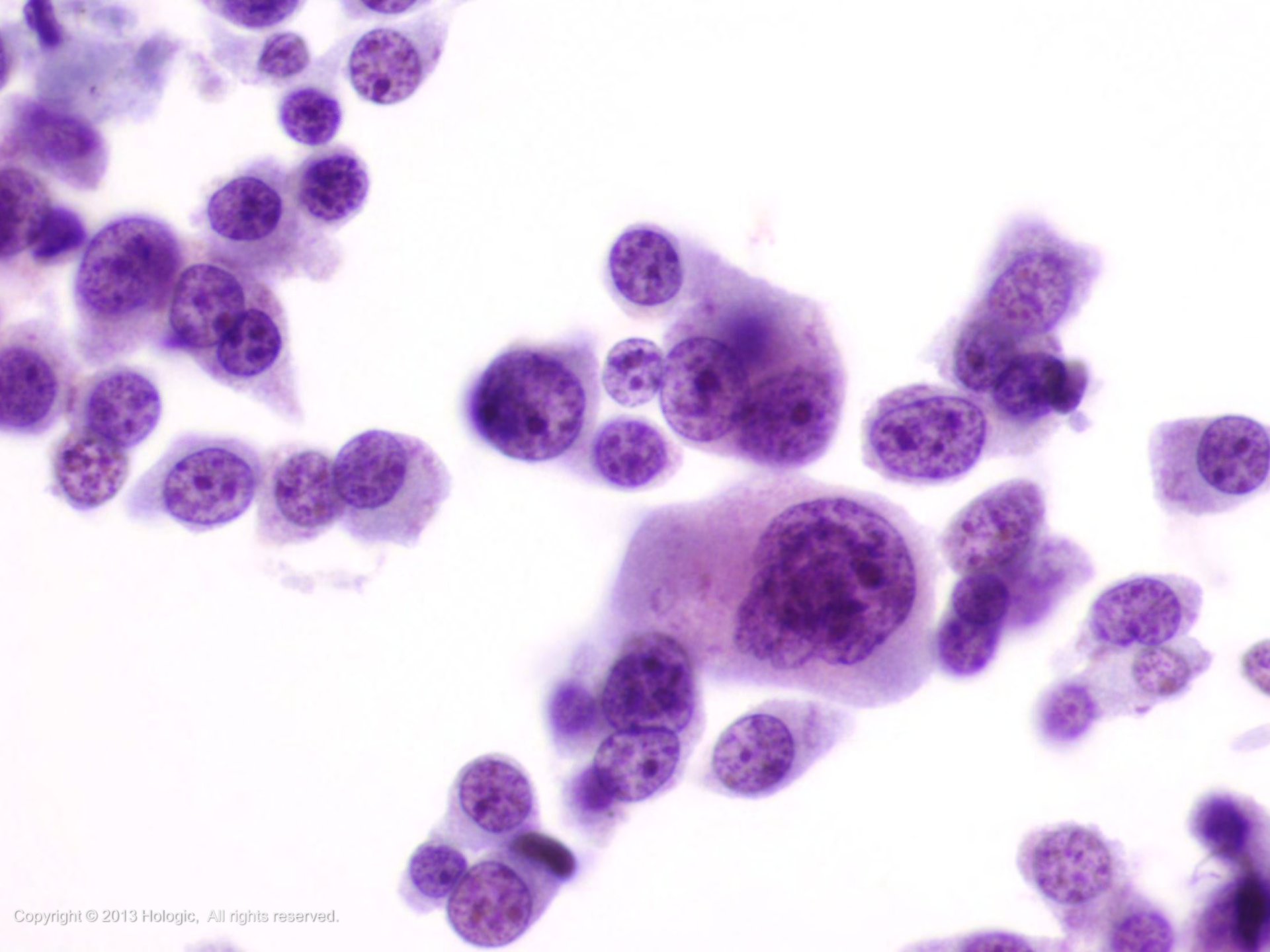
*Continued on next slide*

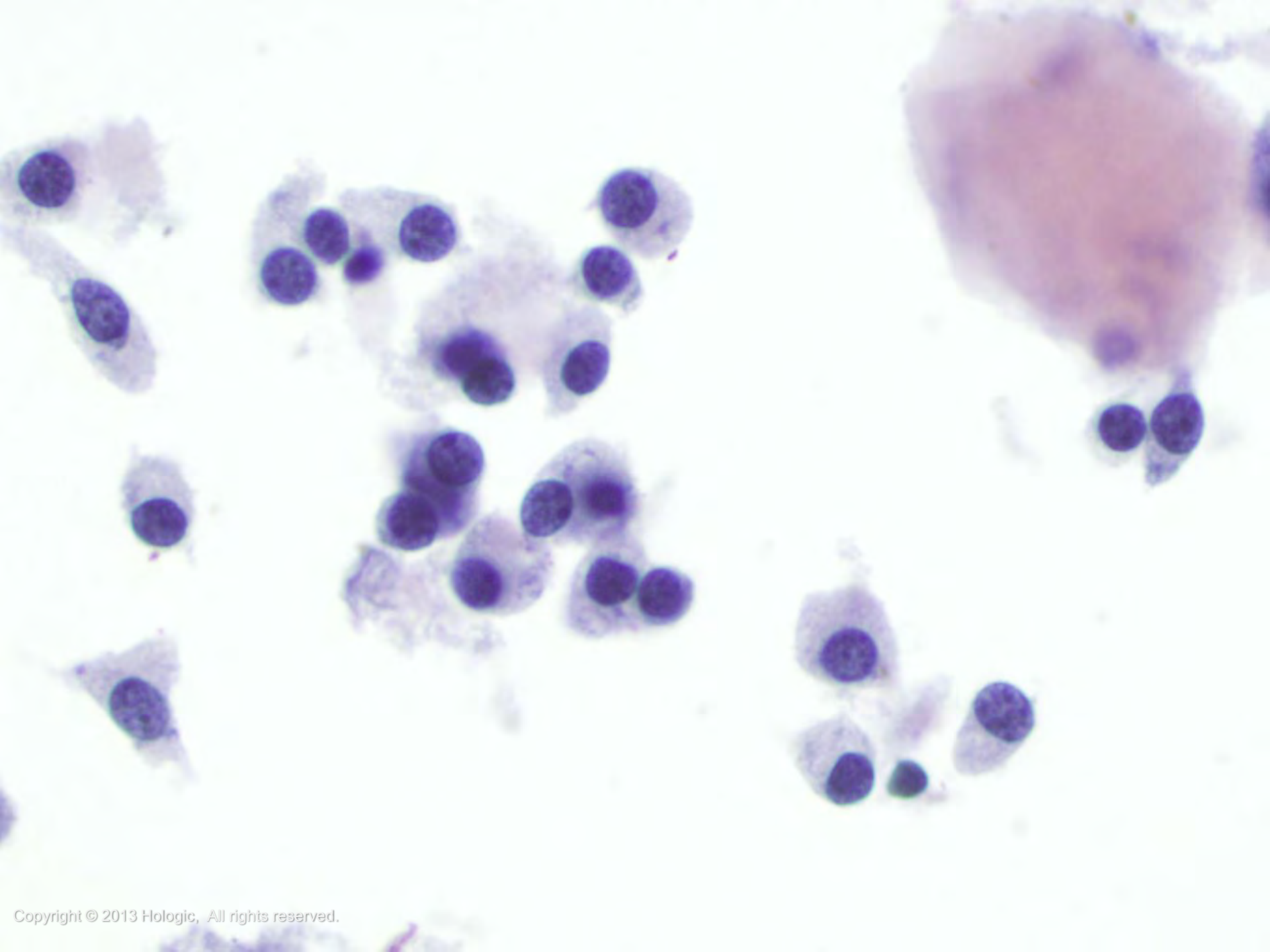
# Malignant Findings Cytology

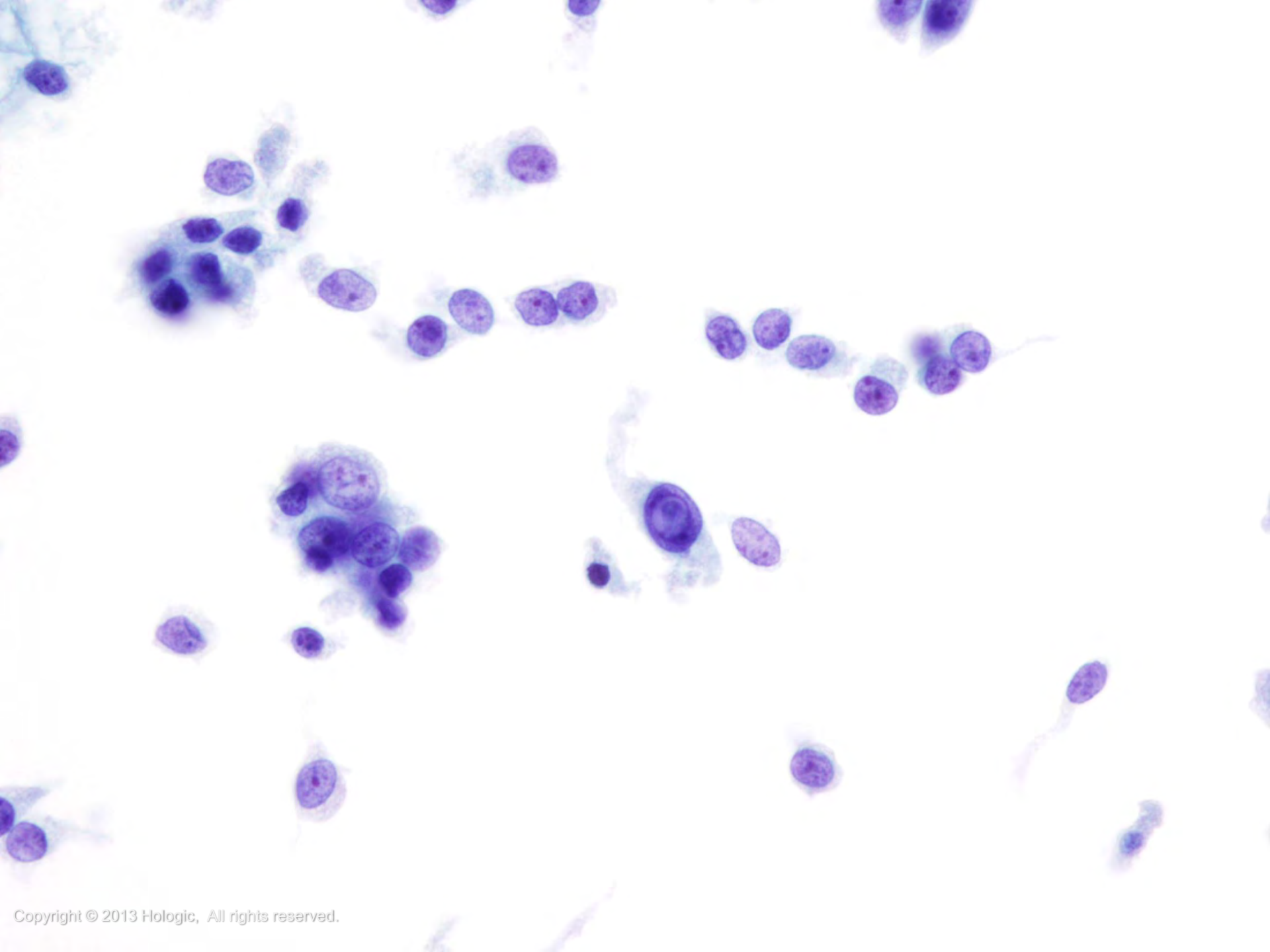
- Medullary Thyroid Carcinoma
  - Binucleation and multinucleation common
  - Nuclei eccentrically located and typically round to oval
  - Spindle cell variant: elongated nuclei
  - Chromatin is coarsely granular with small nucleoli (less frequently, prominent nucleoli)
  - Cytoplasm commonly abundant and finely granular
  - Nuclear pseudoinclusions may be seen

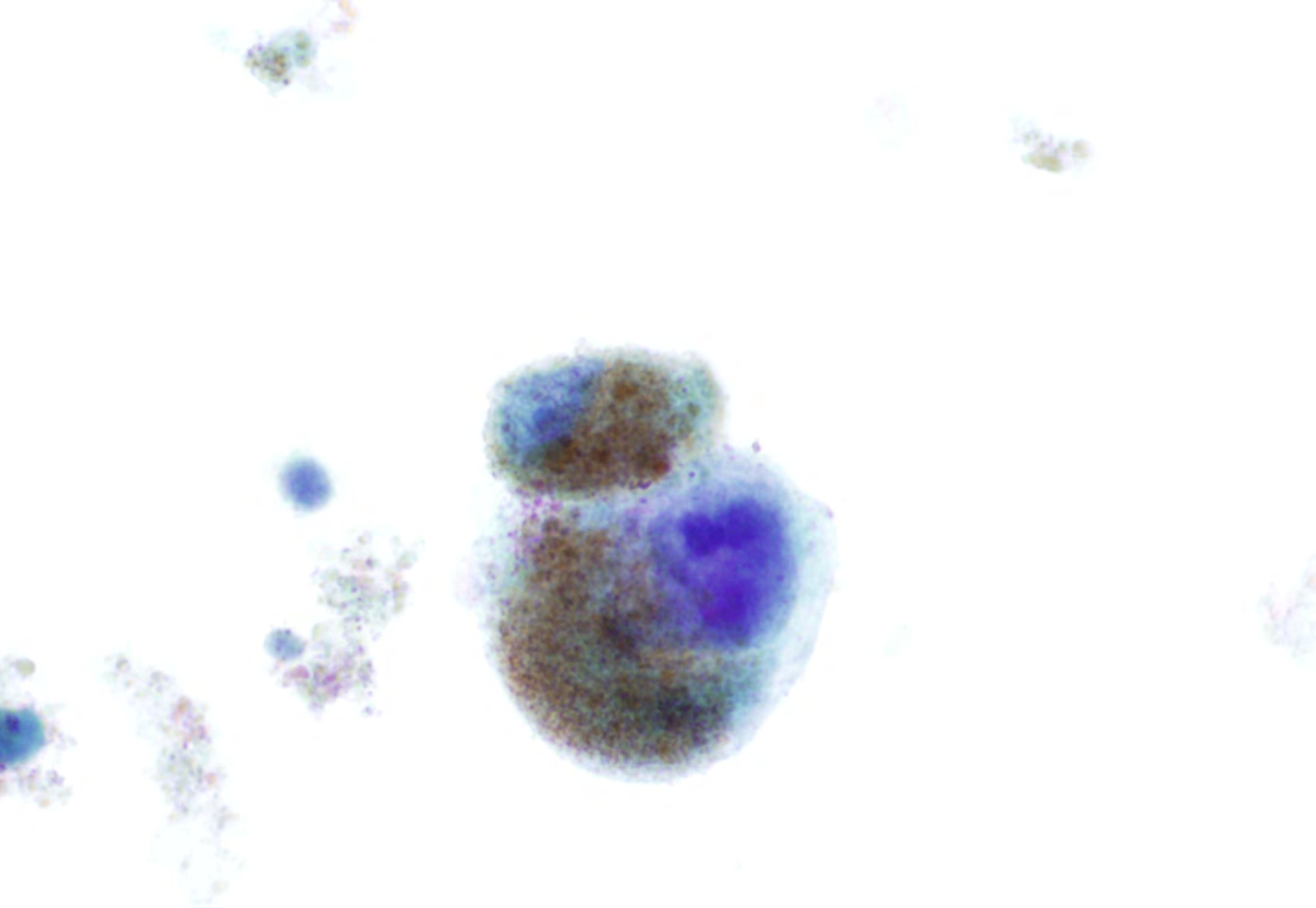












# Malignant Findings Overview

- Poorly Differentiated Carcinoma
  - Rare, aggressive malignancy of follicular cell origin
  - Can co-exist with a well differentiated carcinoma (papillary or follicular) and/or undifferentiated (anaplastic) carcinoma
  - Patients usually present with advanced disease



*continued on next slide*



# Malignant Findings Overview

- Poorly Differentiated Carcinoma-continued
  - Lymph node, lung, and bone metastases common
  - Difficult to diagnose by FNA; most often called “suspicious for a follicular neoplasm”
  - Immunohistochemistry:
    - *Positive*: Thyroglobulin, TTF-1, and cytokeratin
    - *Negative*: Calcitonin



# Malignant Findings Cytology

- Poorly Differentiated Carcinoma
  - Markedly cellular
  - Cells are arranged singly, in crowded groups, papillary-like aggregates, or microfollicles, and can be wrapped by endothelium, creating insulae or trabeculae
  - Naked nuclei, necrosis, and mitoses are often present



*continued on next slide*

# Malignant Findings Cytology

- Poorly Differentiated Carcinoma - continued
  - Cytoplasm is scant
  - Cells often have a plasmacytoid appearance
  - Nuclei are round and frequently display variation in both size and shape with irregular nuclear borders, granular to coarse chromatin with varying sizes of nucleoli



# Malignant Findings Overview

- Undifferentiated (Anaplastic) Carcinoma
  - Rapidly growing, very aggressive
  - >age 50, more common in women than men
  - Rapid tumor growth infiltrates into surrounding soft tissues of the neck



*continued on next slide*

# Malignant Findings Overview

- Undifferentiated (Anaplastic) Carcinoma - continued
  - Common site for metastasis is the lung
  - A secondary co-existing thyroid carcinoma may be present in some cases
- Immunocytochemistry:
  - *Positive*: Pan-keratin, PAX8 (often positive)
  - *Negative*: TTF-1 and thyroglobulin (both are usually negative but can be focally or weakly positive)



# Malignant Findings

## Cytology

- Undifferentiated (Anaplastic) Carcinoma
  - Cellularity variable; can be low due to dense fibrotic stroma and necrosis
  - Cells are commonly arranged as single cells, crowded groups, and stripped nuclei
  - Cells are epithelioid and/or spindle-shaped with marked variation in size
  - Giant cells common

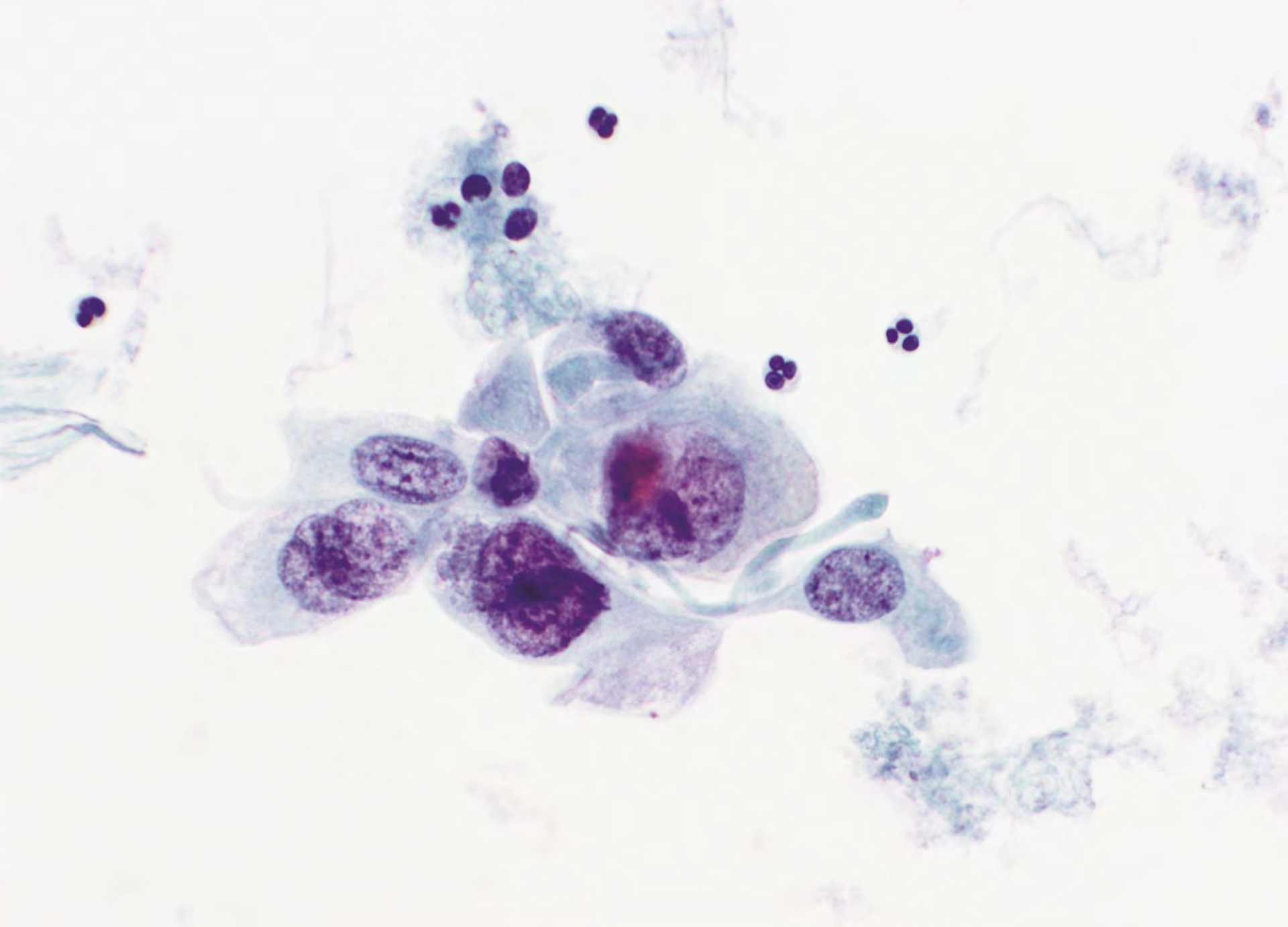


*continued on next slide*

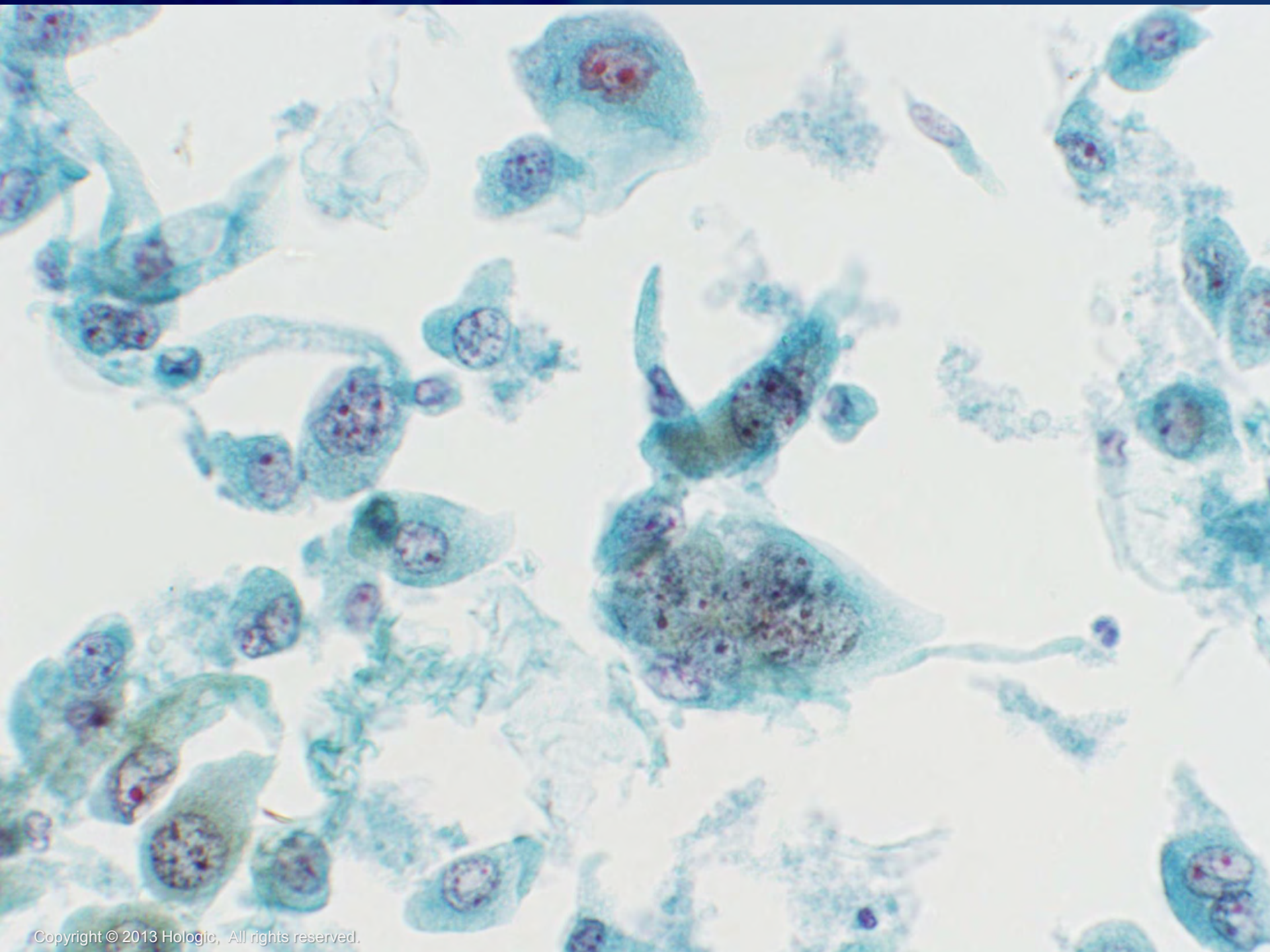
# Malignant Findings Cytology

- Undifferentiated (Anaplastic) Carcinoma - continued
  - Nuclei are enlarged, hyperchromatic, with coarse, irregular chromatin, irregular nuclear borders, macronucleoli, and intranuclear cytoplasmic inclusions
  - Abundant inflammatory cells, primarily neutrophils can be present, sometimes invading the cytoplasm of tumor cells
  - Frequent normal and abnormal mitoses
  - Focal squamous differentiation may be present and raise the possibility of a squamous cell carcinoma (primary or metastatic)









# Malignant Findings Overview & Cytology

- Squamous Cell Carcinoma
  - Poor prognosis
  - Occurs in the elderly
  - Rare tumor of the thyroid, accounting for <1% of tumors occurring in the thyroid
  - Indistinguishable from metastatic squamous cell carcinoma
  - Correlate with clinical history and imaging results
  - Large, pleomorphic keratinized squamous cells with or without necrosis



# Malignant Findings

## Types

- Lymphomas
  - Diffuse large B-Cell lymphoma (DLBCL)
  - Extranodal marginal zone lymphoma of mucosa-associated lymphatic tissue (MALT) lymphoma
  - Mixed DLBCL and MALT lymphoma



# Malignant Findings Overview

- Lymphomas
  - Account for 1-5% of all thyroid cancer
  - Equal split between MALT type, DLBCL and mixed MALT/DLBCL
  - Two thirds are preceded by Hashimoto thyroiditis
  - Mainly affects women in their sixth decade
  - Rapid onset presenting as a firm, diffuse mass
  - Can occur in the thyroid either as a primary lesion or secondarily with the latter being more common
  - Immunophenotypic subtyping is necessary



# Malignant Findings

## Cytology

- Diffuse large B cell Lymphoma (DLBCL)
  - Highly cellular aspirate that is easily recognizable as malignant
  - Large, atypical immature lymphoid cells
    - Centroblast-like cells
      - Peripheral nucleoli and scant cytoplasm
    - Immunoblasts
      - Prominent central nucleolus, abundant cytoplasm and may appear plasmacytoid



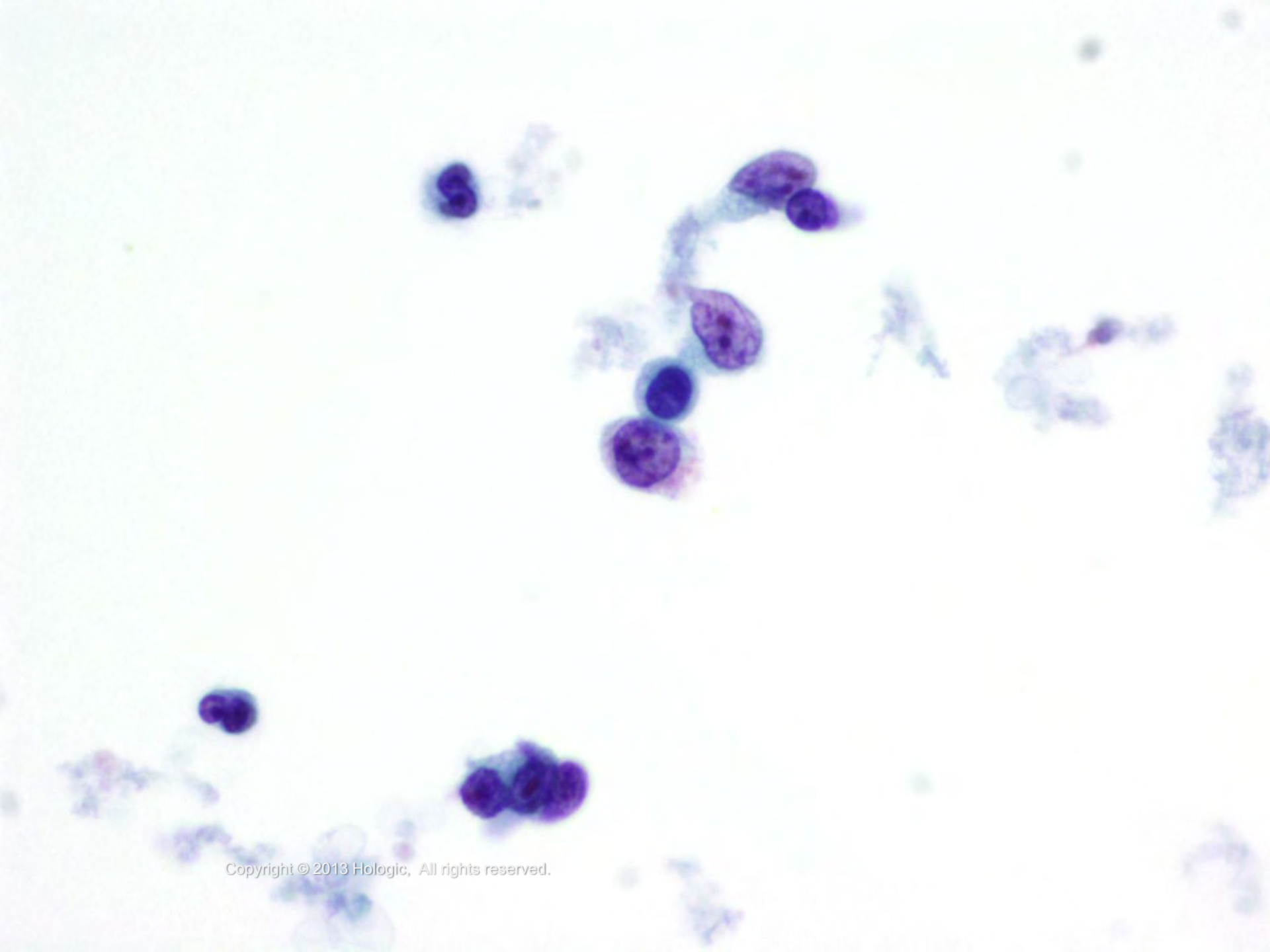
*continued on next slide*

# Malignant Findings

## Cytology

- Diffuse large B cell Lymphoma (DLBCL) - continued
  - Lymphoglandular bodies are present
  - Follicular cells are absent or rare
  - CD20 and CD45 +, CD5 –
  - Monotypic light chain restriction
  - Differential Diagnosis(DDx)-metastatic carcinoma





# Malignant Findings

## Cytology

- Extranodal marginal zone lymphoma of mucosa-associated lymphatic tissue (MALT) lymphoma
  - (DDx) Hashimoto thyroiditis
  - Highly cellular aspirate resembling a reactive lymph node
  - Heterogeneous population with an increased number of small to intermediate-size lymphocytes
  - Immunoblasts, plasma cells, lymphoglandular bodies and lymphohistiocytic aggregates



*continued on next slide*



# Malignant Findings

## Cytology

- Extranodal marginal zone lymphoma of mucosa-associated lymphatic tissue (MALT) lymphoma - continued
  - Absence of cells that transition between intermediate-size and large lymphocytes
  - Rare follicular and oncocytic cells are often present
  - Monocytoid appearance
  - Light chain monoclonality
  - Positive for CD20 and CD45, Bcl-2
  - Negative for CD5, CD10, CD23, Cyclin D1, Bcl-6



# Malignant Findings Types

- Metastatic Carcinomas and Lymphomas
  - Metastases are uncommon. Most common primaries:
    - Kidney (DDx includes follicular and Hürthle cell neoplasms)
    - Colorectal
    - Lung
    - Breast
    - Melanoma (DDx includes medullary and anaplastic carcinoma)
    - Lymphoma (DDx includes undifferentiated carcinoma and Hashimoto thyroiditis)
    - Squamous cell carcinoma (primary or metastatic)

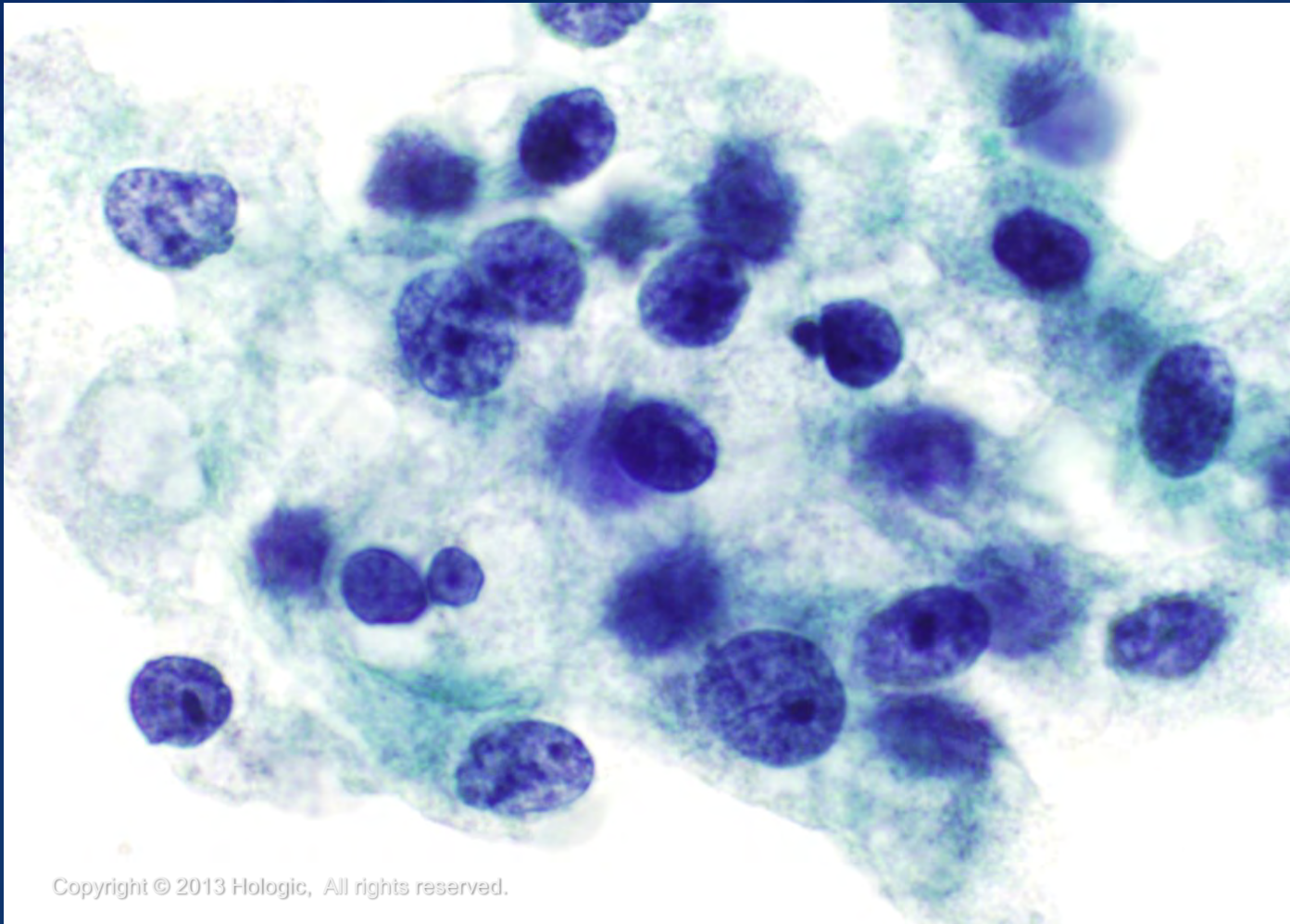


# Malignant Findings Overview

- Metastatic Carcinomas and Lymphomas
  - Patient history, flow cytometry (when considering a lymphoma), and immunocytochemistry (e.g., TTF-1, thyroglobulin) are invaluable for the diagnosis of these cases



# Metastatic Renal Cell Carcinoma



Copyright © 2013 Hologic, All rights reserved.

*ThinPrep*  
Non-Gyn

Hologic Proprietary © 2013

# Trademark Statement

CytoLyt, Hologic, PreservCyt, ThinPrep, and UroCyte are registered trademarks of Hologic, Inc. and/or its subsidiaries in the United States. CytoLyt, Hologic, PreservCyt, ThinPrep, UroCyte and associated logos are trademarks of Hologic, Inc. and/or its subsidiaries in other countries.

All other trademarks are the property of their respective owners.



# For more information...

- Visit our websites: [www.hologic.com](http://www.hologic.com),  
[www.thinprep.com](http://www.thinprep.com), [www.cytologystuff.com](http://www.cytologystuff.com)
  - Product Catalog
  - Contact Information
  - Complete Gynecologic and Non-gynecologic Bibliographies
  - Cytology Case Presentations and Unknowns



# Bibliography

ThinPrep® 2000 Processor Operator's Manual

ThinPrep® 5000 Processor Operator's Manual

Ali, Syed Z., Cibas, Edmund S.: *The Bethesda System for Reporting Thyroid Cytopathology: Definitions, Criteria and Explanatory Notes*, 2010.

Layfield, Lester: *Cytopathology of the Head and Neck ASCP Theory and Practice of Cytopathology Series 7*, 1997: 159-208.

Clark, Douglas P., Faquin, William C.: *Thyroid Cytopathology, Second Edition*, 2010: 1-200

DeMay, Richard M: *The Art & Science of Cytopathology 2<sup>nd</sup> Edition Superficial Aspiration Cytology (Volume 2 of 4)*, 2012: 839-96.



# Bibliography

## Images:

Salmon, I. Prof. *Normal Thyroid*. Photograph. Forpath vzw/asbl, oct; 1999

[<http://www.forpath.org/workshops/9910/images/th02.jpg>]

28 December 2012

SmartDraw<sup>®</sup> (Standard Edition) [Software]. (2011).

Retrieved from <http://www.smartdraw.com>

ThinPrep<sup>®</sup> Non-Gyn Morphology Reference Atlas:

Thyroid: 223-244

<http://www.cytologystuff.com/learn/section2660.html>

<http://www.cytologystuff.com/learn/section2241.html>

